Abstract 11

Right Ventricular Candidal Mycetoma in a Preterm Neonate-A Rare Case Report

Deepa D.Shetty, Jayashree Purkayastha

Abstract

Fungal endocarditis is a rare occurrence in preterm neonates associated with increased morbidity regardless of type of treatment and more than 50% mortality with diagnosis in majority of cases made post-mortem. We report blood stream infection with c*andida albicans* complicated with endocarditis in a 30 weeks preterm neonate. This neonate had stormy neonatal course, peripherally inserted central catheter and received total parenteral nutrition and treatment for bacterial sepsis previously. On day 45 of life, he had cholestasis, deranged liver function test and persistent thrombocytopenia. Blood culture sent on day 60 of life in view of apnea, bradycardia and desaturations grew *C.albicans.* The echocardiography obtained in view of desaturations showed large fungal vegetation on tricuspid valve with mycetoma filling the right ventricle. Mycetoma formation as observed here has been noted only in 9% cases of disseminated candidiasis. In neonates antifungal therapy alone has been noted to have success in comparison with antifungals and surgery in adults. We treated the neonate with Amphotericin B and fluconazole based on culture sensitivity report. The neonate had fluctuating clinical course over next 2 weeks and finally succumbed. Early diagnosis in the presence of risk factors, prompt antifungal therapy and enforcement of strict infection control measures are important to decrease the incidence of fungal opportunistic infection in neonates.
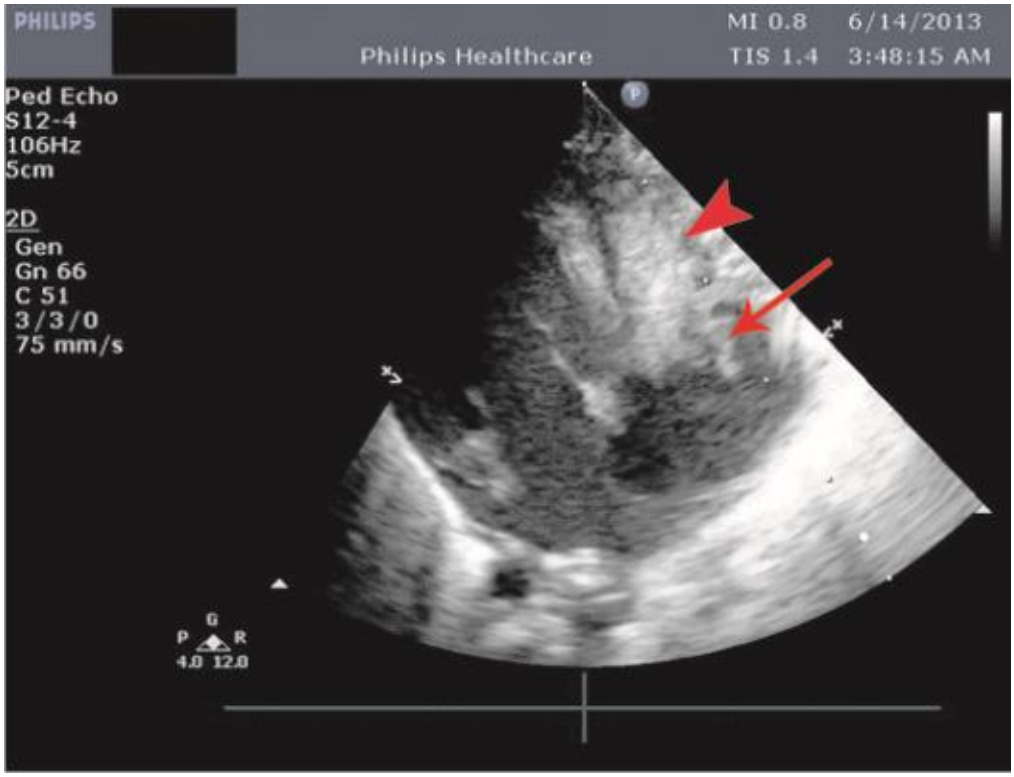
Figure: Right ventricle mycetoma, tricuspid valve vegetations (arrow)