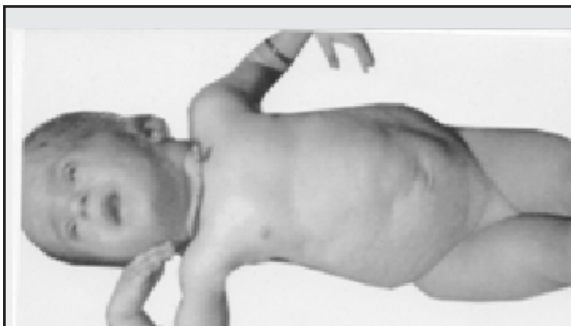


SPOT DIAGNOSIS (IMAGE GALLERY)



>>> S.S. Kashyape, P.N. Lothe
Kashyape Children Hospital, Nashik, India

An eleven-month-old female child born of non consanguineous marriage presented with hypopigmented patches all over body since birth, wrist joint deformity in the form of claw hand, ankle joint deformity, clinodactyly, protruded abdomen, low set ears, narrow nasal bridge, sparse eyebrows and eyelashes. She was partially bald. Only upper incisor tooth was present. There was history of convulsion in past. She also had global developmental delay. What is the diagnosis?

Goltz Syndrome. It is also known as focal dermal hypoplasia and is a rare mesoectodermal disorder inherited by a X-linked dominant gene which is lethal in homozygous males. It is characterized by absent ectodermis, mesodermis and neurodermis derived elements. The dermis may be replaced by accumulation of adipose cells which appears as striking hernia like outpouching of fatty tissue. In Goltz syndrome following varied defects are noted -Hypo or hyperpigmented skin lesions, raspberry like papillomas, adnexal abnormalities such as apocrine nevi, hypohidrosis (scalp and body hairs are usually sparse) with sparse eyebrows and eyelashes, ears are low set with narrow nasal bridge, chin is generally pointed, skull may be microcephalic. Skeletal anomalies include asymmetric involvement of hands and feet, clinodactyly, ectrodactyly, polydactyly, claw hands, abnormal vertebrae with kyphoscoliosis. Dental anomalies include hypodontia, oligodontia, retarded eruption and malocclusion. There may be microphthalmia with bilateral coloboma of the iris and ectopia lentis.

E-published: December 2008