

## CASE REPORTS

# DOES METABOLIC MYOPATHY RESPOND TO STEROIDS? - A CASE REPORT

Savita Krishnamurthy<sup>1</sup>, Indumathi C K<sup>1</sup>, Sanjiv Lewin<sup>1</sup>, Harini R Rao<sup>1</sup>, Raghunandan Nadig<sup>2</sup>  
<sup>1</sup>Department of Pediatrics and <sup>2</sup>Department of Neurology, St John's Medical College, Bangalore, India.

### ABSTRACT

Role of riboflavin, coenzyme Q10 and carnitine in treating metabolic myopathies has been well described. However, literature is scarce on the therapeutic role of steroids. We report a 10 year old boy presenting with progressive proximal and axial myopathy, who responded to steroids within a week. His muscle biopsy later suggested a lipid storage myopathy. Role of steroids in treatment of certain forms of metabolic myopathies needs to be researched.

### ARTICLE HISTORY

Received 24 February 2018  
Accepted 26 March 2018

### Introduction

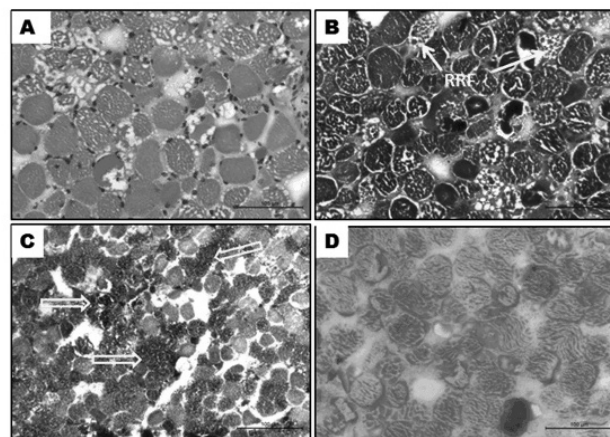
Metabolic myopathies comprise a diverse group of disorders caused by defects in cellular energy metabolism.<sup>1</sup> The three main categories include glycogen storage disorders, fatty acid oxidation defects and mitochondrial disorders due to respiratory chain impairment.<sup>1</sup> Among these, lipid storage myopathies (LSM) include a group of disorders of lipid metabolism involving either fatty acid oxidation or respiratory chain, finally affecting the skeletal muscle exclusively or predominantly. There is a lot of recent data on phenotypes, genetic and therapeutics in these disorders.<sup>2,3</sup> Although steroids are known to affect lipid metabolism, their role in treating LSM has rarely been explored.<sup>4,5</sup> We present a 10 year old boy with progressive proximal and axial lipid storage myopathy who showed a dramatic response to steroids.

### Case Report

A 10 years old boy, born of a third degree consanguineous marriage, presented with gradually progressive fatigability on walking and proximal muscle weakness for one year. There was difficulty in climbing stairs initially followed by difficulty in getting up from squatting position for the past 5 months. Of late, he had developed difficulty in turning in bed and also in extending the neck. However there was no diurnal variation of symptoms, ptosis, diplopia, dysphagia, myalgia, fever or rash. He was evaluated elsewhere and found to have a positive neostigmine test 5 months ago. He had been started on pyridostigmine and steroids on which he had partial improvement in symptoms, followed by worsening to present condition over last 2 months. He was on oral prednisolone at 0.2 mg/kg/d at time of presentation. On examination, his weight was 20 kg and height was 127 cms. He had flaccid quadriparesis, hyporeflexia, neck drop and weakness of trunk muscles. He was noted to have paradoxical breathing.

His higher mental functions, cranial nerves, fundus, bladder and sensory examination were normal. Rest of the systemic examination was normal. Investigations showed hemoglobin 13 g/dl, white cell count 10,790/cumm, platelet count 430,000/cumm, ESR 12 mm at end of 1 hour, serum sodium 132 meq/l, potassium 4.2 meq/l, creatine kinase (CPK) 7431 IU/L (Normal 39-308 IU/L), lactate dehydrogenase (LDH) 4754 IU/L (Normal 85-227 IU/L), aspartate transaminase (AST) 1244 IU/L (Normal 15-37 IU/L) and alanine transaminase (ALT) 380 IU/L (Normal 30-65 IU/L). Serum lactate was 4 mg/dl (<1.5 mg/dl). Renal and thyroid function tests were normal. Echocardiography was normal. Repetitive nerve stimulation was not suggestive of myasthenia and anti-acetylcholine receptor antibody was negative. Possible differential diagnoses of polymyositis, metabolic myopathies and myasthenia gravis were considered and a muscle biopsy was done. Muscle biopsy showed vacuolated fibers positive for Oil

**Figure 1.** Muscle Biopsy Histopathology showing lipid storage myopathy



Transversely cut skeletal muscle tissue showing  
A-rounding, variation in diameter and multiple fine vacuoles (HE stain)  
B- Ragged red fibers (RRF) (MGT stain)  
C- Intense reaction to oxidative enzyme (NADH-tr) in vacuolated fibers (↔)  
D-Vacuolated fibers positive to Oil-red O stain suggesting lipid storage

**CONTACT** Savita Krishnamurthy

**Email:** [sivakripa@gmail.com](mailto:sivakripa@gmail.com)

**Address for Correspondence:**

Savita Krishnamurthy, Department of Pediatrics,  
St John's Medical College, Bangalore, India.

©2019 Pediatric Oncall

Red-O suggestive of lipid storage myopathy (Figure 1). Tandem mass spectrometry showed normal acyl-carnitine levels. A genetic evaluation could not be sent in view of financial constraints. In the meantime, in view of rapid deterioration over the last one month, earlier response to steroids, possibility of polymyositis and impending respiratory failure, he was started on methyl prednisolone 30 mg/kg for 3 days followed by oral prednisolone at 1mg/kg/d. Within a week, he was able to hold his neck in position and walk with support. At 1 month follow up, he was able to climb stairs and his CPK, AST, ALT levels declined to 354 IU/L, 56 IU/L and 134 IU/L respectively. He was also started on riboflavin, coenzyme Q and carnitine after the muscle biopsy report. Steroids were gradually tapered to a low dose (0.3 mg/kg/d) over the next 6 months and subsequently stopped after 18 months. He is currently doing well on riboflavin, coenzyme Q and carnitine and on regular follow up for the past 30 months.

### Discussion

Lipid storage myopathies are a form of metabolic myopathy pathologically characterized by prominent lipid accumulation in muscle fibers due to lipid dysmetabolism either in the mitochondrial transport or oxidation of exogenous fatty acids or catabolism of endogenous triglycerides. They present as progressive myopathy or with recurrent episodes of rhabdomyolysis triggered by fasting, exercise or infections.<sup>1,2,3</sup> Among the LSM, myopathic form of coenzyme Q10 deficiency, a possibly allelic disease of Multiple Acyl-CoA Dehydrogenation Deficiency (MADD) presents with proximal and axial myopathy, fatigability and increased serum levels of creatinine kinase and lactate. Our patient presented with similar clinical symptoms and biochemical findings. Muscle biopsy also shows excessive lipid droplets predominantly in type 1 fibres.<sup>2</sup> Biopsy findings in our child were suggestive of the same.

Many forms of MADD have been shown to be riboflavin responsive.<sup>2</sup> Carnitine supplementation has been used in cases with secondary carnitine deficiency, while coenzyme Q10 is known to be useful in myopathic forms of secondary coenzyme Q10 deficiency.<sup>6</sup> A possibility of myopathic form of secondary coenzyme Q10 deficiency was considered in our child and he has been on riboflavin, coenzyme Q10 and carnitine since then. However, there are very few reports of LSM responsive to steroids. Steroids are known to enhance fatty acid transport, activate triglyceride lipase and augment

lipolytic activity of epinephrine and growth hormone, probably contributing to the therapeutic effect.<sup>4,5</sup> Engel et al reported a 19 year old girl with LSM showing a complete remission within 7 days of prednisone.<sup>5</sup> Similarly, in our case, there was a dramatic response to empirical steroids within a week. On follow up, he continues to be in remission.

More studies are needed to elucidate the effect of steroids on lipid metabolism and their role in treatment of metabolic myopathies, especially in inducing remission.

### Acknowledgement

Dr Gayathri R, Department of Neuropathology, NIMHANS, Bangalore for analyzing the muscle biopsy, Dr Jerome Joseph, Department of Pediatrics, St John's Medical College, Bangalore for clinical management of the case.

**Contributors List:** SK performed literature search and compiled the draft, ICK and SL headed the clinical management and edited the draft, HR performed literature search and assisted in clinical management, RN contributed to clinical management and intellectual content of the draft.

### Compliance with Ethical Standards

**Funding:** None

**Conflict of Interest:** None

### References :

1. Berardo A, DiMauro S, Hirano M. A Diagnostic algorithm for metabolic myopathies. *Curr Neurol Neurosci Rep.* 2010;10:118-26.
2. Bruno C, DiMauro S. Lipid storage myopathies. *Curr Opin Neurol.* 2008;21:601-606.
3. Liang WC, Nishino I. Lipid storage myopathy. *Curr Neurol Neurosci Rep.* 2011;11:97-103.
4. Sarnat HB. Developmental disorders of muscle. In: Kleigman RM, Stanton BF, St Geme JW, Schor NF. *Nelson Textbook of Pediatrics.* New Delhi; Reed Elsevier India. 2016:2991.
5. Engel AG, Siebert RG, Rochester, Minn. Lipid storage myopathy responsive to prednisone. *Arch Neurol.* 1972;27:174-181.
6. Rahman S, Clarke CF, Hirano M. 176th ENMC international workshop: Diagnosis and treatment of coenzyme Q10 deficiency. *Neuromuscul Disord.* 2012;22:76-86.