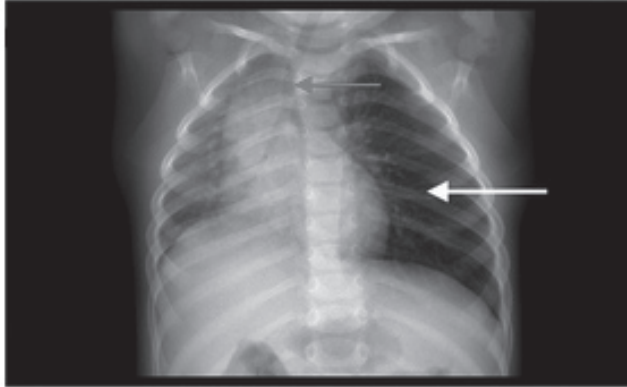


SPOT DIAGNOSIS (IMAGE GALLERY)



PERSISTENT COUGH IN A CHILD

Naline Juillard, Maxime Mermod

Service d'Oto-rhino-laryngologie et de Chirurgie Cervico-Faciale, Lausanne, Switzerland.

Address for Correspondence: Dr Maxime Mermod (MD), Service d'Oto-rhino-laryngologie et de Chirurgie Cervico-Faciale, Rue du Bugnon 46, 1011 Lausanne, Switzerland. E-mail: maxime.mermod@chuv.ch.

An 18-month-old male presented to the emergency department with a history of choking while eating 5 days prior. Despite a trial of treatment with bronchodilators, he had a persistent cough. Physical examination revealed reduced breath sounds over

the left lung field, intercostal retractions, and prolonged expiration. His vital signs were normal. Chest X-ray showed over-inflation of the left hemithorax with mediastinal shift to the right.

What is your diagnosis?

Rigid bronchoscopy was ordered immediately, and showed complete obstruction of the left main bronchus by a pea, which was removed endoscopically. The patient recovered uneventfully and was discharged the following day.

Although rare, foreign body (FB) inhalation is a dangerous event, and is the most common cause of accidental death in children aged less than 1 year. Children remain at high risk of FB inhalation up to age 3 years. (1) Organic items (such as seeds, peanuts, and dried fruits) are the most frequently aspirated objects in younger children, whereas older children are more likely to aspirate inorganic items (such as pieces of plastic and small toys). (2) The types of inhaled FBs vary according to the local diet and customs. (3) FB inhalation classically results in an acute episode of suffocation and choking, followed by paroxysms of coughing and dyspnea or tachypnea. After the acute phase, the FB becomes lodged in the airway, the preventive reflexes stop, and children may present with more subtle signs and symptoms. (2) Persistent cough, wheezing, prolonged expiration, rhonchi, and reduced breath sounds on one side should alert the physician to the possibility of FB inhalation. (2) Chest X-ray may show over-inflation on one side, mediastinal shift, atelectasis, or radio-opaque material in the lung field. (1) However, no single factor in the history, physical examination, or radiographic findings is both sensitive and specific for the diagnosis of FB inhalation. Endoscopy is mandatory for the definitive diagnosis and treatment of FB inhalation. Bronchoscopy should be done in children with a choking history and persistent symptoms, in children with abnormal physical or radiographic findings, (1) and when there is suspicion of FB inhalation. (2) Prevention is important, and prompt diagnosis is essential for the appropriate management of FB inhalation. (1)

References

1. Cohen S, Avital A, Godfrey S, Gross M, Kerem E, Springer C. Suspected foreign body inhalation in children: what are the indications for bronchoscopy? *T J Pediatr.* 2009;155:276-80
2. Cutrone C, Pedruzzi B, Tava G, Emanuelli E, Barion U, Fischetto D, et al. The complimentary role of diagnostic and therapeutic endoscopy in foreign body aspiration in children. *Int J Pediatr Otorhinolaryngol.* 2011; 75:1481-1485.
3. Chinski A, Foltran F, Gregori D, Passali D, Bellussi L. Foreign bodies causing asphyxiation in children: the experience of the Buenos Aires paediatric ORL clinic. *J Int Med Res* 2010;38:655-60



DOI No. : 10.7199/ped.oncall.2015.19