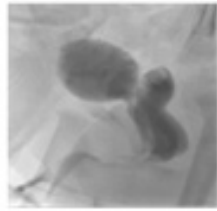
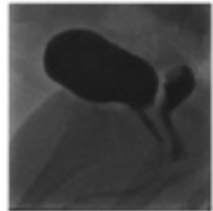


SPOT DIAGNOSIS (IMAGE GALLERY)



Case 1



Case 2

Case 1 & 2 - Micturating Cystourethrogram (MCUG) showing contrast filled structure (Vagina) posterior to the bladder with a filling defect in the dome consistent with cervix

MICTURATING CYSTOURETHROGRAM (MCUG) IN 2 FEMALE INFANTS- WHAT IS THE DIAGNOSIS?

Kollannoor B*, Corbett H, Nayak S*, Patel N*, Abdelaziz M***

**Department of Pediatrics, St Helens and Knowsley NHS Teaching Hospitals, ** Department of Pediatric Urology, Alder Hey Children's NHS Foundation Trust.*

Address for Correspondence: Dr Maysara Abdelaziz, Consultant Pediatrician, St Helens & Knowsley NHS trust, Warrington Road, Prescott, Liverpool L35 5DR, UK.
E-Mail: Maysara.Aziz@sthk.nhs.uk

Case 1: A 6 week old baby girl presented with urinary tract infection (UTI). At 11 weeks she had a second UTI associated with E. coli septicemia. Her renal ultrasound showed left sided pyelonephritis and her micturating cystourethrogram (MCUG) (Figure 1) was reported to show a urogenital sinus. A pediatric urologist identified the vaginal and urethral openings, ruling out urogenital sinus.

Case 2: A term baby had mild left hydronephrosis on antenatal and postnatal renal ultrasound scans. Her MCUG was reported to show vesico-ureteric reflux (VUR). However there was a contrast filled structure behind the bladder extending to the perineum, with wide and round end with filling defect in the dome (Figure 2). A pediatric urologist identified both urethral and vaginal openings on examination.

What is the diagnosis?

Expert opinion: Reflux of urine into vagina during voiding is known as vaginal reflux. (1) Vaginal reflux usually presents with post-micturition dribbling. The diagnosis is clinical so radiological investigations are not required. However, vaginal reflux may be seen during micturating cystourethrogram (MCUG). (2) Vaginal reflux should be considered when a contrast filled structure extending to the perineum is seen behind the bladder on MCUG. Careful genital examination is recommended. Identification of urethral and vaginal openings rules out a urogenital sinus, which can also cause opacification of the vagina during MCUG.

In female infants, the incidence of vaginal reflux has been reported to be 18.8 percent. (3) Recurrent UTIs in infants with vaginal reflux develop in 33 percent which is higher than 7.7 percent in infants without vaginal reflux. (3) In our case series, vaginal reflux was incidentally noted in the above two infants as part of investigation with MCUG. In the two infants described one had recurrent UTI whilst the other did not have UTI. The infant with recurrent UTI was managed along NICE UTI treatment guidelines in children. (4) While there are suggested techniques in managing vaginal reflux and urinary incontinence in older girls with satisfying results by adopting a correct posture by spreading the legs wide during voiding to prevent reverse flow of urine (5), no specific management for vaginal reflux was followed in the above two infants described.

Contributors: AM and KB conceptualized and drafted the initial report. AM, KB, CH, NS and PN reviewed and revised the report. All authors approved the final manuscript as submitted and agree to be accountable for all aspects of the work.

References:

1. Snyder EM, Nguyen RA, Young KJ, Coley BD. Vesicovaginal reflux mimicking obstructive hydrocolpos. J Ultrasound Med. 2007 Dec;26(12):1781-4.
2. Warade M, Majid Y, Dayananda L, Gupta K. Vesicovaginal reflux: A case report. Indian J Radiol Imaging 2009;19:235-7
3. Shim YH, Lee JW, Lee SJ. The risk factors of recurrent urinary tract infection in infants with normal urinary systems. Pediatr Nephrol. 2009 Feb;24(2):309-12
4. NICE Guidelines. Urinary tract infection in under 16s: diagnosis and management. Available at website: [www.nice.org.uk/guidance, cg54](http://www.nice.org.uk/guidance/cg54). Accessed on 22nd February 2017
5. Fernández Ibieta M, Zambudio Carmona G, Martínez Castañero I, Guirao Piñera MJ, Ruiz Jiménez JI. Reflujo vaginal: una causa olvidada de incontinencia diurna en niñas prepúberes. An Pediatr (Barc). 2015;83:55-6.

Funding: none

Conflict of Interest: none

DOI No. : 110.7199/ped.oncall.2017.28

