

LETTER TO EDITOR (VIEWERS CHOICE)

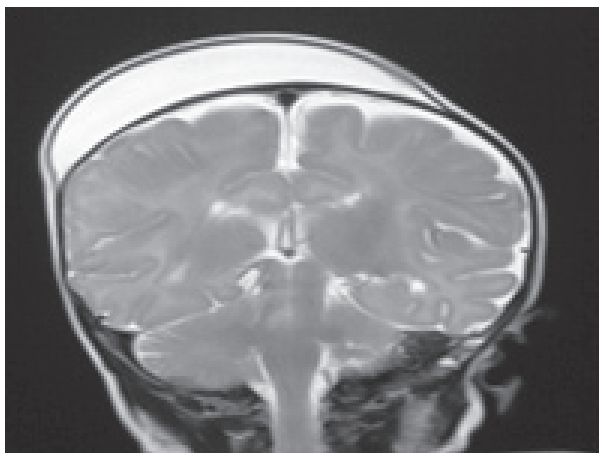
SUB-APONEUROTIC FLUID COLLECTION: A RARE CAUSE OF SCALP SWELLING IN INFANCY

Shiji Chalipat, Geeta Karambelkar, Vijay Dhobale, S R Agarkhedkar, Renuka Jadhav

Keywords: Sub-aponeurotic fluid collection, scalp swelling.

A 4 weeks old female child was brought with gradually increasing scalp swelling for 5 days. She was born by emergency caesarean section at term due to failure to progress. There was no history of forceps or ventouse application during the process of labour. Birth weight was 3kg and post natal course was uneventful and there was no scalp swelling at that time. There was no trauma. On local examination there was a soft, non tender, fluctuant diffuse scalp swelling, measuring 8×6 cm extending from vertex to frontoparietal area. The swelling was not limited by suture lines and no signs of bruising, trauma or inflammation were observed over scalp. There were no focal neurological deficits on neurologic evaluation. Hemogram and coagulation profile were normal. Lateral X ray of skull showed soft tissue swelling with no skull fracture. Ultrasound cranium showed sub-aponeurotic fluid collection but was not definitive about type of fluid. MRI brain showed a large fluid collection in the sub-aponeurotic space (8 cm × 5.6 cm × 1.5 cm) over right frontoparietal region and also left parietal region with no intracranial extension (Figure.1). Brain parenchyma and ventricular system were normal. Therapeutic aspiration of the fluid was performed under aseptic precautions and the fluid was clear and sterile. Biochemical parameters of the fluid were similar to cerebrospinal fluid (CSF). The swelling reappeared again within 24 hours of aspiration. Based on clinical presentation and neuroimaging studies, a diagnosis of subaponeurotic fluid collection was made and was managed conservatively. On regular follow up of the infant, the swelling gradually resolved over next 12 weeks.

Figure 1: MRI Brain showing sub-aponeurotic fluid collection



Sub aponeurotic fluid collection (SFC) is a rare but a diagnostic dilemma where a scalp swelling appears in young infants. This condition is poorly described in literature with less than 20 cases reported worldwide. (1) Usual age of presentation of SFC is early infancy. The etiology of SFCs remains largely uncertain. (2) Previous studies suggest that SFC, like sub-aponeurotic haemorrhage (SH), may be linked to birth trauma, disruption of scalp lymphatic drainage or venous drainage or cerebrospinal fluid (CSF) leakage. (3) However, analysis of several aspirates from these patients showed that CSF was found in all samples. The origin of this CSF is uncertain. Aspirations have no therapeutic benefit with swelling reappearing immediately (2,3) which was also observed in our patient. Treatment is conservative with spontaneous resolution of the swelling occurring over time. It is therefore vital that clinicians are aware of this condition and manage these patients appropriately.

Funding: None

Conflict of Interest: None

References :

1. Vaibhav A, Smith R, Millman G, Cooper J, Dwyer J. Sub-aponeurotic fluid collection in infancy: An unusual but distinct cause of scalp swelling in infancy. *BMJ Case reports*. 2010; pii: bcr0420102915
2. Hopkins RE, Inward C, Chambers T, Grier D. Sub-aponeurotic fluid collections in infancy. *Clin Radiol*. 2002; 57:114-116
3. Schoberer A, Yagmur E, Boltshauser E, Korinth M, Niggemann P, Häusler M. Sub-aponeurotic fluid collections: A delayed-onset self-limiting cerebrospinal fistula in young infants. *Eur J Paediatr Neurol*. 2008;12:401-403

From: Department of Paediatrics, Dr DY Patil Medical College, Pimpri, Pune.

Address for Correspondence: Dr Shiji Chalipat, Assistant Professor, Department of Paediatrics, Dr DY Patil Medical College, Pimpri, Pune, India.

Email : dr_shiji@yahoo.co.in

DOI: 10.7199/ped.oncall.2014.42



Quick Response Code