

CASE REPORTS

LEIGH'S SYNDROME DUE TO UNREPORTED HETEROZYGOUS VARIATIONS IN NDUFAF6 GENE

Bajpai A*, Gupta RK**, Thapar RK**

Abstract

Leigh's Syndrome also termed as sub-acute necrotizing encephalopathy is a rare, inherited progressive neurodegenerative disorder with characteristic pathological features usually presenting in infancy or early childhood. We report a 5 years old male child who had gradual regression of achieved milestones from 1 year of age. He developed myoclonic seizures at age of four years. On examination, he had rigidity. MRI showed abnormal signal pattern in bilateral putamen, caudate and superior colliculi. Targeted gene sequencing analysis showed complex I deficiency that was compound heterozygous for two variations in NDUFAF6 gene (612392.0001 and 612392.0002) which is known to cause Leigh's Syndrome.

Keywords: Myoclonic, Gliosis, Ataxia, Seizures

Introduction

Leigh's Syndrome also termed as sub-acute necrotizing encephalopathy is a rare, inherited progressive neurodegenerative disorder with characteristic pathological features usually presenting in infancy or early childhood. The estimated prevalence of Leigh's Syndrome is 2.05 cases per 100,000. (1) The preschool incidence of Leigh's syndrome is 1 out of 32,000. (2) Age of onset of symptoms is usually less than 2 years (infantile form), but others may present in childhood (juvenile form) and unusually in adulthood. It presents early in life with psychomotor regression, abnormal muscle tone, weakness, dystonia, brainstem and cerebellar dysfunction (ataxia), regression of the achieved milestones, seizures, deficits of the pyramidal tract, apraxia, and myoclonus followed by ophthalmoplegia and respiratory difficulties as a sign of brain stem damage. (3) Affected children usually become symptomatic within the first year of life with feeding difficulties, vomiting and failure to thrive. Death usually occurs within a few years after onset of symptoms, typically from progressive respiratory failure. Laboratory analysis shows metabolic acidosis with elevated blood, cerebrospinal fluid (CSF) lactate, and pyruvate concentrations. (4) This syndrome is most commonly inherited in an autosomal recessive pattern. In about 20 to 25% of people with Leigh's syndrome, the condition is inherited in a mitochondrial pattern, which is also known as maternal inheritance. In a small number of affected individuals with mutations in nuclear DNA, Leigh's syndrome is inherited in an X-linked recessive pattern. (5) We report a case which presented clinically as a neurodegenerative disorder and subsequently diagnosed as a Leigh syndrome with 2 novel variations in the NDUFAF6 gene.

Case Report

A 5 years old male child, 1st born of non-consanguineous marriage, with an uneventful perinatal period, presented with history of regression of achieved milestones. The child was able to walk at 1 year of age after which there was gradual regression of achieved milestones. He developed myoclonic seizures at age of four years. At the time of presenting to our hospital, he

was bed-ridden and had intractable seizures. There was no family history of similar illness. On examination he had increased tone in the both upper and lower limbs. Deep tendon reflexes were exaggerated with bilateral positive Babinski sign. Fundus examination and arterial blood gas were normal. Tandem mass spectrometry shows elevated glycine level 755.2 mmol/L (normal value < 505). CSF lactate was 19.8mg/dl (normal value < 20mg/dl). EEG was suggestive of diffuse encephalopathy and MRI brain showed abnormal signal pattern in bilateral putamen, caudate and superior colliculi with areas of encephalomalacia and gliosis in bilateral frontal lobe (Figures 1a and 1b). Targeted gene sequencing analysis showed complex I deficiency with compound heterozygous for two variations in NDUFAF6 gene (612392.0001 and 612392.0002) which is known to cause Leigh's Syndrome. Based on clinical presentation, MRI findings and gene sequencing he was diagnosed to have Leigh's Syndrome. He was started on thiamine, riboflavin, carnitine, fat rich diet and anti-epileptic drugs and showed some improvement.

Figure 1a and 1b: MRI (T2 flair image) shows abnormal signal pattern in bilateral putamen, caudate and superior colliculi with encephalomalacia and gliosis in bilateral frontal lobe.

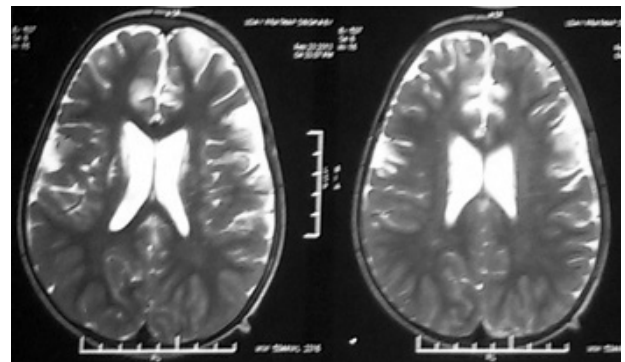


Figure1a

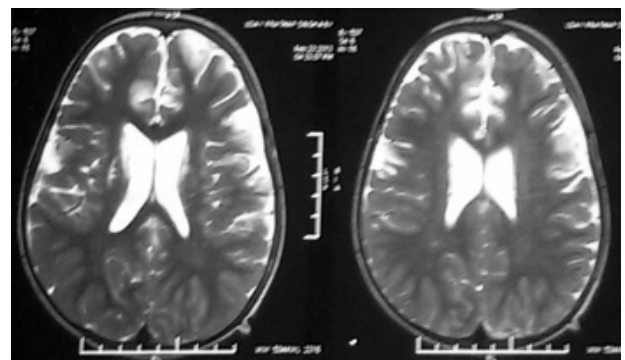


Figure 1b

Discussion

Leigh's disease is a rare progressive neurological disorder of the childhood. The underlying defect can be

at any of the sites in the enzyme pathway for respiratory metabolism. The mutations can arise sporadically or be inherited by autosomal recessive transmission (COX deficiency) or X linked transmission (PDHE1a deficiency) or by maternal transmission (complex V deficiency ATPase 6NT 8993 mutation). Mutations in other mitochondrial genes ND4 and ND6 and nuclear genes such as SURF-1 are also reported to be associated. Leigh's Syndrome associated mitochondrial enzyme deficiencies are those of pyruvate carboxylase, pyruvate dehydrogenase, cytochrome C oxidase, and Complex 1 (NAD-Coenzyme Q Reductase). (5,6) The diagnostic criteria are: (a) Progressive neurological disease with motor and intellectual developmental delay; (b) signs and symptoms of brainstem and/or basal ganglia disease; (c) Raised lactate levels in blood and/or cerebrospinal fluid; (d) Characteristic symmetric necrotic lesions in the basal ganglia and/or brainstem. Neuroimaging plays an important role in diagnosis of patients with Leigh's syndrome. The most characteristic neuro-radiological findings are bilateral, symmetric focal hyperintensities in the basal ganglia, thalamus, substantia nigra and brainstem nuclei at various levels on T2-weighted MRI. (5,6) These high T2 signals on MRI reflect the spongiform changes and vacuolation in the affected brain structures. (7) In the basal ganglia, the putamen is particularly involved. (8) In our patient, the glycine level was raised but it is not glycine encephalopathy because there was no hypotonia which is seen in glycine encephalopathy. Also, the child had progressive neurological disease with motor and intellectual developmental delay and characteristic symmetric necrotic lesions in the basal ganglia which was more suggestive of Leigh's Syndrome.

The aim of symptomatic treatment is to improve the ATP production and to lower the lactate levels. Thiamine, a cofactor of pyruvate dehydrogenase complex has been reported to improve the neurological status in some patients. Marked improvement is observed with riboflavin, which nearly normalizes the adenosine triphosphate production. (9) Rapid clinical and biochemical improvement has been observed in patients with acute central respiratory failure with the use of intravenous soya bean oil (ketogenic emulsion). Ketogenic diet has been found to improve the outcome in those with a deficiency of pyruvate dehydrogenase. Coenzyme Q and carnitine have also been found to be effective. (10)

Funding: None

Conflict of Interest : None

References :

1. Castro GM, Blanco BMO, Campos GY, Arenas BJ, Pintos ME, Eiris PJ. Epidemiology of pediatric mitochondrial respiratory chain disorders in northwest Spain. *Pediatr Neurol* 2006;34:204-211.
2. Darin N, Oldfors A, Moslemi AR, Holme E, Tulinius M. The incidence of mitochondrial encephalomyopathies in childhood: clinical features and morphological, biochemical, and DNA abnormalities. *Ann Neurol* 2001; 49:377-383.
3. Huntsman RJ, Sinclair DB, Bhargava R, Chan A. Atypical presentations of Leigh's syndrome: a case series and review. *Pediatr Neurol*. 2005;32:334-340
4. Medina L, Chi TL, DeVivo DC, Hilal SK. MR findings in patients with subacute necrotizing encephalomyelopathy (Leigh syndrome): correlation with biochemical defect. *AJNR* 1990;11:379-384.
5. Savoiaro M, Zeviani M, Uziel G. MRI in Leigh syndrome with SURF1 gene mutation. *Ann Neurol*. 2002; 51:138-139. Hombal AG, Narvekar V. Leigh's Disease (Subacute Necrotizing Encephalomyelopathy) - A Case Report. *Ind J Radiol Imag*. 2005;15:217-219.
6. Rossi A, Biancheri R, Bruno C. Leigh Syndrome with COX deficiency and SURF1 gene mutations: MR imaging findings. *Am J Neuroradiol* 2003; 24:1188-1191.
7. Mannan ASRA, Sharma MC, Shrivastava P, Raite AM, Gupta V, Behari M, Sarkar C. Leigh's syndrome-Clinical Brief. *Indian J Pediatr*. 2004;71:1029-1033
8. Bar MM, Elpeleg ON, Saada A. Effect of various agents on adenosine triphosphate synthesis in mitochondrial complex I deficiency. *J Pediatr* 2001;139:868-870
9. Toth G, Morava E, Bene J, Selhorst JJ, Overmars H, Vreken P, et al. Carnitine-responsive carnitine insufficiency in a case of mtDNA 8993T > C mutation associated Leigh syndrome. *J Inherit Metab Dis*. 2001; 24:421-422

From: *Department of Pediatrics, 7 Air Force Hospital, Kanpur, India, **Department of Pediatrics, Command Hospital, Lucknow, India.

Address for Correspondence:

Major Ajay Bajpai, 7 Air Force Hospital, Kanpur Cantt 208004, India.

Email : baijuafmc@yahoo.co.in

DOI: 10.7199/ped.oncall.2018.22

