

---

## LETTER TO EDITOR (VIEWERS CHOICE)

### **LIFE THREATENING WEGENER'S GRANULOMATOSIS - AN UNCOMMON DISEASE MASKED BY COMMON SYMPTOMS**

*Clay Cohen\*, Priya Prabhakaran\*\*, Franco Diaz\*\**

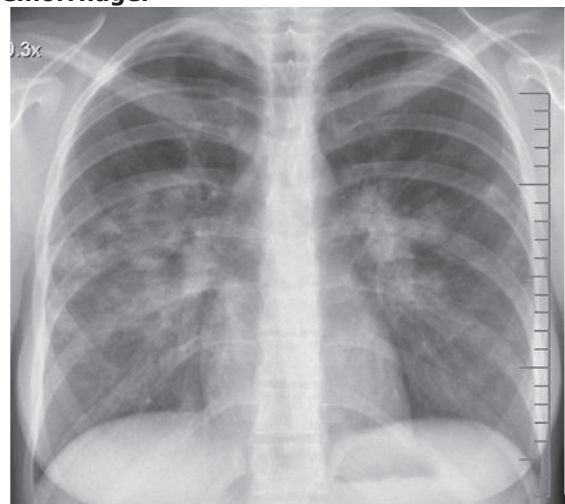
---

**Keywords:** vasculitis; pulmonary renal syndrome; hemoptysis; antibodies, antineutrophil cytoplasmic; respiratory insufficiency; renal insufficiency.

A 16 year-old previously healthy Caucasian female presented to the emergency department with a four day history of cough and hemoptysis followed by a two day history of respiratory distress. The week prior to presentation she had also noticed hematuria. Upon arrival she was afebrile, hypotensive (blood pressure 92/46), and in severe respiratory distress (respiratory rate of 28/min). After stabilization she was admitted to the intensive care unit. Community acquired pneumonia (CAP) and acute respiratory distress syndrome (ARDS) was the working diagnosis. Chest x-ray demonstrated bilateral perihilar patchy lung densities (Figure 1). Recent medical history included recurrent otitis media, sinus infections, as well as the development of oral ulcers, and fatigue over the previous six weeks. Laboratory work up revealed white blood cells (WBC) of 17,300 cells/cumm, hemoglobin of 9.6 g/dL, and platelet count of 649,000cells/cumm. Inflammatory markers were elevated with an erythrocyte sedimentation rate (ESR) of 130 mm/hr, and C - reactive protein (CRP) of 45.39 mg/dL. Her BUN and creatinine were 18 and 1.3 mg/dL respectively. Urine analysis showed uncountable red blood cells (RBC). These laboratory studies along with her smoldering clinical course with hemoptysis, weight loss, and prominent sinus and middle ear disease prompted consideration of a pulmonary-renal syndrome. A flexible bronchoscopy with bronchoalveolar lavage revealed diffuse lower airway membrane inflammation with thick bloody

secretions and clots scattered diffusely throughout her bilateral bronchioles, consistent with diffuse alveolar hemorrhage (DAH). Wegener's Granulomatosis (WG) was suspected based on renal, upper, and lower airway involvement. Detection of proteinase 3 (PR3) antibody at 3.2 IU/mL confirmed the diagnosis of WG. Treatment of WG was initiated with high dose intravenous steroids. She received seven rounds of plasmapheresis with two doses of rituximab separated by two weeks. Long-term outpatient therapy has included high dose corticosteroid and cyclophosphamide infusions.

**Figure 1: Initial chest x-ray demonstrating bilateral perihilar patchy lung densities, representing diffuse alveolar inflammation and hemorrhage.**



Wegener's granulomatosis, otherwise known as granulomatosis with polyangiitis, is an anti-neutrophil cytoplasmic antibody (ANCA) associated vasculitis. The onset of WG is usually insidious, and the diagnosis is often delayed with potential life threatening progression. Children frequently present to their pediatricians with constitutional symptoms (fever and arthralgias), recurrent sinusitis, otitis media, and stridor. (1) Common presenting features of WG include glomerulonephritis (88%), diffuse alveolar hemorrhage (DAH) (44%) and venous thrombotic events (12%). (2) A necrotizing CAP and WG may present with similar progression of constitutional and respiratory signs and symptoms. Chest radiography of necrotizing CAP often demonstrates a pleural effusion, which is usually not seen in WG. (3) The constellation of her symptoms at presentation (hypoxemic respiratory failure, hemoptysis, anemia, bilateral pulmonary infiltrates on pulmonary radiographs) is characteristic of DAH. (4) The diagnostic criteria, according to the American College of Rheumatology, require two of the following four: abnormal urinary sediment (RBC casts > 5 RBC/hpf), abnormal findings on chest radiography, oral ulcers/nasal discharge, and granulomatous inflammation on biopsy. (5) Treatment involves the use of corticosteroids and cyclophosphamide or rituximab. With combined cyclophosphamide and steroid treatment, 10-year survival reaches 75%. (6)

**Funding:** None

**Financial Disclosure:** None

**Conflict of Interest:** None

**References :**

1. Eustaquio ME, Chan KH, Deterding RR, Hollister RJ. Multilevel airway involvement in children with Wegener's granulomatosis: clinical course and the utility of a multidisciplinary approach. *Arch Otolaryngol Head Neck Surg* 2011; 137: 480-485

2. Akikusa JD, Schneider R, Harvey EA, Hebert D, Thorner PS, Laxer RM, et al. Clinical features and outcome of pediatric Wegener's granulomatosis. *Arthritis Rheum* 2007; 57: 837-844
3. Spalding SJ, Cambria M, Arkachaisri T. Distinguishing Wegener's granulomatosis from necrotizing community acquired pneumonia: A case report and comparison of radiographic findings. *Pediatr Pulmonol* 2009; 44: 195-197
4. Lara AR, Schwarz MI. Diffuse Alveolar Hemorrhage. *Chest* 2010; 137: 1164-1171
5. Ozen S, Pistorio A, Iusan SM, Bakkaloglu A, Herlin T, Brik R, et al. EULAR/PRINTO/PRES criteria for Henöch-Schonlein Purpura, childhood polyarteritis nodosa, childhood Wegener granulomatosis and childhood Takayasu arteritis: Ankara 2008. Part II: Final classification criteria. *Ann Rheum Dis* 2010; 69:798-806
6. Koldingsnes W, Nossent, JC. Baseline features and initial treatment as predictors of remission and relapse in Wegener's granulomatosis. *J Rheumatol* 2003; 30: 80-88

---

**From:** \*UAB Department of Pediatrics, Pediatric Residency Program, Birmingham, AL, \*\*UAB Department of Pediatrics, Division of Critical Care, Birmingham, AL, USA.

**Address for Correspondence:** Clay Cohen, Department of Pediatrics, Children's of Alabama, 1621 28th Ave S, Birmingham, AL, 35209, USA.

**Email:** ccohen@uabmc.edu



---

**DOI No.** 10.7199/ped.oncall.2014.56

---