

REVIEW ARTICLE

Ocular Morbidity In Premature Children

Mihir Kothari\*, V. Narendran\*\*, Parag K. Shah\*\*\*

**Introduction:**

The incidence of pre-term births in India varies from 2% to 4.3%.<sup>1</sup> With the improving infant mortality rate from 64.9/1000 in 2000 AD to 56.29/1000 in 2005 AD (Source: CIA World Factbook) more premature children are now surviving. These pre-term infants are more likely than term infants to have significant abnormalities of all parts of the visual system leading to reduced vision (Table1).

**Table 1: Vision Threatening Eye Diseases in Pre-term Infants Compared to Normal.<sup>2</sup>**

Disease	Prevalence
Retinopathy of Prematurity	30% (< 32 weeks) to 80% (< 28 weeks)
Myopia	6% Vs 2%
Squint (Strabismus)	13% Vs 1%
Amblyopia (Lazy Eye)	6% Vs 2%
Cerebral Visual Impairment	30%
Cataract, Glaucoma and Retinal Detachment	Not known

The most common problem in pre-term infants is retinopathy of prematurity (ROP).<sup>2</sup> Pre-term infants also have higher rates of refractive error, strabismus, amblyopia and cerebral visual impairment. The later problem is largely associated with neonatal brain injury. Years later, these children may develop glaucoma and retinal detachment.

In this review we present common eye disorders focusing on ROP that have high incidence in a premature child and not infrequently cause mild to severe visual impairment very early in life. A pediatrician helps by timely referral of the child to a Pediatric Ophthalmologist and counsels the parents

\*Director, Jyotirmay Eye Clinic and Pediatric Low Vision Center, 205 Ganatra Industrial Estate, Pokhran Road No1, Thane (W) 400 601, Maharashtra, India

\*\*Chief Medical Officer and Head of the Vitreo-retinal Services, Aravind Eye Hospital and Post Graduate Institute of Ophthalmology, Avinashi Road, Coimbatore 641 014, Tamilnadu, India.

\*\*\*Consultant, Vitreo-retinal Services, Aravind Eye Hospital and Post Graduate Institute of Ophthalmology, Avinashi Road, Coimbatore 641 014, Tamilnadu, India.

**Corresponding author:**

Mihir Kothari : [drmihirkothari@yahoo.com](mailto:drmihirkothari@yahoo.com)

about the probabilities of various ocular co-morbidities, their possible remediation and impact on the development of the child.

**Retinopathy of Prematurity:**

The most common eye disease of prematurity is retinopathy of prematurity (ROP).<sup>2</sup> The frequency and severity of this disorder is inversely related to the gestational age and birth weight (Table 2 and 3).

**Table 2: Incidence of ROP in the babies born at different Gestational age**

Gestational Age	Incidence of ROP
> 32 weeks	< 6%
< 31 weeks	30%
< 28 weeks	83%

**Table 3: Incidence of ROP in the babies of different Birth Weights**

Weight	Any ROP	Prethres-	Thresh
< 750gm	90%	39%	15%
750-999	78%	21%	7%
1000-1250	46%	7.3%	2%

Damage in ROP ranges from minor to catastrophic. Many risk factors other than gestational age ; birth weight are also associated with higher incidence of ROP. They are listed in table 4.

**Table 4: Risk factors for ROP<sup>3-15</sup>**

Established Risk Factors <sup>3-5</sup>	Potential Risk Factors <sup>6-13</sup>	Confirmed as not Risk Factors <sup>14,15</sup>
- Prematurity - Birth weight - Oxygen therapy	- In-vitro fertilization (IVFET) and Multiparity <sup>6-8</sup> - Intraventricular hemorrhage, Neonatal Seizures and Cerebral Palsy <sup>9</sup> - Anemia <sup>10,11</sup> - Blood transfusion <sup>10-12</sup> - Sepsis <sup>13</sup> - Bronchopulmonary dysplasia <sup>10</sup> - Vitamin E deficiency	- High light levels <sup>14</sup> - Hyperbilirubinemia <sup>15</sup>

**Pathophysiology:**

ROP is caused by the abnormal vascular development of the retina in pre-terms. The normal vascular development in human fetal retina<sup>16</sup> includes the process of Vasculogenesis and Angiogenesis.

**Vasculogenesis:**

Migration of large numbers of spindle-shaped mesenchymal precursor cells from the optic disc (completed by 15 weeks of gestation). These cells proliferate and differentiate to produce cords of endothelial cells that forms an immature vascular tree in the inner retinal layer centered on the optic disc. This is followed by Angiogenesis.

**Angiogenesis:**

The above mentioned immature vascular plexus become denser and gets extended peripherally. The vascular plexus matures by remodeling. The outer plexus starts forming around the incipient fovea between 25 and 26 weeks of gestation. The mature vessels then reach nasal retina followed by temporal retina at term.

**Pathological development of vessels in ROP<sup>17-20</sup>**

The vasculature in preterm child is immature. The child receives oxygen supplementation. Free Radicals are produced in the retina causing injury to the developing vascular plexus. This is associated with vasoconstriction and ischemia to the Retinal Pigment Epithelium (RPE). The RPE releases vascular endothelial growth factor (VEGF). This causes proliferative vitreo-retinopathy called ROP. At 16 weeks vasculogenesis begins at the optic disc, nasal ora is reached first followed the temporal ora that vascularise by 42 - 44 weeks.

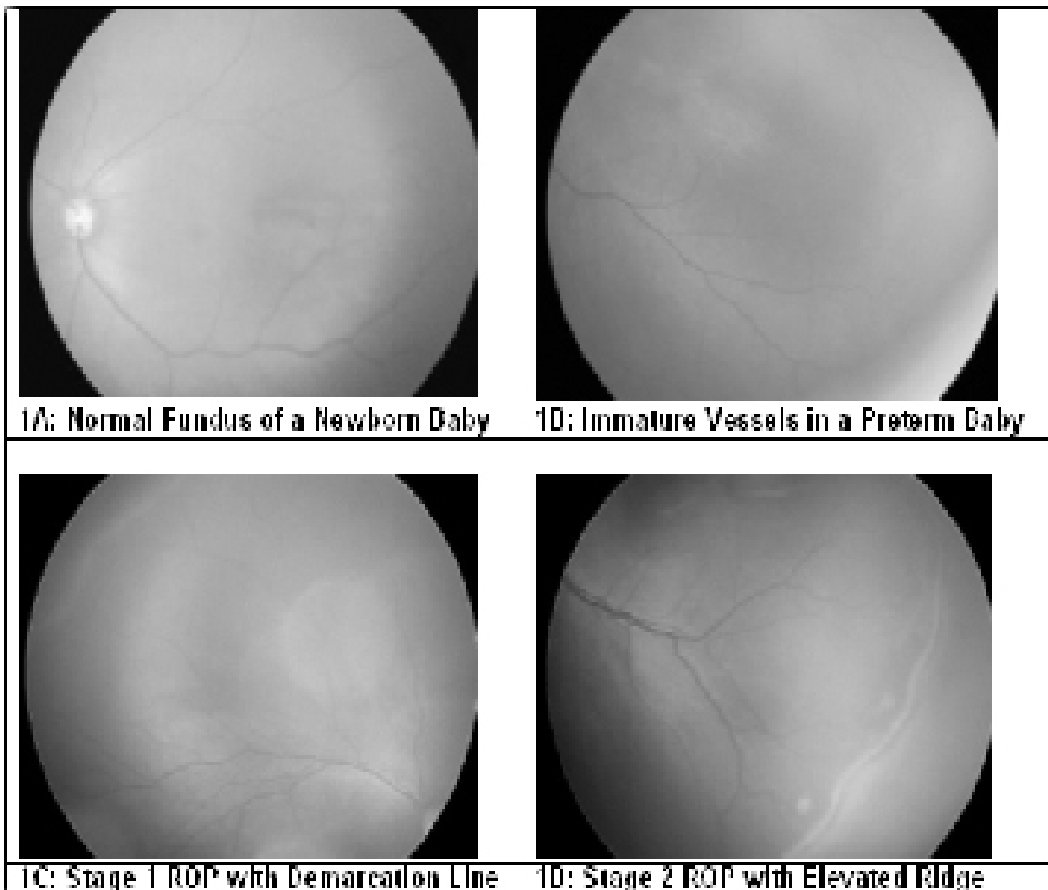
**Classification of ROP:**

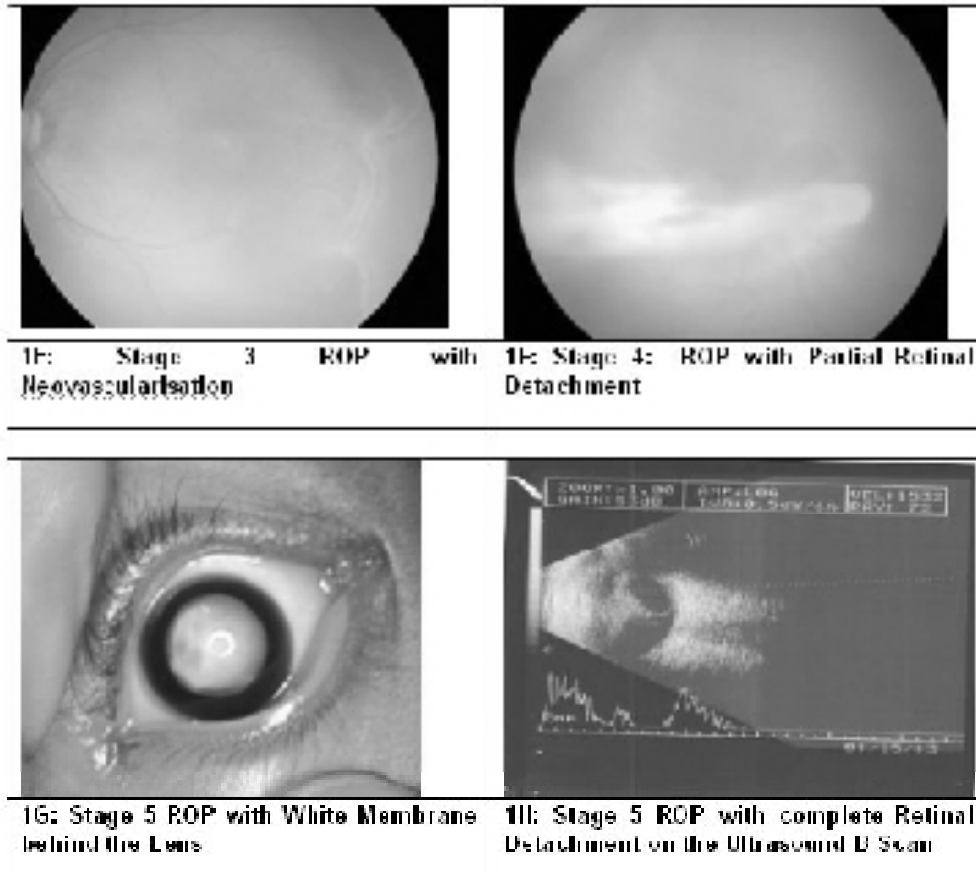
An international classification of retinopathy of prematurity was put forward by *The Committee for the Classification of Retinopathy of Prematurity* in 1984 (updated in 1987 and 2005).<sup>20</sup> This is universally accepted and followed till date.

**1. Typical or classic form of ROP:**

This form of ROP passes through five stages with increasing severity. (Fig-1)

Figure 1A to 1D: showing Normal Fundus and Different Stages of ROP





## 2. AP-ROP

This was formerly called as Rush disease or Fulminate ROP or type II ROP (Fig 2). It is now named as aggressive posterior ROP (AP-ROP). This is more commonly seen in babies with birth weight < 1200 grams or before 24 weeks of gestation. However in developing countries it is also seen in bigger babies. AP-ROP does not follow the classic pattern of stage 1 through stage 5. This disease is very aggressive and progresses rapidly to cause retinal detachment and blindness.<sup>21,22</sup> Hence in children at risk of developing this disease; the screening should be performed within two weeks after birth, follow up and the treatment be more aggressive.

## 3. Plus Disease:

Typically, this is an active form of ROP where the blood vessels at the posterior pole are dilated and tortuous (Fig 3). Presence of Plus disease signifies the need of urgent LASER or CRYO therapy, which is generally performed within 48-72 hours.

## 4. Threshold ROP:

During older times this stage of ROP (Fig 4) signified the need to treat the child with the LASER or CRYO therapy. However, presently the treatment is indicated at Prethreshold stage.<sup>23</sup>

## 5. Prethreshold ROP:

*ETROP*: Early treatment of Retinopathy of Prematurity, A randomized controlled trial, convincingly demonstrated that treatment before the Threshold stage; the stage at which treatment was recommended previously, can reduce the incidence of unfavorable structural outcomes from 15.6% to 9.0%. Hence, currently most eye surgeons prefer to treat the premature babies with ROP at Prethreshold stage. Presence of the plus disease with presence of neo-vascularization in zone 1 or 2 is an easy definition of pre-threshold ROP

## 2. Regressed ROP:

The child with ROP can regress in two patterns either spontaneously or by treatment (Fig 5 a and b). The ROP can regress by type 1, which is more common and leaves less sequelae and type 2 that leaves more

sequelae. The sequelae of the regressed ROP is known as Cicatricial ROP.

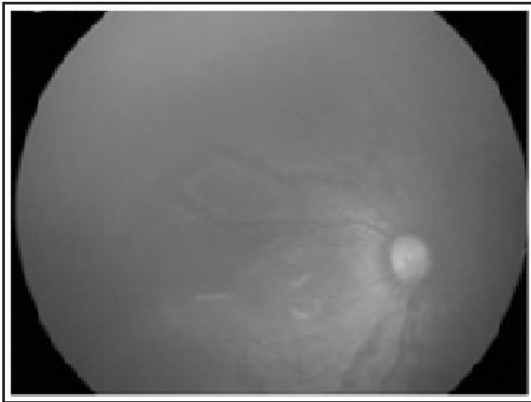
**7. Cicatricial ROP:**

A child with regressed ROP may not have any detachment of the retina but have retinal vascular abnormalities, retinal pigment alteration and the dragging of the macula (Fig 6) or optic disc with or without a retinal fold. The later abnormality can reduce the vision very severely and cause visual impairment.

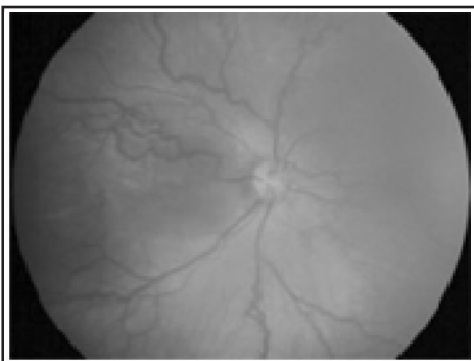
**ROP Zones:**

As mentioned above the retinal vessels develop around the optic disc area and then grow centrifugally. Depending on the location of the disease, ROP is classified into three zones (Fig 7) The ROP in Zone 1 has poorer prognosis than ROP in Zone 2 compared to that in Zone 3. Also, the Zone 1 ROP is more severe and aggressive than that in Zone 2 or 3. ROP in zone 3 generally regress spontaneously without significant negative impact on the vision.

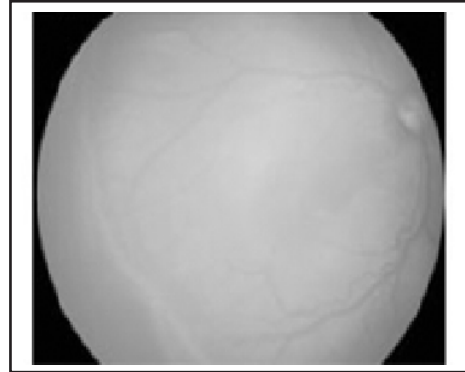
**Figure 2: AP- ROP**



**Figure 3: Plus Disease: Tortuous Dilated Blood Vessels at the Posterior Pole**

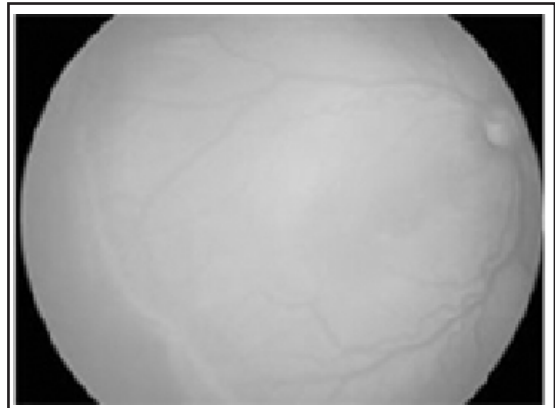


**Figure 4: Threshold ROP**

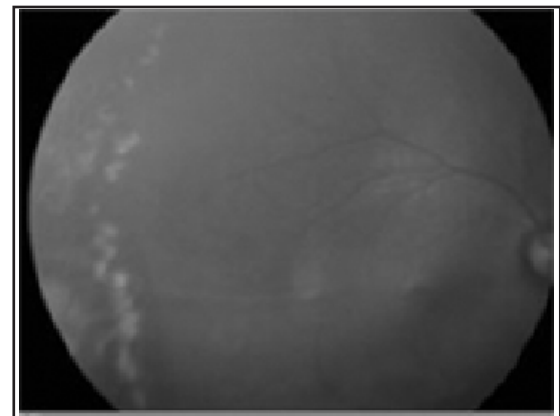


**Figure 5A and 5B: Threshold ROP before and after LASER Induced Regression**

**5A**

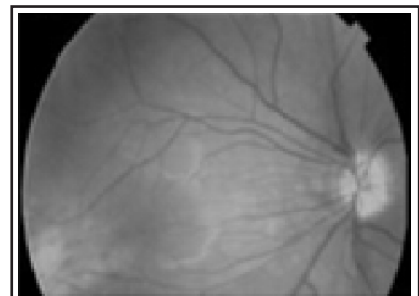

**5B**

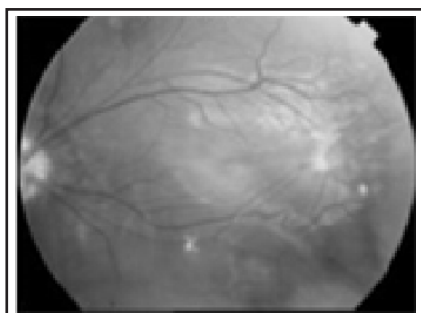

**Figure 6A and 6B: Cicatricial ROP with Macular Ectopia**

**6A**



6B



**Role of Pediatricians in ROP:**

The responsibility of getting the baby to the ophthalmologist for screening at the appropriate time rests with the pediatrician. A well organized screening strategy and timely intervention can to a large extent prevent blindness due to ROP.

**Who should be screened?**

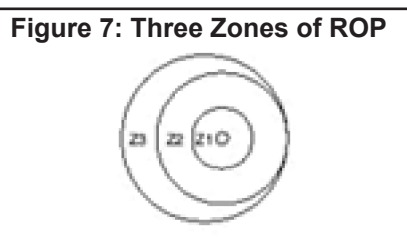
The indications recommended by the Indian ROP working group are given in table 5.<sup>24</sup>

**Table 5: The screening criteria for ROP**

Birth Weight	≤ 1700 gms
Gestational age	≤ 34-35 weeks
Exposure to Oxygen	≥ 30 days
Other Risk Factors (in babies , 37 weeks or > 2000 gms)	<ul style="list-style-type: none"> <li>• Respiratory distress Syndrome</li> <li>• Blood Transfusions</li> <li>• Sepsis</li> <li>• Multiple Births (twins/triplets etc)</li> <li>• Apnoeic episodes</li> <li>• Intracranial Hemorrhage</li> <li>• Pediatrician has an index of suspicion</li> </ul>

**When should the screening begin?**

There is an optimal time when the screening should take place. An earlier date would result in high false negatives and a later date would result in missing the treatable cases until it is too late. The sequence of events leading to ROP usually takes about 4 weeks except in a small subset of premature infants who develop fulminate or type 2 ROP in 2 weeks. Therefore routine screening should begin at no later than four weeks after the birth and possibly even earlier for infants at higher risk (2 weeks).<sup>25</sup> One session of retinal screening should be carried out before day 30 of the life of any premature baby '**THE DAY 30 STRATEGY**'.



**How frequently a premature baby should be examined?**

The answer depends on the presence or absence of the disease and its severity. This will be decided by the ophthalmologist by assessing the stage of the disease, zone of involvement and the presence or absence of plus disease.

Nevertheless, even after the ROP has resolved a premature child is at a high risk of developing other vision threatening ocular morbidity (Table 1) that require a follow up at 4 months of age to assess the refractive status and ocular alignment followed by next check up at one year to assess the functional vision.

**Can the change in nursery practice make a difference in the incidence or the outcome of ROP?**

Based on the results of the HOPE ROP study<sup>25</sup> (High Oxygen Percentage in retinopathy of prematurity study) and STOP ROP study<sup>26</sup> (Supplemental Therapeutic Oxygen for Prethreshold Retinopathy of Prematurity study<sup>26</sup>) following recommendations can be made

1. Supplemental oxygen is not found to have any additional benefit in Prethreshold or threshold ROP
2. The risk of adverse event including pneumonia and/or exacerbation of chronic lung disease is high in children who receive the supplemental oxygen
3. The clinician should individually assess the risk/benefit ratio of oxygen supplementation or curtailing the oxygen without worrying about the risk of exacerbating an active disease (ROP)
4. Avoid repeated large fluctuations in SpO<sub>2</sub> levels

**Treatment of Babies with ROP:**

It is known that spontaneous regression occur in 48% of those babies with Threshold disease giving rise to good visual and functional outcome. Out of remaining 52% children 35% are likely to develop severe vision threatening complication if not treated. The incidence of the unfavorable out come can be reduced to 9% if the LASER or CRYO is performed at prethreshold stage. However, lowering the limit from Prethreshold stage would mean treating 3 children when only one child required treatment.



Ophthalmologists apply the criteria to treat or not to treat based on the individual risk/benefit ratio. LASER photocoagulation is performed in one or more sittings within 72 hours of decision to treat. The peripheral, nonvascular retina is ablated with the LASER and the sign of regression is visible within 5-7 days. In advanced cases (Stage 4 or 5) retinal surgery is indicated which has limited success rates.

### **Other vision threatening ocular morbidity associated with Prematurity:**

#### **Myopia:**

Low birth weight, prematurity and ROP all significantly impact the refractive state in the long term.<sup>27,28</sup> At age 10-12 years children born preterm (even if there was no ROP) have an increased prevalence of all refractive errors.<sup>27</sup> The prevalence of myopia in babies with Prethreshold ROP is 64.5%<sup>28</sup> and does not change significantly with treatment. The severity and incidence of refractive error is inversely related to the gestational age and birth weight and directly related to the severity of the disease. Every premature child is recommended to have a routine eye evaluation between 4 – 6 months of age for the assessment of the refractive status of the eye and ocular alignment.

#### **Squint:**

The prevalence of strabismus in general population is 1 - 2% while at 9 months, 20 - 30% of infants with prethreshold ROP have strabismus.<sup>29</sup> The presence of strabismus in child can be associated with 1) Lack of binocularity and stereo-acuity, 2) Amblyopia, 3) Reduced field of vision, 4) 50% increased chance of losing the good eye due to injury, 5) Reduced Self esteem. An early intervention as early as 4 months of age is usually recommended.

#### **Amblyopia:**

With an increased prevalence of squint and refractive errors a child who is prematurely born has a proportionately higher incidence of Amblyopia. It can affect one eye or both the eyes and can be treated if detected early. The treatment generally entails appropriate spectacle correction and/or occlusion therapy.

#### **Cerebral Visual Impairment:**

Pre-term newborns represent a high-risk population for brain damage, primarily affecting the white matter, and for related neurodevelopmental disabilities.<sup>30</sup> This can be associated with the damage to the anterior or the posterior visual pathways leading to

severe to mild visual impairment. Nearly 19% Children have ophthalmic deficits while another 47% have both, neurological and ophthalmic deficits.<sup>31</sup> The associated ophthalmic deficits range from the strabismus in 37%, oculomotor apraxia or gaze palsy in 15%, nystagmus in 11%, optic atrophy in 17%, refractive errors in 9% and squint in 37%. These children need to have an early intervention by the vision stimulation, management of all other ocular comorbidities as mentioned above. A concurrent consultation with the occupational therapist, physiotherapist and pediatric neurologist is required in many.

**Summary:** A pre-term child is at a high risk for developing various vision threatening ocular disorders that need an early referral to the ophthalmologist for the intervention.

#### **Bibliography:**

1. Agarwal KN, Agarwal DK, Agarwal A, Rai S, Prasad R, Agarwal S, Singh TB. Impact of the integrated child development services (ICDS) on maternal nutrition and birth weight in rural Varanasi. *Indian Pediatr* 2000;37:1321-7.
2. Repka MX. Ophthalmological problems of the premature infant. *Rtard Dev Disabil Res Rev* 2002;8:249-57.
3. Leo SW, Cheong PYY. Incidence of retinopathy of prematurity in Singapore. *Singapore Med J* 1997;38:54-7.
4. Arræ M, Peitersen B. Retinopathy of prematurity: review of a seven-year period in a Danish neonatal intensive care unit. *Acta Paediatr* 1994;83:501-5.
5. Seiberth V, Linderkamp O. Risk factors in retinopathy of prematurity. A multivariate statistical analysis. *Ophthalmologica* 2000;214:131-5.
6. McKibbin M, Dabbs TR. Assisted conception and retinopathy of prematurity. *Eye* 1996;10:476-8.
7. Bergh T, Ericson A, Hillensjö T, et al. Deliveries and children born after in-vitro fertilisation in Sweden 1982-95: a retrospective cohort study. *Lancet* 1999;354:1579-85.
8. Watts P, Adams GG. In vitro fertilisation and stage 3 retinopathy of prematurity. *Eye* 2000;14:330-3.
9. Pennefather PM, Tin W. Ocular abnormalities associated with cerebral palsy after preterm birth. *Eye* 2000;14:78-81.
10. Englert JA, Saunders RA, Purohit D, et al. The effect of anemia on retinopathy of prematurity in extremely low birth weight infants. *J Perinatol* 2001;21:21-6.
11. Dutta S, Narang S, Narang A, Dogra M, Gupta A. Risk factors of threshold retinopathy of prematurity. *Indian Pediatr* 2004;41:665-71.
12. Wallace DK, Kylstra JA, Phillips SJ, et al. Poor postnatal weight gain: a risk factor for severe retinopathy of prematurity. *J AAPOS* 2000;4:343-7.
13. Nair PM, Ganesh A, Mitra S, Ganguly SS. Retinopathy of prematurity in VLBW and extreme LBW babies. *Indian J Pediatr* 2003;70:303-6.
14. Reynolds JD, Hardy RJ, Kennedy KA, et al. Lack of efficacy of light reduction in preventing retinopathy of prematurity. Light Reduction in Retinopathy of Prematurity (LIGHT-ROP) Cooperative Group. *N Engl J Med* 1998;338:1572-6.
15. Hosono S, Ohno T, Kimoto H, Shimizu M, Nozawa M, Genkawa R, Yoshida T, Wada S, Harada K. No clinical correlation between bilirubin levels and severity of retinopathy of prematurity. *J Pediatr*

*Ophthalmol Strabismus* 2002;39:151-6.

17. Ashton N. Oxygen and the growth and development of retinal vessels. In vivo and in vitro studies. The XX Francis I. Proctor Lecture. *Am J Ophthalmol* 1966;62:412-35.

18. Tripathi B, Knight G, Ashton N. Effect of oxygen on the developing retinal vessels of the rabbit. IV. Effect of hyperoxia on rabbit retinal vessels in tissue culture. *Exp Eye Res* 1974;19:449-75

19. Kissun RD, Garner A. Vasoformative properties of normal and hypoxic retinal tissue. *Br J Ophthalmol* 1977;61:394-8

20. An international classification of retinopathy of prematurity. The Committee for the Classification of Retinopathy of Prematurity. *Arch Ophthalmol* 1984;102:1130-4

21. Shah PK, Narendran V, Saravanan VR, Raghuram A, Chattopadhyay A, Kashyap M, Devraj S. Fulminate type of retinopathy of prematurity. *Indian J Ophthalmol* 2004;52:319-20.

22. Shah PK, Narendran V, Saravanan VR, Raghuram A, Chattopadhyay A, Kashyap M, Morris RJ, Vijay N, Raghuraman V, Shah V. Fulminate retinopathy of prematurity - clinical characteristics and laser outcome. *Indian J Ophthalmol* 2005;53:261-5

23. Good WV; Early Treatment for Retinopathy of Prematurity Cooperative Group. Final results of the Early Treatment for Retinopathy of Prematurity (ETROP) randomized trial. *Trans Am Ophthalmol Soc* 2004;102:233-48;

24. Jalali S, Anand R, Kumar H, Dogra MR, Azad R, Gopal L. Programme planning and screening strategy in retinopathy of prematurity. *Indian J Ophthalmol* 2003;51:89-99.

25. McGregor ML, Bremer DL, Cole C, McClead RE, Phelps DL, Fellows RR, Oden N; HOPE-ROP Multicenter Group. High Oxygen

Percentage in Retinopathy of Prematurity study. Retinopathy of prematurity outcome in infants with prethreshold retinopathy of prematurity and oxygen saturation >94% in room air: the high oxygen percentage in retinopathy of prematurity study. *Pediatrics* 2002;110:540-4.

26. Supplemental Therapeutic Oxygen for Prethreshold Retinopathy Of Prematurity (STOP-ROP), a randomized, controlled trial. I: primary outcomes. *Pediatrics* 2000;105:295-310.

27. O'Connor AR, Stephenson TJ, Johnson A, Tobin MJ, Ratib S, Fielder AR. Change of refractive state and eye size in children of birth weight less than 1701 g. *Br J Ophthalmol* 2006;90:456-60

28. Davitt BV, Dobson V, Good WV, Hardy RJ, Quinn GE, Siatkowski RM, Summers CG, Tung B; Early Treatment for Retinopathy of Prematurity Cooperative Group. Prevalence of myopia at 9 months in infants with high-risk prethreshold retinopathy of prematurity. *Ophthalmology* 2005;112:1564-8

29. VanderVeen DK, Coats DK, Dobson V, Fredrick D, Gordon RA, Hardy RJ, Neely DE, Palmer EA, Steidl SM, Tung B, Good WV; Early Treatment for Retinopathy of Prematurity Cooperative Group. Prevalence and course of strabismus in the first year of life for infants with prethreshold retinopathy of prematurity: findings from the Early Treatment for Retinopathy of Prematurity study. *Arch Ophthalmol* 2006;124:766-73.

30. Arpino C, D'Argenzio L, Ticconi C, Di Paolo A, Stellin V, Lopez L, Curatolo P. Brain damage in preterm infants: etiological pathways. *Ann Ist Super Sanita* 2005;41:229-37.

31. Huo R, Burden SK, Hoyt CS, Good WV. Chronic cortical visual impairment in children: aetiology, prognosis, and associated neurological deficits. *Br J Ophthalmol* 1999;83:670-5.

**E- published : September 2006**

---