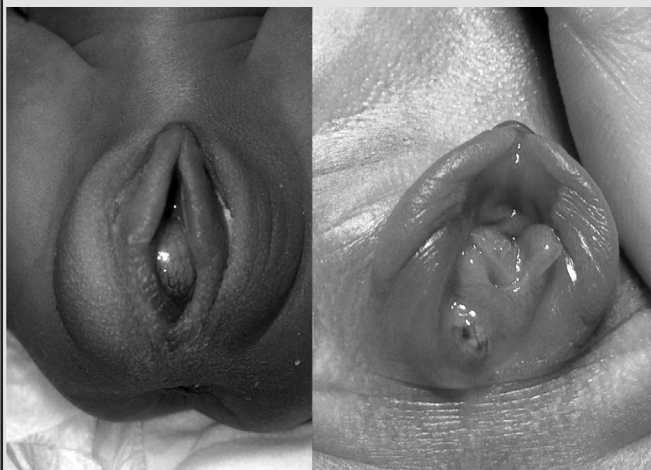


---

SPOT DIAGNOSIS (IMAGE GALLERY)

---



**NEWBORN GENITAL TUMEFACTION**

**Ana Maria Ferreira, Tatiana Pereira, Liliana Quaresma, Fátima Fonseca, Teresa Caldeira**

*Department of Paediatrics and Neonatology, Centro Hospitalar de Entre Douro e Vouga, Santa Maria da Feira, Portugal.*

---

**Address for Correspondence:** : Dr Ana Maria Ferreira, Avenida Camilo Tavares de Matos, 229, 2 no. abstrandar, 3730-240 Vale de Cambra, Aveiro, Portugal. Email: anamariaf.88@gmail.com

---

A preterm female neonate was born via caesarean section to a healthy 31-year-old woman at an estimated gestational age of 34 weeks. Preeclampsia was diagnosed at 31st weeks of gestation and a complete antenatal corticosteroid therapy cycle was administered. No evidence was found of congenital

malformations on prenatal ultrasounds. At delivery, birth weight was 1780 grams (appropriate for gestational age). Resuscitation with positive pressure ventilation was required, with an Apgar Score of 5 and 10 at 1 and 5 minutes, respectively. The baby was admitted to the neonatal intensive care unit and was managed conservatively. Her urine output was normal in the first 24 hours. At 36 hours of life she developed oligoanuria. Clinical examination revealed a 15 x 0.5 mm spherical swelling protruding in the vulvar introitus with well-defined limits, elastic consistency, yellowish and with superficial vascularization, more lateralized to the right, probably blocking the distal meatus of the urethra (Figure 1). No vaginal bleeding or breast enlargement was observed and she remained stable, except for voiding difficulty. The swelling spontaneously drained after 12 hours

with discharge of mucous material without any characteristic smell, leaving visible the glandular orifice (Figure 2). Renovesical ultrasound was normal.

Paraurethral cyst seems to be the most likely diagnosis. This is a rare cause of inter-labial vulvar swelling in a newborn female. The incidence ranges between 1 in 7000 children and the diagnosis is clinical. The etiology remains unknown, however, the obstruction of the glandular duct or cystic degeneration of embryonic remains of the paraurethral glands appear to be the most common cause. (1,2) The differential diagnosis of genital swellings in newborn is variable and should include imperforate hymen with hydrocolpos, ectopic ureterocele, prolapsed urethra and rhabdomyosarcoma apart from paraurethral cyst. (3,4) Characteristically the paraurethral cyst is oval, milky and located on either side of the urethral meatus, sometimes causing obstruction by mass effect. In this case, although the histological exam wasn't performed, the characteristics and location of the lesion, as well as the identification of the gland orifice after drainage was suggestive of the diagnosis. The management is still controversial. However, majority of reports recommend conservative treatment because of its benign, self-limited and asymptomatic nature. It is generally agreed that surgery (incision, excision or needle aspiration) should be considered when the cyst is symptomatic or persistent. (3,4)

### References

1. Moralioglu S, Bosnali O, Celayir AC, Sahin C. Paraurethral Skene's duct cyst in a newborn. *Urology Annals*. 2013; 5: 204-205.
2. Costantino E, Ganesan GS. Skene's gland cyst as an interlabial mass in a newborn girl. *BMJ Case Report*. 2016. doi:10.1136/bcr-2016-215042
3. Shashy L, Linton JM, Neonate with Interlabial Mass. *J Sci Med*. 2016; 2: 107-108
4. Nakamura E, Shintaku S, Horii M, Manabe H, Hirano Y, Muroto K. Early Regression of Paraurethral Cyst in a Neonate. *Pediatr Neonatol*. 2014; 55: 225-227

**Financial disclosure:** None

**Conflict of interest:** None

**DOI No. :** 10.7199/ped.oncall.2016.47

