

TEACHING FILE

GRAND ROUNDS

Ira Shah

HYPERLIPIDEMIA IN AN HIV INFECTED CHILD ON ANTI-RETROVIRAL THERAPY

Clinical Problem: A 9 years old boy was detected to be HIV infected in October 2014 in view of right otitis media with mastoiditis causing focal cerebritis. After treatment of this infection, his CD4 count was done which was 821 cells/cumm. However in view of a life threatening illness, he was started on anti-retroviral therapy (ART) consisting of abacavir, lamivudine and efavirenz. At the time of starting his ART, his weight was 21.5kg and systemic examination was normal. He continued to remain asymptomatic and serial CD4 counts done at 6 monthly interval remained in the range of 900-970 cells/cumm. On regular screening in June 2016, he was noticed to have hyperlipidemia (cholesterol - 201mg/dl and triglycerides were 609 mg/dl, LDL cholesterol of 150mg/dl). At that time his weight had increased to 37.6kg.

What is the cause of this hyperlipidemia? How should it be treated?

Expert Opinion: Hyperlipidemia is common in HIV-infected patients on ART, especially those on protease inhibitors (PIs) and stavudine. (1) Efavirenz can also cause increases in cholesterol and triglycerides. (2) Common lipid abnormalities seen in HIV infected individuals are very high triglyceride levels and modest increases in total-cholesterol levels. (3) LDL cholesterol is implicated in the pathogenesis of atherosclerotic cardiovascular disease and ideally, the goal should be to achieve an LDL cholesterol level of less than 110 mg/dL. (3)

There are no specific treatment guidelines for management of hyperlipidemia in HIV infected children. Non-pharmacologic measures, such as a low-fat diet, supplementation of omega-3 fatty acids, weight reduction and aerobic exercise are the main stay of therapy. Drug therapy is indicated for patients with familial combined hyperlipidemia that is associated with atherogenesis and for patients with triglyceride concentrations exceeding 1000 mg/ dL due to risk of acute pancreatitis. (3)

Drug therapy for hyperlipidemia involves statins, resins, niacin and fibric acid derivatives. (1) Many antiretroviral drugs, especially the PIs are metabolized by the cytochrome P-450 (CYP) enzyme system. Statins are also metabolized by the CYP system. Thus, plasma statin levels may increase or decrease in the presence of ART, warranting close monitoring and caution while being used. (3) Resins, such as cholestyramine and colestipol can lower total and LDL cholesterol by 10-30 percent but may increase triglyceride levels hence are not preferred in HIV infected individuals. (3) Niacin in high doses can lower LDL and total cholesterol by approximately 20-30 percent, lower triglycerides by 35-55 percent, and increase HDL cholesterol by 20-35 percent. However, it can lead to nausea, diarrhea, hepatotoxicity, and vasodilatory symptoms such as flushing which can limit its use. (3) Appropriate niacin dose in children is

still not established. (2) Fibric acid derivatives include clofibrate, fenofibrate, and gemfibrozil chiefly lower triglyceride levels and have only modest effects on LDL and HDL cholesterol, they are basically used for treatment of hypertriglyceridemia.

Monitoring low-density-lipoprotein cholesterol levels four to six weeks after the start of lipidlowering therapy and then at three months; more frequent monitoring may be necessary in HIVinfected patients.

Our patient was started on diet restricted in fats and given omega 3 fatty acid supplements. He was advised regular exercise. Three months later, his serum cholesterol was 235 mg/dl and triglycerides were 181 mg/dl with LDL cholesterol of 140mg/dl.

Funding : None

Conflict of Interest: None

References

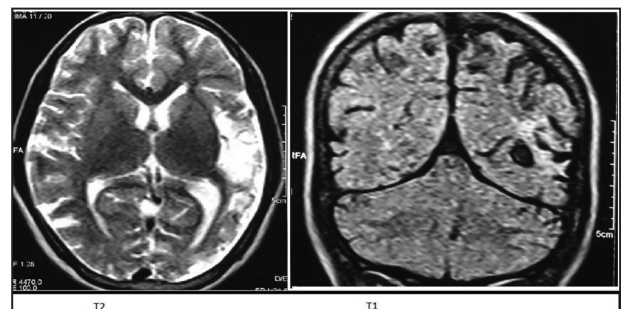
1. Geletko SM, Zuwallack AR. Treatment of Hyperlipidemia in HIV-infected Patients. *Am J Health Syst Pharm.* 2001 Apr 1;58(7):607-14.
2. Rhoads MP, Lanigan J, Smith CJ, Lyall EG. Effect of specific ART drugs on lipid changes and the need for lipid management in children with HIV. *J Acquir Immune Defic Syndr.* 2011 Aug 15;57(5):404-12.
3. Rohrs HJ. Pediatric Lipid Disorders in Clinical Practice and Management. Available at website: emedicine.medscape.com/rarticle,1825087-treatment. Accessed on 9th September 2016



DOI No.: 10.7199/ped.oncall.2016.47

POOR SCHOLASTIC PERFORMANCE IN AN HIV INFECTED GIRL

Clinical Problem: A 10 years old HIV infected girl on anti-retroviral therapy (ART) consisting of zidovudine (AZT), lamivudine (3TC) and nevirapine (NVP) for 5 years presented with poor scholastic performance. As per the mother, she had difficulty in understanding simple commands and was not performing poorly in school. On examination, neurological examination was normal. Her IQ test showed borderline IQ. Her MRI brain is depicted in Figure 1. Her CD4 count was 820 cells/cumm and HIV viral load was undetectable. Cerebrospinal fluid (CSF) was normal though HIV PCR could not be done.



What could be the cause of her worsening neurological status?

Expert Opinion: Neurological complications occurring commonly in HIV-AIDS infected individuals are either due to primary HIV infection or due to opportunistic infections. Highly active antiretroviral therapy (HAART) has been found to decrease the risk of such neurological damage however continued damage can persist inspite of vigorous antiretroviral therapy. This because HAART decreases the viral load in the blood but due to poor penetration of the drugs into the central nervous system (CNS), the virus can continue to multiple in the CNS. (1) Thus, ART should be initiated as soon as any neurocognitive impairment is diagnosed so as to prevent any irreversible neurological damage and drugs that have a better CNS penetration should be used.

References

- 1) Tozzi V, Balestra P, Bellagamba R, Corpolongo A, Salvatori MF, Visco-Comandini U, et al. Persistence of neuropsychologic deficits despite long-term highly active antiretroviral therapy in patients with HIV-related neurocognitive impairment: prevalence and risk factors. *J Acquir Immune Defic Syndr.* 2007; 45: 174-82.

Funding : None

Conflict of Interest: None



DOI No. : 10.7199/ped.oncall.2016.48

From: Medical Sciences Department, Pediatric Oncall, Mumbai.

Address for Correspondence Dr Ira Shah, 1/B Saguna, 271, B St Francis Road, Vile Parle (W), Mumbai 400056.

CONGENITAL HYDROCEPHALUS: COMMUNICATING OR OBSTRUCTIVE?

Jogender Kumar, Amitabh Singh

Clinical Problem: A two-month-old boy presented with irritability, recurrent episodes of projectile vomiting for 3 days and rapidly increasing head size for 15 days. There was no fever. He was born at term and had a birth weight of 2.69 kg with uneventful perinatal course. Baby was on breast feeds. On examination, anterior fontanelle was tense and bulging and there were widely separated squamoparietal sutures. He had sun setting of the eyes. Lumbar puncture was tried three times by different pediatricians but every time, it was a dry tap. On ventricular tap, 30 ml of cerebrospinal fluid (CSF) was removed following which irritability improved. A bedside cranial ultrasound (Figure 1) showed dilated lateral, third and fourth ventricles suggestive of communicating hydrocephalus. MRI brain (Figure 2) also showed all four ventricles dilated suggestive of communicating hydrocephalus.

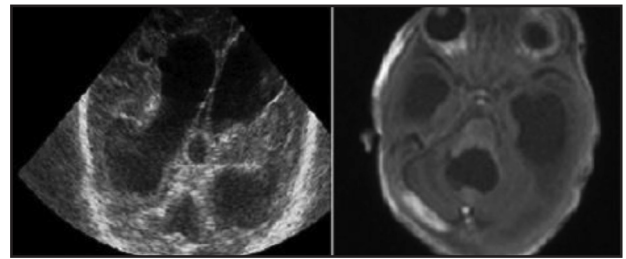


Figure 1 : Ultrasound of the skull shows dilated lateral, third and 4th ventricles

Figure 2 : MRI shows all 4 ventricles dilated

Is it is really communicating hydrocephalus? If yes, then why was the lumbar puncture a dry tap?

Expert Opinion: For such a large communicating hydrocephalus; if the obstruction is at subarachnoid granulations then there must be CSF filled subarachnoid space. However, there is no fluid in the subarachnoid space. The only possibility is there is no CSF beyond the fourth ventricle which can explain the dry lumbar tap. In view of above picture, possibility of obstruction at the level of the foramen of Magendie and Luschka was kept. The baby was taken for surgery in view of worsening hydrocephalus. During surgery, a dye was put in CSF and it was found that there was no dye going beyond the fourth ventricle so a diagnosis of atresia of foramina of Magendie and Luschka was considered. Atresia of the foramina of Magendie and Luschka is a rare cause of obstructive hydrocephalus; in literature only few cases are described. (1) As clinical features are like Dandy Walker malformation; so some authors consider it as a spectrum of the same. As seen in our patient, this entity presents as communicating hydrocephalus. Magnetic resonance imaging in such cases shows slight dilation of all the ventricles along with a significantly dilated fourth ventricle. In absence of aqueductal stenosis the enlargement of both lateral recesses of the fourth ventricle suggests the possibility of an atresia of the foramina of Magendie and Luschka. (2) The classical treatment for this entity was CSF shunting. However, recent treatment includes endoscopic ventriculostomy. Giannetti et al successfully treated one case of atresia of foramina of Magendie and Luschka by fourth ventriculostomy. (2) In our patient ventriculoperitoneal shunt was done in view of high pressure hydrocephalus.

Almost all of congenital hydrocephalus are communicating (3) but this special entity causes obstructive hydrocephalus which radiologically mimics as communicating. In such cases lumbar tap should be avoided as it may lead to herniation of brain stem.

References

1. Maloney AF. Two cases of congenital atresia of the foramina of Magendie and Luschka. *J Neurol Neurosurg Psychiatry*. 1954;17:134-138.
2. Giannetti AV, Malheiros JA, da Silva MC. Fourth ventriculostomy: an alternative treatment for hydrocephalus due to atresia of the Magendie and Luschka foramina. *J Neurosurg Pediatr*. 2011; 7:152-156.
3. Volpe JJ. Neurological Proliferation, Migration. Organization and Myelination. In: *Neurology of the Newborn*. Vol 899. 5th edn. Saunders. Philadelphia. 2008: 93

Funding: None

Conflict of Interest: None

DOI No. : 10.7199/ped.oncall.2016.53

From: Department of Pediatrics, All India Institute of Medical Sciences, New Delhi, India.

Address for Correspondence Dr. Jogender Kumar¹
Senior Resident, Pediatrics, Post Graduate
Institute of Medical Education and
Research, Chandigarh, India.160012.

Email: jogendrayadv@gmail.com

