

TEACHING FILE

GRAND ROUNDS

Ira Shah

NEONATAL CHOLESTASIS IN AN INFANT WITH RH INCOMPATIBILITY

Clinical Problem: A 1 ½ months old boy was referred for jaundice with clay stools since birth. There was history of Rh incompatibility which led to jaundice in neonatal period that required phototherapy and exchange transfusion in the baby. Subsequently the child was noticed to have direct jaundice. On examination, weight was 4.4 kg, he had hepatomegaly. Other systems were normal. Investigations showed bilirubin 6.2 mg/dl (direct=3.2 mg/dl), SGOT = 10 IU/L, SGPT = 125 IU/L, total proteins = 5.1 gm/dl, albumin= 3.1 gm/dl, alkaline phosphatase = 626 IU/L, GGTP = 250 IU/L. HIDA scan did not show excretion of tracer into small intestine even after 24 hours. An intraoperative cholangiogram (IOC) showed free flow of dye into intestines. Liver biopsy showed minimal intrahepatic and intra-canalicular cholestasis with no bile duct proliferation and mild to moderate cholangitis. After flushing the system after IOC, and supplementing with ursodeoxycholic acid (UDCA) the liver function test subsequently normalized. At last follow-up at 2 years of age, liver function tests were normal and there was no portal hypertension on doppler.

What is the likely cause of neonatal cholestasis?

Expert Opinion: The commonest cause of neonatal cholestasis with clay stools is biliary atresia. With HIDA scan showing no excretion of tracer even after 24 hours, one should rule out biliary atresia. However, one should also remember that alloimmune Rh hemolytic disease of newborn (HDN) has been reported to be a significant risk factor for cholestasis with the published prevalence of cholestasis in neonates with Rh HDN being 13–60 percent. (1) Because of excessive hemolysis, the excess bilirubin can densify as calcium bilirubinate sludge in bile ducts, leading to cholestasis (inspissated bile duct syndrome). (2) Features suggestive of inspissated bile duct syndrome include dilated bile ducts with sludge or echogenic material in the lumen, raised levels of liver enzymes including GGT, the non-excretory HIDA scan and the response to UDCA as was seen in our patient. Liver biopsy in our patient was classical of inspissated bile duct syndrome. Other predisposing factors for the development of inspissated bile in neonates include prematurity, parenteral nutrition, sepsis and diuretic therapy. (2)

Funding : None

Conflict of Interest: None

References

1. Smits-Wintjens VE, Rath ME, Lindenburg IT, Oepkes D, van Zwet EW, Walther FJ, Lopriore E. Cholestasis in neonates with red cell alloimmune hemolytic disease: incidence, risk factors and outcome. *Neonatology*. 2012; 101(4):306-10.
2. Miloh T, Rosenberg HK, Kochin I, Kerkar N. Inspissated bile syndrome in a neonate treated with cefotaxime: sonographic aid to diagnosis, management, and follow-up. *J Ultrasound Med*. 2009 Apr; 28(4):541-4.



DOI No.:10.7199/ped.oncall.2017.15

RECENT CONVERSION OF TUBERCULIN SKIN TEST

Clinical Problem: A 5 year old girl weighing 14kgs was referred in view of positive Tuberculin skin test (TST) (15mm by 2 TU) in November 2015. She had been tested as she had fever for 3 days but was currently asymptomatic. Chest X ray was normal and there was no contact with a patient having tuberculosis (TB). Her TST in August 2015 was negative. She was advised Quantiferon TB Gold test that was negative.

What is the cause of her positive TST now?

Expert Opinion: This is recent conversion of TST. Mantoux conversion is the development of new or enhanced hypersensitivity due to infection with tuberculous or non-tuberculous mycobacteria, including BCG vaccination. Mantoux conversion is defined as a change (within a two-year period) of Mantoux reactivity which meets either of the following criteria:

- A change from a negative to a positive reaction
- An increase of = 10 mm

Conversion has been associated with an annual incidence of TB disease of 4 percent in adolescents or 6 percent in contacts of smear-positive cases. (1)

Quantiferon TB Gold assay is an interferon-gamma (IFN- γ) release assay (IGRA) based on the fact that T-cells sensitized with tuberculous antigens produce IFN- γ when they are re-exposed to mycobacterial antigens. IGRAs assess response to *M. tuberculosis* proteins by measuring IFN- γ . The antigens used are not present in BCG and non-tuberculous mycobacteria and this test help to determine false positive mantoux results that may come due to these infection. The QuantiFERON-TB Gold (QFT-G, Cellestis, Australia) and the newer version QuantiFERON-TB Gold In-Tube (QFT-GIT, Cellestis, Australia) are whole-blood based enzyme-linked immunosorbent assays (ELISA) measuring the amount of IFN- γ produced in response to specific *M. tuberculosis* antigens (QFT-G: early secretory antigen target-6 (ESAT-6) and culture filtrate protein 10 (CFP-10), QFT-GIT: ESAT-6, CFP-10, TB7.7). However, ESAT-6 and CFP-10 antigens are present in *M. kansasii*, *M. szulgai*, and *M. marinum*, and sensitization to these organisms might contribute to the release of IFN- γ in response to these antigens and cause false-positive IGRA results. (2)

Thus, a positive TST and a negative QFT-GIT is suggestive of infection due to non-tuberculous mycobacteria (NTM) in this child. It is unlikely to be due to BCG vaccination as in India, BCG is given at birth and there is no recent BCG given in this child. NTMs also known as atypical mycobacteria or mycobacteria other than *Mycobacterium tuberculosis* (MOTT) usually cause infections in immunocompromised humans. NTM are ubiquitous organisms and can be isolated from soil, house dust, water, food and animals. Transmission is by inhalation, ingestion or direct contact with a contaminated environmental source. Exposure to NTM may cause a positive TST but may not lead to disease. Since the child is currently asymptomatic, this NTM infection does not require any treatment.

References

1. Menzies D. Interpretation of repeated tuberculin tests. Boosting, conversion, and reversion. *Am J Respir Crit Care Med.* 1999;159:15-21.
2. Mazurek GH, Jereb J, Vernon A, LoBue P, Goldberg S, Castro K, Division of Tuberculosis Elimination, National Center for HIV, STD, and TB Prevention, CDC . Updated Guidelines for Using Interferon Gamma Release Assays to Detect Mycobacterium tuberculosis Infection - United states .June 25, 2010 , 59(RR05) 1-25 Available at. www.cdc.gov/mmwr/ Accessed June 26, 2010



Funding : None

Conflict of Interest: None

DOI No.: 10.7199/ped.oncall.2017.32

DERMAL SWELLINGS, JOINT CONTRACTURES BUT NO GINGIVAL HYPERTROPHY

An 18 month old girl born of third degree consanguineous marriage presented with gradual restriction of movements in both the limbs for 6 months. Patient had flexion contractures of both ankles, knees, hips, elbows and limitation of movements of the spine. Pink confluent papules were present on both the ears. Bilateral parietal non-tender fluctuant swellings were seen over the scalp, which were non-transilluminant and progressively increasing in size (Fig 1). Patient had a mental delay with social quotient of 33. There was no gingival hypertrophy. Skeletal radiography showed joint contractures without any lytic or sclerotic lesion. CT scan of brain revealed soft tissue swelling over both parietal bones. (Fig 2) Histologic examination of skin biopsy of the parietal mass by light microscopy showed minimal hyperkeratosis with entire dermis showing eosinophilic homogenous ground substance with numerous fibroblasts with pericellular halo (Fig 3).

Fig 1 : Bilateral parietal swelling over scalp.

Fig 2 : CT brain showing soft tissue swelling over both parietal bones.

Fig 3 : Histology of parietal Mass shows eosinophilic ground substance with numerous fibroblasts

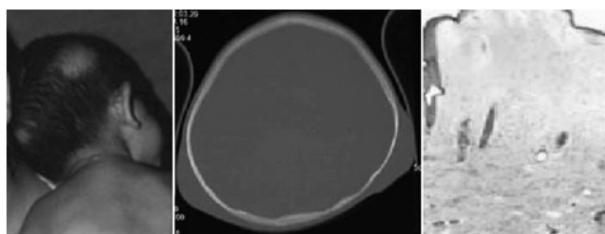


Figure 1

Figure 2

Figure 3

What is the diagnosis?

Hyaline fibromatosis syndrome. It is the current name for diseases previously known as infantile systemic hyalinosis and juvenile hyaline fibromatosis. It is a rare autosomal recessive disorder that arises from

mutation of gene ANTXR2 (anthrax toxin receptor-2), also known as gene CMG2 (capillary morphogenesis gene2), located in chromosome 4q21. (1) It has onset in infancy or early childhood and is characterized by papulonodular skin lesions, soft tissue masses, gingival hypertrophy, joint contractures and bone lesions. (2) The skin lesions consist of dermal tumors mainly on scalp and face, papules and plaques on trunk, chin, ears and nostrils. (3) Gingival hypertrophy can be severe enough to interfere with feeding. Joint contractures are seen as flexion contractures of fingers, elbows, hips and knees. (2) This disorder is characterized by production and deposition of unidentified hyaline material in the skin and other organs. (4) The fundamental defect is probably a disturbance in the metabolism of mucopolysaccharides. There is accumulation of both intracellularly and extracellularly of fibrillar glycoprotein complexes. (5) Variation in disease expression is common. Histologic features of skin tumors are characteristic and show an abundance of homogeneous, amorphous ground substance in which spindle-shaped tumor cells with elliptical nuclei are embedded. (6) Mental development and life expectancy are normal. Treatment consists of surgical excision of dermal tumors for functional and aesthetic reasons. However recurrences are common. Contractures can be decreased with capsulotomy, but improvement is transient. (2) Final outcome is a patient with deformities and joint contractures. (2)

References

1. Marques SA, Stolf HO, Polizel JO, Munhoz T, Brandão MC, Marques MEA. Hyaline fibromatosis syndrome: cutaneous manifestations. *An Bras Dermatol.* 2016 Mar-Apr ` 91(2): 226-229
2. M. Larralde, A. Santo s- Munoz, I. Calb, C. Magarinos. *Pediatric Dermatology* 2001 ` 18: 400 -402.
3. Fayad M, Yacoub A, Salman Set al. Juvenile hyaline Fibromatosis: 2 new patients and review of the literature. *Am J. Med Genet* 1987 ` 26:123-131.
4. Winik B, Boente M, Asial R. Juvenile hyaline fibromatosis intrastructural study. *Am J Dermatopathol* 1998 ` 20: 373- 378.
5. Costa OG, Costa PU. Juvenile hyaline fibromatosis *Med Cutan Ibero Lat Am* 1975 ` 3: 331-340.
6. Yesudian P, Janaki V, Thambiah F. Juvenile hyaline fibromatosis. *Int J. Dermatol* 1984 ` 23: 619- 620.

Funding : None

Conflict of Interest: None

DOI No. : 10.7199/ped.oncall.2017.7

From: Medical Sciences Department, Pediatric Oncall, Mumbai, India.

Address for Correspondence Dr. Ira Shah, 1/B, Saguna, 271/B, St. Francis Road, Vile Parle (West), Mumbai 400056 India.

