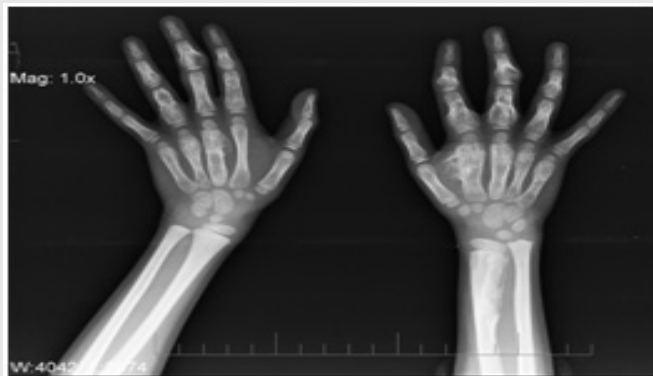


## SPOT DIAGNOSIS (IMAGE GALLERY)



### ASYMPTOMATIC SIX YEAR OLD GIRL WITH MULTIPLE BONY SWELLINGS

**Minhajuddin Ahmed\*, Manal Ashraf Ali\*\***

*\*Department of Pediatrics, Chirayu Medical College and Hospital, \*\*Department of Pathology, RKDF Medical College and Research Centre, Bhopal, MP, India.*

**Address for Correspondence:** : Dr Minhajuddin Ahmed, Department of Pediatrics, Assistant Professor, Chirayu Medical College and Hospital, Bhopal MP, India. Email: minzahmad@yahoo.co.in

A 6 year old female child presented with painless multiple swellings in bilateral hands and right foot. On physical examination swellings were painless, multiple, discrete and appears to be bony in origin. No one in family had similar problem. X ray of bilateral hands is depicted in figure 1.

#### What is the diagnosis?

X-ray of the hands shows asymmetrically distributed multiple enchondromas and few enchondroma protuberans suggestive of multiple enchondromatosis or Ollier's disease (OD). Enchondromas are rare non-familial, non-inherited benign asymptomatic cartilaginous tumor commonly intra-osseous, which develop in the metaphyses with close proximity to growth plate cartilage. (1) Multiple enchondromas are known as enchondromatosis or OD. It was first described by Ollier in 1899 and has a prevalence of 1:100000. (2) Males are affected twice than females. It is characterized by asymmetric distribution of cartilage lesions which can be of various size, numbers, location and evolution. Problems due to OD are skeletal deformity and pathological fractures and risk to develop chondrosarcoma. When multiple enchondromas are associated with soft tissue hemangiomas, then it is called as Maffucci syndrome. Diagnosis is based on clinical and radiological evaluation. (2) It is due to the changes in signaling pathway which control the proliferation and differentiation of chondrocytes leads to the formation of intra-osseous cartilaginous foci. In most patients with OD, the disease is caused by mutations in the IDH1 or IDH2 gene. (3) Roentgenogram shows multiple radiolucent, homogenous lesions which are well circumscribed, oval or elongated shape surrounded by thin rim of radio-dense bone. MRI and histological analysis has limited role and used when there is suspicion of malignancy. OD should be differentiated from hereditary multiple exostoses which is an autosomal dominant disorder characterized by multiple bone tumors capped by cartilage which occurs in metaphyses of long bones. Other rare differentials are polystotic fibrous dysplasia, diaphyseal aclasis, Kaposi sarcoma, Klippel-Trenaunay syndrome and Weber-Parks syndrome. (4)

As such there is no medical treatment available but surgery is only indicated if complications like pathological fractures, growth defect and malignant transformation occur. Early presentation can lead to more severe disease. Malignant transformation is variable in OD from 5-50 percent. (5) Other tumors has been associated with OD (4), so regular follow up is recommended.

#### References

1. Whyte M. Multiple Enchondromatosis: Ollier's disease. In: Acquired Disorders of Cartilage and Bone. Washington DC. American Society for bone and Mineral Research. 2003; 479-487.
2. Khoo RN, Peh WC, Guglielmi G. Clinics in diagnostic imaging (124). Multiple enchondromatosis in Ollier disease. Singapore Med J 2008;49(10):841-45.
3. Kumar A, Jain VK, Bharadwaj M, Arya RK. Ollier Disease: Pathogenesis, Diagnosis, and Management. Orthopedics. 2015; 38(6):e497-506
4. Maroteaux P, Le Merrer M. Les maladies osseuses de l'enfant. 3rd ed. Medecine-Sciences: Flammarion. 1995:190-2.
5. Rozeman LB, Hogendoorn PC, Bovee JV. Diagnosis and prognosis of chondrosarcoma of bone. Expert Rev Mol Diagn. 2002; 2:461-472.

**Funding :** None

**Conflict of Interest :** None



**E-published:** July-September2016. **DOI No. :** 10.7199/ped.oncall.2016. 44