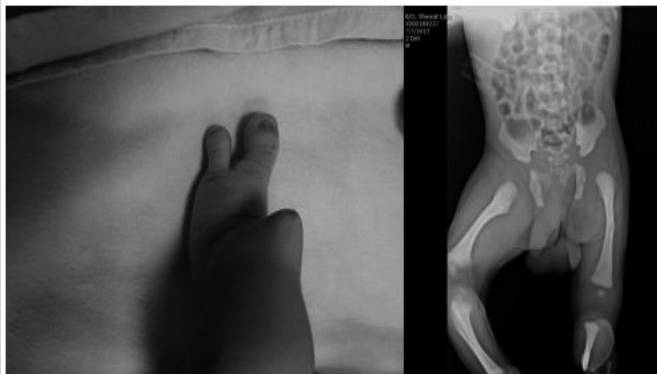


## SPOT DIAGNOSIS (IMAGE GALLERY)



### ABSENCE OF FIBULA

**Smriti Nath, Amalendu Das, Ehteshamul Hassan, Vivek Sharma**

*Department of Pediatrics, Tata Motors Hospital, Jamshedpur, India.*

**Address for Correspondence:** : Smriti Nath, 57 River View Enclave, Telco Colony, Jamshedpur-831004, India.  
Email:- smritin@tatamotors.com

A male term newborn with birth weight 2.58 kg, first born to parents of non-consanguineous marriage was delivered by emergency caesarean section for fetal bradycardia. Mother was suffering from hypothyroidism. She was on thyroid supplements. Baby had shortening of left lower limb with angulation of leg and two toes (Fig 1). Movement of both limbs were normal. X-Ray of limbs shows left sided femoral shaft angulation, short and angulated tibia with absence of fibula, two metacarpals with four phalanges (Fig 2). Other limb X-rays were normal. Echocardiography and ultrasound abdomen were normal.

### What is the diagnosis?

Fibular Hemimelia - Type II. Fibular hemimelia is a congenital lower limb anomaly characterized by partial or complete absence of fibula. (1,2) It can be associated with proximal focal femoral deficiency, absence of lateral rays and phalanges of lateral toes, syndactyly and polydactyly. There may be knee valgus, knee instability, tibial bowing and leg length discrepancy. (3) Achterman and Kalamchi classified the congenital deficiency of fibula according to severity of fibular hypoplasia (1): Type Ia- proximal fibular epiphysis distal to the level of tibial growth plate and distal fibular growth plate is proximal to the dome of talus, Type Ib- partial absence of fibula and Type II- includes complete absence of fibula. Searle et al (4) proposed Type 0 with features of fibular hemimelia syndrome except for radiographically normal fibulae. Differential diagnosis include amniotic band syndrome, thalidomide embryopathy, and femoral-facial syndrome. (5) The management is mainly surgical and includes limb lengthening procedure like Ilizarov's technique or amputation with prosthesis. (6)

### References

1. Achterman C, Kalamchi. Congenital deficiency of the fibular. *J Bone Joint Surg Br.*1979; 61(2):133-157.
2. Stevens PM, Arms D. Postaxial hypoplasia of the lower extremity. *J Pediatr Orthop.* 2000; 20: 166-172.
3. Maffuli N, Fixen JA. Fibular hypoplasia with absent lateral rays of the foot. *J Bone Joint Surg Br.*1991; 73(B):1002-1004.
4. Searle CP, Hildebrand RK, Lester EL, Caskey PM. Findings of fibular hemimelia syndrome with radiographically normal fibulae. *J Pediatr Ortho B.* 2004; 13(3):184-188.
5. Orphanet: Fibular hemimelia. Available from: [www.orpha.net/consor/cgi-bin/OC\\_Exp.php?Lng=EN&Expert=93323](http://www.orpha.net/consor/cgi-bin/OC_Exp.php?Lng=EN&Expert=93323). Accessed on June 9th 2016
6. Choi IH, Kumar SJ, Bowen JR. Amputation or limb lengthening for partial or total absence of the fibula. *J Bone Joint Surg Am.*1990; 72(A):1391-1399.

**Funding :** None

**Conflict of Interest :** None



**E-published:** July-September2016. **DOI No. :** 10.7199/ped.oncall.2016.28