

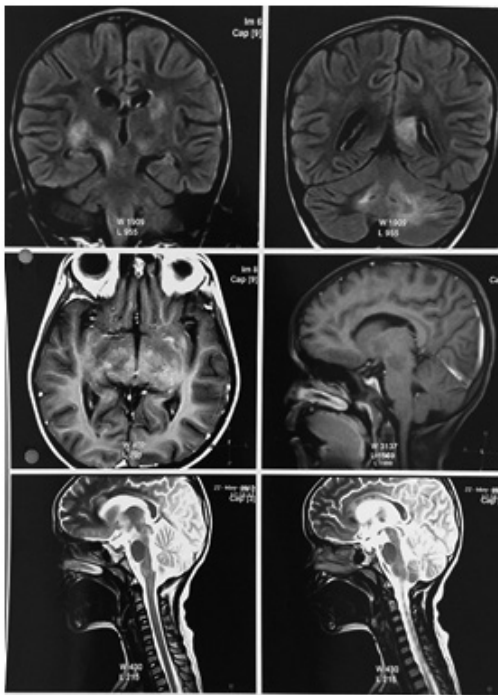
## TEACHING FILE

### GRAND ROUNDS

Ira Shah

#### DEMYELINATION IN TUBERCULOUS MENINGITIS

**Clinical Problem:** A 7 years old girl presented with fever for 15 days, and 1 episode of generalised tonic clonic convulsion followed by loss of consciousness. Her sister was suffering from fibrocavitatory TB and was on treatment with anti-tuberculous therapy (ATT) from 3 months. On examination, the patient was comatose, had neck stiffness and spasticity of bilateral lower limbs. Cerebrospinal fluid (CSF) showed 300 cells/cumm (5 percent polymorphs, 95 percent lymphocytes), 105 mg/dl of proteins and 20 mg/dl of sugar. CSF GeneXpert was positive for *mycobacterium tuberculosis* and was sensitive to rifampicin. She was started on 4 drug ATT along with steroids (for 2 months). She responded to the same, but subsequently after 3 months of therapy, she presented with abnormal movements and behavioural problems. MRI brain showed extensive demyelination.



#### How common is demyelination in CNS TB? How should it be treated?

**Expert Opinion:** Demyelination is commonly seen in tuberculous encephalopathy. It is characterized by diffuse brain edema and demyelination, which usually is extensive. (1) Patients present with impaired consciousness, seizures, disseminated intravascular coagulation, signs and symptoms of meningitis with or without spinal fluid changes. (2) Rarely central nervous system (CNS) tuberculosis presents as acute disseminated encephalomyelitis (ADEM). (3). Treatment with high dose steroids have proven to be useful. In our patient, we restarted oral steroids and ATT was continued to which she responded. She is on tapering doses of steroids.

**Funding :** None

**Conflict of Interest:** None

#### References

1. Dastur DK. The pathology and pathogenesis of tuberculous encephalopathy and radiculomyelopathy: a comparison with allergic encephalomyelitis. *Childs Nerv Syst.* 1986;2:139.
2. Cherian A, Thomas S. Central nervous system tuberculosis. *Afr Health Sci.* 2011;11(1):116-127.
3. Masoodi I, Farooq O, Ahmad I, Bhat MY, Ahmad N Wani H, et al. Acute disseminated encephalomyelitis as the first presentation of CNS tuberculosis: report of a case with brief review. *Ger Med Sci.* 2010;8:Doc32.



**DOI No.:** 10.7199/ped.oncall.2017.30

#### SPLENECTOMY WITHOUT PRIOR VACCINATION

**Clinical Problem:** A 9 years old boy presented with pain in left part of abdomen since days. There was no fever or trauma. On examination, vital parameters were normal. There was firm splenomegaly. Other systems were normal. Investigations showed hemoglobin of 10.8 gm/dl, white cell count of 9,400/cumm (with platelets of 2,49,000/cumm. Ultrasound abdomen showed 12.6 x 10.4 x 9.4 cm large hypoechoic area with internal echoes in the spleen. CT abdomen showed 12.8 x 9 cm hypodense homogenous lesion with lobulated margins suggestive of large splenic abscess. At the time of surgery, it was diagnosed to be a cyst and histopathology proved it to be an epidermoid cyst of spleen. The child is asymptomatic on follow up.

#### When to do splenectomy in splenic cysts? How to vaccinate in emergency splenectomy?

**Expert Opinion:** Splenic cystic lesions are rare. They may be congenital, neoplastic, vascular, inflammatory and post-traumatic in origin. The traditional treatment of splenic cysts had been splenectomy but it has its morbidity of leading to immunodeficiency. (1) Asymptomatic splenic cysts less than 5cm in diameter are managed conservatively with total cystectomy, marsupialization, or cyst decapsulation (unroofing), accessed either by open laparotomy or laparoscopy. Partial splenectomy preserves more than 25 percent of splenic parenchyma and can also be done laproscopically. (3) In special situation such as presence of multiple cysts, very large-sized cyst, in cases of cysts in the hilum of the spleen, a cyst completely covered by the splenic parenchyma, uncontrolled bleeding during surgery or cysts that are inaccessible for fenestration or marsupialization, one may consider doing a total splenectomy. (4) In our patient, since the cyst was very large, a total

splenectomy was done.

Patients who undergo splenectomy are at increased risk of infections due to pneumococcus, H. influenzae type B (Hib), and meningococcus. Thus, conjugated pneumococcal vaccine, conjugated Hib vaccine and conjugated meningococcal vaccine is recommended in these patients. The vaccines should ideally be given 4-6 weeks prior to a planned splenectomy. In case of emergency splenectomy, the vaccines can be given 14 or more days after emergency removal of the spleen. The polysaccharide pneumococcal vaccine (PPSV23) is given 8 weeks after the conjugated pneumococcal vaccine to cover the other serotypes. (5)

**Funding :** None

**Conflict of Interest:** None

#### References

1. Rana APS, Kaur M, Singh P, Malhotra S, Kuka AS. Splenic Epidermoid Cyst - A Rare Entity. J Clin Diagn Res. 2014; 8: 175-176.
2. Hansen MB, Moller AC. Splenic cysts. Surg Laparosc Endosc Percutan Tech. 2004; 14:316-22.
3. Karfis EA, Roustanis E, Tsimoyiannis EC. Surgical Management of Nonparasitic Splenic Cysts. JSLS?. 2009;13:207-212.
4. Macheras A, Misiakos EP, Liakakos T, Mpistarakis D, Fotiadis C, Karatzas G. Non-parasitic splenic cysts: A report of three cases. World J Gastroenterol. 2005;11:6884-6887.
5. Miniero R, Barretta M, Dolceamore TR, De Luca G, Altomare F, Chiarello P. Update on prevention of infections in patients without spleen or with diminished splenic function. Minerva Pediatr. 2013;65:427-45.



**DOI No.:** 10.7199/ped.oncall.2017.10

#### HODGKIN'S LYMPHOMA WITH TUBERCULOSIS

**Clinical Problem:** A 12 years old boy presented with evening rise of fever for 4-5 months, bilateral otorrhoea for 1 month and loss of appetite. He was treated for cervical tuberculous lymphadenopathy 3 years ago and took antituberculous therapy (ATT) for 8 months. Ten months ago he had evening rise of temperature and cervical adenopathy. Fine needle aspiration was suggestive of tuberculosis (TB) with positive acid fast bacilli. He was started on ATT which he was taking till date. His HIV ELISA was negative. On examination,

weight was 25.6 kg and height was 137 cm. He had matted cervical tender lymphadenopathy. A lymph node biopsy was done that showed complete loss of lymph node architecture and presence of Reed Steinberg cells suggestive of Hodgkin's lymphoma.

#### Can TB and lymphoma co-exist?

**Expert Opinion:** TB and lymphoma appear similar on clinical and radiological grounds and thus to differentiate between them is always a challenge. Several reports have reported coexistence of tuberculosis and non-Hodgkin lymphoma (NHL) in lymph nodes. (1-3) It is postulated that immunosuppression that occurs during treatment for lymphoma can lead to TB. (4) Also in patients with TB, the risk of NHL is significantly increased. (5) Thus in a patient with tuberculous adenitis who is not responding to treatment, in addition to ruling out drug-resistant tuberculosis, one should also rule out lymphoma.

#### References

1. Sellar RS, Corbett EL, D;Sa S, Linch DC, Ardeshta KM. Treatment for lymph node tuberculosis. BMJ. 2010; 340:c63.
2. Bellido MC, Martino R, Martínez C, Sureda A, Brunet S. Extrapulmonary tuberculosis and non-Hodgkin;s lymphoma: coexistence in an abdominal lymph node. Haematologica. 1995; 80:482-3.
3. Dres M, Demoule A, Schmidt M, Similowski T. Tuberculosis hiding a non-Hodgkin lymphoma "there may be more to this than meets the eye." Respir Med Case Rep. 2012;7:15-16.
4. Kaplan MH, Armstrong D, Rosen P. Tuberculosis complicating neoplastic disease. A review of 201 cases. Cancer. 1974;33:850-858.
5. Asklung J, Ekbohm A. Risk of non-Hodgkin;s lymphoma following tuberculosis. Br J Cancer. 2001;84:113-115.



**Funding :** None

**Conflict of Interest:** None

**DOI No. :** 10.7199/ped.oncall.2017.31

**From:** Medical Sciences Department, Pediatric Oncall, Mumbai, India.

**Address for Correspondence** Dr. Ira Shah, 1/B, Saguna, 271/B, St. Francis Road, Vile Parle (West), Mumbai 400056. India.