

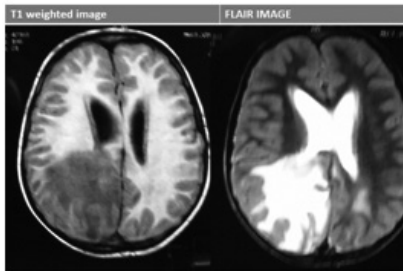
TEACHING FILE

GRAND ROUNDS

Ira Shah

SPACE OCCUPYING LESION IN THE BRAIN- WHAT IS IT?

Case: A 7 years old boy presented with fever and headache for 1 month, projectile vomiting for 15 days and altered sensorium for 1 day. There was no contact with a patient having tuberculosis. On examination, he had signs of raised intracranial tension. An MRI brain was done that showed obstructive lateral ventricle hydrocephalus with irregularly shaped heterogeneously enhancing periventricular masses in the antero-mesial aspects of both temporal lobes and in medial aspect of right occipital lobe with areas of vasogenic edema and leptomeningeal enhancement. A differential diagnosis of tuberculoma or a neoplasm was considered. The child's condition was too unstable to do a lumbar puncture. A neurosurgery opinion was taken regarding biopsy of the lesion but was not considered, again due to unstable condition of the child.



How to differentiate between tuberculoma and other space occupying lesions?

Expert's opinion: MRI is frequently performed in patients suspected to have central nervous system space occupying lesions to help in differentiating tuberculoma and other causes. Sometimes, MRI features are similar and usually not useful for differentiation. MR spectroscopy (MRS) helps to differentiate tuberculoma from other infective granulomas. While the MRI uses signals from hydrogen protons to form anatomic images, the proton MRS uses this information to determine the concentration of brain metabolites such as N-acetyl aspartate (NAA), choline (Cho), creatine (Cr), and lactate in the tissue examined. MRS of brain tuberculomas commonly detects peaks of lipids attributable to large lipid fractions in tuberculosis bacillus. It will also have increased choline levels and decreased N acetyl aspartate and creatine levels. The choline, creatine ratio is greater than 1 in tuberculomas. (1) In our patient, MRS was done and samples from the right occipital lobe lesion were taken and compared with the normal right frontal parenchyma. In the occipital lesion, there was increase in choline relative to creatine and NAA. There was a lactate-lipid peak between 1.49 and 1.28 ppm suggestive of tuberculoma. The child was started on steroids and anti-tuberculous therapy. Once his condition stabilized, a cerebrospinal

fluid examination was done which grew mycobacterium tuberculosis on culture, thus confirming the diagnosis.



DOI No.: 10.7199/ped.oncall.2016.38

HOW TO TREAT CONGENITAL SYPHILIS WHEN AQUEOUS PENICILLIN IS NOT AVAILABLE?

Case: A 3 days old baby is diagnosed to have congenital syphilis on testing with VDRL. The child is asymptomatic and had normal birth with birth weight of 3kg. Cerebrospinal fluid (CSF) VDRL is negative. Injectable crystalline penicillin and procaine penicillin is not available.

How should this child be treated?

Expert's opinion: Congenital syphilis, either proved or presumed, is treated with a 10-day course of aqueous penicillin G (100,000–150,000 U/kg/day, administered as 50,000 U/kg/dose, intravenously, every 12 hours during the first 7 days of life and every 8 hours thereafter for a total of 10 days) or procaine penicillin G (daily single dose of 50 000 U/kg/day, intramuscularly for 10 days). In case of shortage of aqueous penicillin, CDC recommends that some or all daily doses should be substituted with procaine penicillin G (50,000 U/kg/dose IM a day in a single dose for 10 days). If both aqueous or procaine penicillin G are not available, ceftriaxone may be considered with careful clinical and serologic follow-up. Ceftriaxone must be used with caution in jaundiced infants. For infants = 30 days old, it is given in dose of 75 mg/kg IV or IM/day in a single dose for 10-14 days. For older infants, this dose should be 100 mg/kg/day in a single dose. Studies that strongly support ceftriaxone for the treatment of congenital syphilis have not been done. In case of abnormal CSF examination at the beginning, a repeat CSF exam at 6 months of age if the initial exam was abnormal is recommended. (1)

In patients, if the diagnosis of congenital syphilis is not completely established, then benzathine penicillin G, 50,000 U/kg IM as a single dose can be used. Treated infants should be followed-up at 3, 6 and 12 months of age, until serologic non-treponemal tests become non-reactive or the titre has decreased fourfold. With adequate treatment or in cases in which antibody is transplacentally acquired in the absence of congenital infection, non-treponemal antibody titres should decrease by 3 months of age and be non-reactive by 6 months of age. Previously treated infants at 6–12 months of age with increasing or persistent titres should be re-evaluated, including CSF examination, and treated with a further 10-day course of if the results are abnormal.

References

1. CDC. 2002 CDC Sexually Transmitted Diseases Treatment Guidelines. MMWR 2002 ;51 (RR-6):1-80.



DOI No.: 10.7199/ped.oncall.2016.41

HYDROCEPHALUS IN TUBERCULOUS MENINGITIS?

Case: A 4 years old girl was referred as she had been on antituberculous therapy (ATT) for past 2 years 8 months. At age of 1 year 4 months, she was diagnosed as tuberculous meningitis (TBM) with hydrocephalus and was started on ATT and underwent ventriculoperitoneal (VP) shunt insertion. She was alright was next 6 months and at 2 years she developed drowsiness with right sided hemiparesis. A CT brain showed large granuloma anterior to brain stem causing upper cervical cord compression. She was thus restarted on steroids which was given for 2 months. At 2 years 4 months, she developed an encysted collection of fluid 16.4 x 13.9 cm underneath the anterior abdominal wall that required excision. At 2 years 7 months of age she developed a peritoneal pseudocyst and hence VP shunt was removed and a ventriculo-atrial (VA shunt) was put. Abdominal lymphnode biopsy was done at the same time where mycobacterium tuberculosis was isolated and 2 drugs ATT consisting of Isoniazid (H), Rifampicin (R) were continued. At 3 years 4 months of age, MRI brain was done which showed substantial regression of confluent granulomas in retroclivum region. At 3 years 10 months of age, she had headache and a fall following which VA shunt broke and again a VP shunt was reinserted. CT brain now showed disappearance of granuloma. At 4 years of age, at the time of referral, the child was asymptomatic, had normal milestones and no focal neurological deficit. Her weight was 14 kg, height was 84.5 cm, head circumference was 46 cm. Her hearing assessment, ophthalmological assessment was normal and EEG was also normal. Her ATT was thus stopped and she was advised regular follow up.

Do all patients with TBM and hydrocephalus require a VP shunt?

Expert Opinion : Hydrocephalus is the most common complication of TBM seen in up to 87 percent of patients. Early shunting with drugs therapy may offer the best therapeutic outcome. Shunt surgery does not alter the prognosis of stage III TBM as these patients usually have high mortality or are left with major disability like mental retardation, hemiparesis or blindness. Shunt surgery is indicated in patients who have failure of medical management, or have TBM with hydrocephalus and uncontrolled raised intracranial pressure. Shunt prevents the development of subsequent visual deterioration. VP shunt is preferred as it can be done in presence of active disease and early shunting with anti-TB therapy improves outcome.

The criteria for performing VP Shunt are CSF polymorphs less than 5 cells/cumm, CSF protein less than 100 mg/dl with evidence of hydrocephalus on CT scan irrespective of the number of CSF lymphocytes. In patients with Grade 1 and 2 based on Palur Grading system (1) (Table 1), in presence of periventricular edema on CT scan, shunt surgery may be required. For patients in Grade III, surgery may be performed either if external ventricular drainage causes an improvement in sensorium or without selection. As per Palur et al, all patients in Grade IV should undergo external ventricular drainage and only those who show a significant change in their neurological status within 24 to 48 hours of drainage, should have shunt surgery. (1) However, recent studies have depicted that there may be improvement in patients with Grade 4 also when VP shunt is inserted. (2,3)

Table 1 : Palur grading system for need for shunt in TBM (1)

Grade	Clinical Features	Glasgow Coma Scale
I	No neurological deficit, normal sensorium	15
II	Neurological deficit present, normal sensorium	15
III	Altered sensorium, easily arousable; neurological deficit present or absent	9-14
IV	Deeply comatose; decerebrate or decorticate posturing present or absent	3-8

References

1. Palur R, Rajshekhar V, Chandy MJ, Joseph T, Abraham J. Shunt surgery for hydrocephalous in tubercular meningitis: A long-term follow up study. J Neurosurg 1991; 74: 64-69.
2. Srikantha U, Morab JV, Sastry S, Abraham R, Balasubramaniam A, Somanna S, et al. Outcome of ventriculoperitoneal shunt placement in Grade IV tubercular meningitis with hydrocephalus: a retrospective analysis in 95 patients. Clinical article. J Neurosurg Pediatr. 2009;4(2):176-83.
3. Peng J, Deng X, He F, Omran A, Zhang C, Yin F, et al. Role of ventriculoperitoneal shunt surgery in grade IV tubercular meningitis with hydrocephalus. Childs Nerv Syst. 2012;28:209-215

DOI No. : 10.7199/ped.oncall.2016.31

From: Medical Sciences Department, Pediatric Oncall, Mumbai.

Address for Correspondence Dr Ira Shah, 1/B Saguna, 271, B St Francis Road, Vile Parle (W), Mumbai 400056.

