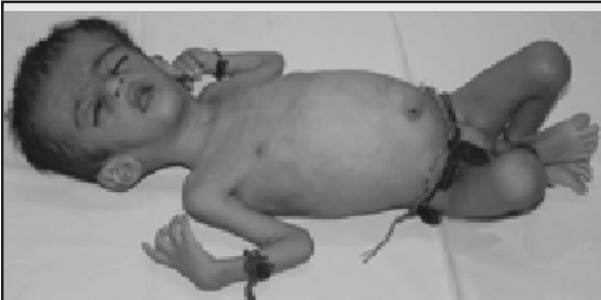


SPOT DIAGNOSIS (IMAGE GALLERY)



>>> *Vinayak Deshmukh. Assoc. Prof. of pediatrics. J.N.M.C.Sawangi Meghe. Wardha.442001.*

A full term normal male child delivered by LSCS had dysmorphic triangular face, frontal prominence, brachycephaly and widely open anterior fontanelle with low set ear, high arched palate, umbilical hernia, hypotonia, micrognathnia, blue tinge of sclera, failure to thrive, distal arthrogyriposis and lack of subcutaneous fat with no catch up in growth. His birth weight was 2.8 kg and by 3 months of age he was weighing 3.5 kg. Investigations

as chromosomal studies, x ray skull and chest were normal. Abdominal ultrasound showed small cysts on kidneys along with umbilical hernia. MRI brain showed Brachycephaly, prominent 3rd and both lateral ventricles, hypoplastic corpus callosum.

What is the diagnosis?

Silver Russell Syndrome

E-published: August 2008