

CASE REPORT

A RARE SYNDROME WITH AGENESIS OF CORPUS CALLOSUM

Moumita Samanta, Mihir Sarkar, Chanchal Kundu, Sukanta Chatterjee

Abstract

Corpus callosum agenesis is a well known feature of certain syndrome complexes of clinical significance namely, Aicardi syndrome, Smith lemli Opitz syndrome, Klinefelter, Leigh's disease etc. We present a nine month old male child with global developmental delay, chronic constipation, facial dysmorphism, microcephaly, bony deformities and repeated convulsions. Further evaluation revealed presence of ventricular septal defect, genitourinary abnormality, Hirschsprung disease and agenesis of corpus callosum fitting into the diagnosis of Mowat Wilson Syndrome (MWS). By 2007 only 171 cases have been reported worldwide and none from India till date. MWS is primarily a phenotypic diagnosis and genotypically characterized by heterozygous mutation or deletion of zinc finger E box binding homeobox 2 gene, ZEB2 previously called ZFH1B. Our case had typical phenotypic features of MWS with normal genetic study and certain unreported manifestations. Identification of this unique syndrome complex is important for genetic counseling and rehabilitation based on associated comorbid conditions.

Key words: Mowat Wilson Syndrome, Agenesis of corpus callosum

Introduction

Agenesis of corpus callosum may occur as an isolated defect, but it is frequently associated with other organ malformations and genetic syndromes. It is considered a potential marker for neurological impairment. In children, the prognosis is frequently related to other associated abnormalities. One such syndrome complex with agenesis of corpus callosum is Mowat Wilson Syndrome (MWS). It was first described by Mowat et al in 1998, consists of group of birth defects with agenesis of corpus callosum. Exact prevalence is unknown. Both males and females (1.42:1) from different ethnic backgrounds are affected with similar features. (1) It is an autosomal dominant disorder resulting from new mutations ZFH1B (zinc finger E- box binding homeobox) gene on chromosome 2q22. (2) In many cases genetic study has found to be normal. (3)

Case Report

A nine month old male child born out of nonconsanguineous marriage presented with repeated episodes of tonic generalized convulsion for one day. No history of fever. There was history of delayed developmental milestones and constipation. The antenatal, natal and immediate post natal period were uneventful. Developmental age was 6 months. Elder sibling was 6 years old and healthy. On examination, length was 69 cm (25th centile of CDC chart), weight 7 kg (<5th centile) and head circumference 42 cm (< 5th centile). Skull was irregular in shape with occipital prominence and bilateral temporal hollowing, microcephaly, closed fontanels. There was facial

asymmetry, hypertelorism, horizontal eyebrows with medial flaring, low set ears with central depression, broad nasal bridge with prominent rounded tip. Open mouth, everted lower lip, M shaped upper lip and micrognathia [Fig 1]. Short systolic murmur was heard in lower left sternal border with normal heart sounds. Mild kyphosis of spine was seen with sacral dimple, right sided cryptorchidism and left sided inguinal hernia, bilateral talipes equinovarus and bilateral abnormal sole creases. [Fig 2] Investigations like hemogram and cerebrospinal fluid analysis were within normal limits. In CT scan brain there was prominent interhemispheric fissure, absence of corpus callosum, and widely separated lateral ventricles with dilated occipital horns (colpocephaly) suggestive of agenesis of corpus callosum [Fig 3]. Diffuse cerebral dysrhythmia was seen in EEG. Small membranous subaortic ventricular septal defect of 2mm size was found in echocardiography with no evidence of pulmonary artery hypertension. Barium enema revealed dilated colon with suggestive of hirschsprung disease and confirmed by rectal biopsy [Fig 4]. Karyotyping was normal (46 XY) and genetic sequencing analysis did not reveal ZEB2 mutation. Ultrasound abdomen, renal function, liver function, lipid profile and ophthalmologic examination were within normal limits.

Discussion

Fig [1] Child with Mowat Wilson syndrome

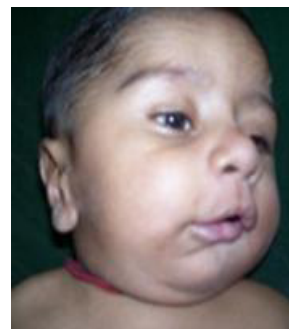

Fig [3] CT scan brain- agenesis of corpus callosum with colpocephaly

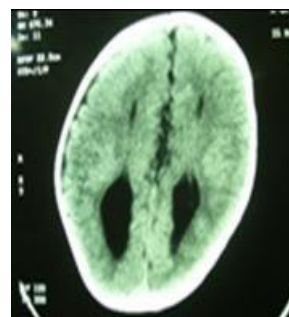


Fig [2] Bilateral abnormal sole creases

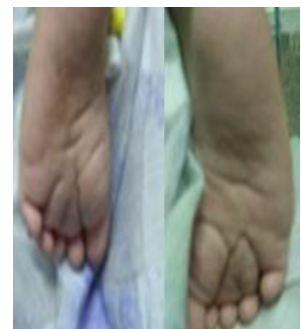
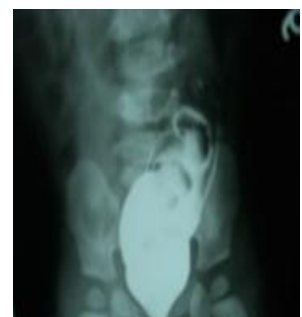
Fig [4] Barium enema- Hirschsprung disease



Mowat Wilson Syndrome is primarily a phenotypic diagnosis, with facial gestalt and delayed psychomotor development being constant clinical features. Associated congenital malformations are variable. Bilateral abnormal sole creases (fig 3) and inguinal hernia were found in this case that have not been mentioned in the literature before. The facial phenotype is particularly important for the initial clinical diagnosis (4) as seen in our case. Majority of cases are sporadic in occurrence, with low sibling recurrence risk (1%). (5) Agenesis of the corpus callosum is the only MWS feature that can be detected prenatally. (6) Agenesis of the corpus callosum and urogenital anomalies (especially hypospadias) are significant positive predictors of a ZEB2 defect. (5) However, it has been seen that individuals with typical MWS facial features have deletions and mutations of ZEB2 gene which may be too small to be detected in gene sequence analysis and Fluorescent in situ hybridization (FISH) technique. (3) This might explain the normal genetic study in our case.

Maximum survival is 30yrs with heart disease being cause of early mortality. Goldenberg Shprintzen Syndrome, a close differential diagnosis of MWS is also associated with mental retardation and hirschsprung disease. But agenesis of corpus callosum is rarely seen and facial features are strikingly different. (7) Aicardi syndrome commonly associated with agenesis of corpus callosum is X-linked dominant with male lethality. Smith Lemli Optiz syndrome is an autosomal recessive syndrome complex with midline defects was ruled out in view of normal serum cholesterol and 7-dehydrocholesterol. (8)

Identification of a syndrome complex is vital as it helps to quantify co-morbid conditions like heart disease, seizure disorder in MWS. Hence individualized guidelines for timely intervention, rehabilitation can be formulated. Owing to low recurrence risk (1%), diagnosis of MWS is important for adequate counseling and allaying apprehension of parents. To the best of our knowledge this is the first case of Mowat Wilson syndrome being reported from India with certain unreported manifestations.

Financial disclosure: none

Conflict of interest: none

References

1. Adam MP, Schelley S, Gallagher R, Brady AN, Barr K, Blumberg B, et al. Clinical features and management issues in Mowat-Wilson syndrome. *Am J Med Genet A.* 2006; 140: 2730-2741
2. Mowat DR, Croaker GD, Cass DT, Kerr BA, Chaitow J, Ades LC, et al. Hirschsprung disease, microcephaly, mental retardation, and characteristic facial features: delineation of a new syndrome and identification of a locus at chromosome 2q22-q23. *J Med Genet.* 1998; 35: 617-623.
3. Adam MP, Bean LJH, Miller VR. Mowat-Wilson Syndrome- GeneReviews-NCBI Bookshelf. Last revised February 11, 2008. Available on URL <http://www.ncbi.nlm.nih.gov/bookshelf/br.fcgi?book=gene&part=mws>.
4. Horn D, Weschke B, Zweier C, Rauch A. Facial phenotype allows diagnosis of Mowat-Wilson syndrome in the absence of Hirschsprung disease. *Am J Med Genet A.* 2004; 124A: 102-104.
5. Zweier C, Thiel CT, Dufke A, Crow YJ, Meinecke P, Suri M, et al. Clinical and mutational spectrum of Mowat-Wilson syndrome. *Eur J Med Genet.* 2005; 48: 97-111.
6. Espinosa-Parrilla Y, Encha-Razavi F, Attie-Bitach T, Martinovic J, Morichon-Delvallez N, Munnich A, et al. Molecular screening of the ZFX1B gene in prenatally diagnosed isolated agenesis of the corpus callosum. *Prenat Diagn.* 2004; 24: 298-301.
7. Zweier C, Albrecht B, Mitulla B, Behrens R, Beese M, Gillessen-Kaesbach G, et al. "Mowat-Wilson" syndrome with and without Hirschsprung disease is a distinct, recognizable multiple congenital anomalies-mental retardation syndrome caused by mutations in the zinc finger homeo box 1B gene. *Am J Med Genet.* 2002; 108: 177-181.
8. Neal WA. Disorders of Lipoprotein Metabolism and Transport in Metabolic Diseases. In: Behrman RE, Kliegman RM, Jenson HB, editors. *Nelson Textbook of Pediatrics* 18edn; Vol.1, Philadelphia, Saunders, Elsevier, 2007: 588-589.

From: Department of Pediatrics, Medical College Kolkata.

Address for Correspondence: Moumita Samanta, 123/1/6, Roy Bahadur Road, Behala, Kolkata-700034, India. Email: samanta.ritu@gmail.com

E-published: 1st December 2010 **Art#**72
