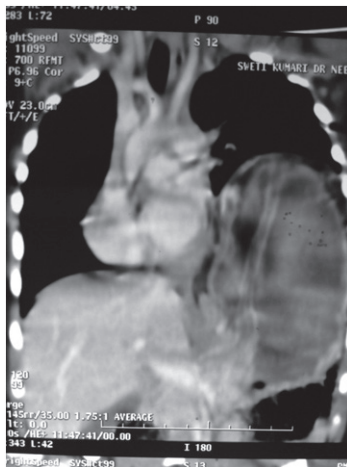


SPOT DIAGNOSIS (IMAGE GALLERY)



IS IT REALLY PULMONARY TB

***Tanvi Meha, **Anshul Raja, ***Arbind Kumar Sinha**

Department of Pediatrics, Patna Medical College & Hospital, Patna, Bihar, **Department of Radiodiagnosis, Era's Lucknow Medical College & Hospital, Lucknow, Uttar Pradesh, * Department of Physiology, Anugrah Narayan Magadh Medical College & Hospital, Gaya, Bihar*

Address for Correspondence:

Dr. Tanvi Meha, 403, Jaya Neelam Vihar, IAS Colony, Patna, Bihar, India. E-mail id: tanvimeha@yahoo.com

A 3.5 years old female child presented to pediatric outpatient department (OPD) with fever for seven days. She was on anti-tuberculous therapy (ATT) for the past 2 years when she had an episode of cough and respiratory distress. She was diagnosed to have tuberculosis (TB) on the basis of her chest x-ray by a physician. Since her chest x-ray did not improve after six months of ATT regime, the physician referred her to another doctor. She was asymptomatic at that time and the next doctor asked her to continue with the same treatment regimen. Her serial chest x-rays continued to show persistence of the abnormality and so she was referred from one doctor to another. When she reported to our OPD, she was still on ATT. On examination, she had decreased breath sounds in left infra-mammary and infrascapular regions. A gurgling sound was also appreciable. Other systems were normal. Investigations showed hemoglobin 11.3 gm%, white cell count of 14,900/cumm, erythrocyte sedimentation rate (ESR) of 34 mm at end of 1 hour. Renal and liver function tests were normal. HIV Elisa and Mantoux test were negative. Her CT chest is depicted in Figure 1.

Is this pulmonary TB?

In this patient, chest x-ray postero-anterior view showed elevation of left hemidiaphragm with mediastinal shift towards right side. Ultrasonography of abdomen showed eventration of left hemi-diaphragm with left kidney being visualized in left thoracic area. Intravenous pyelography was done to rule out any associated renal anomaly and it showed left thoracic kidney. Contrast enhanced computed tomography of chest showed considerably elevated left hemidiaphragm with marked mediastinal displacement to right with upward displacement of bower loops and left kidney underlying the diaphragm (Figure 1). The findings were suggestive of diaphragmatic eventration with left thoracic kidney.

Eventration of diaphragm causes elevation of the entire hemidiaphragm. Congenital type is the result of either incomplete development of the muscular portion or central tendon or abnormal development of phrenic nerves. (1) Clinical manifestations are varied. Most cases are asymptomatic at birth and later present with failure to thrive, acute or recurrent chest infections and respiratory distress which can be life threatening requiring mechanical ventilatory support. (2) Most eventrations are asymptomatic and do not require repair. The choice of operation is diaphragmatic plication. (3) Ectopic kidneys are thought to occur in approximately 1 in 1000 births, but only about 1 in 10 of these is ever diagnosed. With a prevalence rate of less than 0.01 percent, intrathoracic kidneys represent less than 5 percent of all renal ectopias; indeed, it has the lowest frequency rate among all renal ectopias. It has therefore a reported incidence of less than 5 per 1 million births. (4,5) Usually it is asymptomatic and cases are often diagnosed incidentally by chest radiograph performed for other causes. It must therefore be borne in mind in the evaluation of patients with suspected elevated hemi diaphragm or masses in the inferior aspect of the thorax. Our patient was misdiagnosed as TB and given ATT for 23 months but was eventually diagnosed to be left thoracic kidney. Thus it is important to know that every abnormal chest X-ray does not mean TB.

REFERENCES:

1. Sutton D. Text book of radiology and imaging. 7th Edition. Churchill livingstone. London. 2003: 51-53
2. Irene MI, Booker PD. Congenital diaphragmatic hernia and Eventration of the diaphragm. In Lister J, Irene MI, eds. Neonatal surgery. 3rd edition. London. Butterworth. 1990: 214.
3. Tiryaki T, Livanelioglu Z, Atayurt H. Eventration of the diaphragm. Asian J Surg. 2006; 29:8-10.
4. Chong SL, Chao SM. An unusual cause of mediastinal mass - a case report and literature-review of intrathoracic kidney. Proc Singapore Healthcare. 2012; 2: 144
5. Aydin HI, Sarici SU, Alpay F, Gökçay E. Thoracic ectopic kidney in a child: a case report. Turk J Pediatr. 2000;42:253-5.

Funding: none

Conflict of Interest: none

DOI No. : 10.7199/ped.oncall.2017.38

