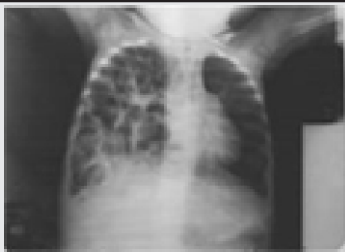


SPOT DIAGNOSIS (IMAGE GALLERY)



>>> Emmanuel Onyekwelu,
Department of Pediatrics, Royal Victoria Teaching Hospital, Banjul The Gambia
West Africa. E-Mail:euonyekwelu@hotmail.com

Spot Diagnosis

Chest radiograph reveals an anterior parasternal hernia with multiple air filled spaces with haustrations suggestive of intestinal loops within the right hemi-thorax suggestive of Congenital diaphragmatic hernia {CDH}. It is characterized by an incomplete formation or fusion, muscularization of the diaphragm resulting in apparent absence of the diaphragm or eventration. The three basic types of CDH include the posterolateral Bochdalek hernia {occurring at approximately 6 weeks gestation}, the anterior Morgagni hernia and the hiatus hernia. Cryptogenic congenital diaphragmatic hernias has been a cause of sudden deaths in the early months of life. Mortality is significant at 50 percent depending on the other associated malformations. Associated high mortality rates which have not improved significantly despite advanced novel aggressive intensive perinatal and infantile interventions, are related directly to co-existent pulmonary hypoplasia or intractable persistent pulmonary hypertension, which are usually recalcitrant. Advanced novel therapies for CDH have included delayed operation, extracorporeal membrane oxygenation {ECMO}, high frequency oscillatory ventilation {HFOV}, surfactant ,and inhaled nitric oxide {INO} therapy. However,the effects of these modalities in terms of proffering a statistically significant survival advantages in neonates with CDH have not been clearly determined. Surgical intervention of these defects is almost always indicated. This child in addition had hepatitis and multicystic kidney.