

## CASE REPORTS

### A CASE OF UNKNOWN BUTTON BATTERY INGESTION PRESENTING AS RECURRENT RESPIRATORY INFECTIONS AND RESULTING IN SEVERE ESOPHAGEAL INJURY, TRACHEAL COMPRESSION, AND VOCAL CORD PARALYSIS

Stephanie Schroter, Stacey Ulrich

#### Abstract

Foreign body ingestions in the pediatric population are often un-witnessed making them difficult to diagnose in the young child. Button battery ingestions can cause significant tissue damage in short periods of time and thus need prompt identification and removal. This case report discusses button battery ingestion presentation, management, and consequences.

**Keywords:** button battery; foreign body ingestion

#### Introduction

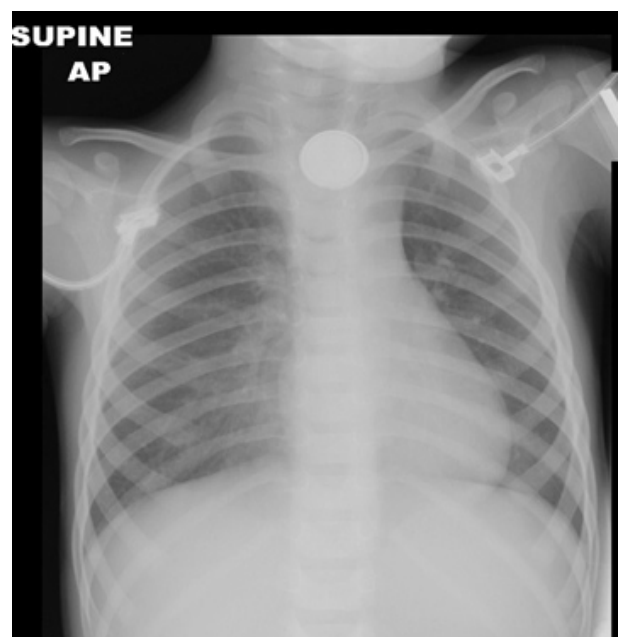
Foreign body ingestions are a common pediatric emergency room complaint. Un-witnessed foreign body ingestions are challenging as they can present with a wide array of nonspecific symptoms. They can have dire consequences if undiagnosed for as short as 30 minutes in some cases. (1,2) Ingestions often occur at a young age creating an extra diagnostic dilemma for the physician. The patient is unable to report the ingestion and parents may be unaware that it occurred. Here we describe a 21-month old female with an un-witnessed button battery ingestion. Initially she was diagnosed with recurrent respiratory infections. She developed significant weight loss, refusal to eat, and trouble breathing, which prompted further evaluation and diagnosis.

#### Case Report

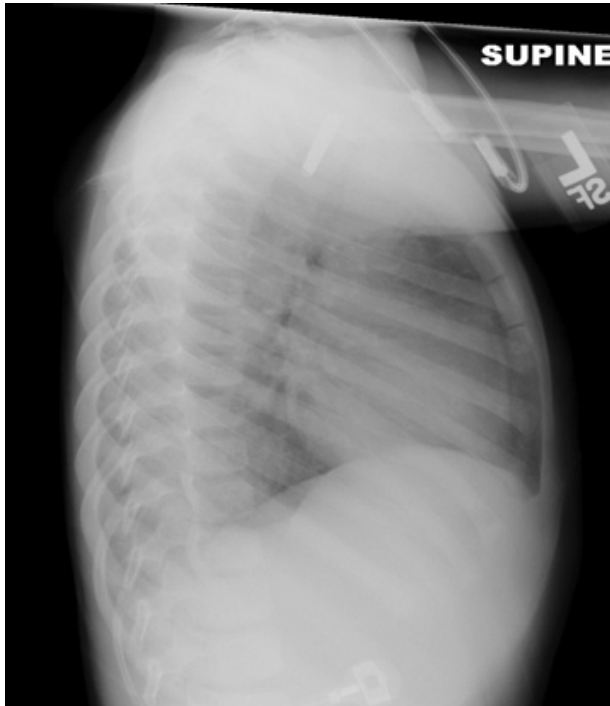
A 21-month old female child presented to the emergency department with a 3-week history of decreased oral intake. Three weeks prior the patient had upper respiratory illness symptoms and was diagnosed with croup. She then developed poor oral intake for which she was re-evaluated. This was speculated to be from her respiratory illness. Her intake continued to worsen with refusal to eat anything for 3 days. The patient's mother reported that she would immediately spit out any food or water given to her. She had only one wet diaper in the past 24 hours. A 5-pound (2.3 kg) weight loss had been documented over the prior 3 weeks. She was seen by her primary care doctor and referred to our facility for lethargy, severe dehydration, and malnutrition. Review of systems was noted to be positive for cough and congestion, negative for fever, diarrhea, and vomiting. Past medical history was remarkable for 2 hospitalizations for bronchiolitis at ages 13 months and 15 months of age. On examination her weight was 8.8 kg, temperature 37.40C, pulse 117/min, respiratory rate 27/min, blood pressure 100/80 mm of Hg, oxygen saturation 99% on room air but had been as low as 86% in ambulance transport. Physical examination was notable for cachexia and moderate distress. Her eyes were sunken, lips and mucous membranes were dry. She had coarse breath sounds and rhonchi bilaterally with mild retractions. Her skin had poor turgor with tenting and capillary refill delayed at 4 seconds. She had overall decreased tone and strength. Other systems were normal. Admission investigations showed

sodium of 147 mmol/L, potassium of 3 mmol/L, BUN of 42 mg/dL, creatinine of 0.7 mg/dL, and uric acid of 13.9 mg/dL. Other laboratory values were within normal limits. An intravenous (IV) line was placed and she was given a normal saline bolus of 20 ml/kg. Chest X-ray revealed a metallic foreign body consistent with a button battery in the upper esophagus (Fig. 1). The esophagus was separated anteriorly from the tracheal air column suggestive of esophageal edema. Parents were unaware of any ingestion but estimated it may have occurred up to 6 weeks prior. Otolaryngology was consulted and took her to the operating room for endoscopy. The battery could not be visualized and appeared to have eroded through the esophageal wall as an anterior esophageal mass was seen. There was debris and inflammation in the esophagus with a risk for perforation. Bronchoscopy was performed and revealed considerable mid trachea narrowing due to posterior tracheal wall compression from the battery. A neck incision was made and neck exploration was performed to remove the battery. It had become walled off between the esophagus and trachea. After removal of the battery, her airway remained compressed and a gastrostomy tube was placed for enteral feeds. General surgery and otolaryngology followed her closely as an outpatient. She required numerous esophageal dilations due to development of a stricture and diverticulum. Over the following few months, she became more stridulous. She was found to have bilateral vocal cord paresis and persistent airway compression requiring tracheostomy tube placement.

**Fig 1 : AP Chest X-ray demonstrating button battery.**



**Fig 2: Lateral Chest X-Ray demonstrating button battery.**



### Discussion

Button battery ingestions occur most commonly at ages 1-3 years and in the elderly where it is often mistaken for a pill. (1) The most dangerous of the batteries is the  $\geq 20$  mm lithium coin cell battery (button battery) where ingestion results in worse clinical outcomes. (3) Between the years 1985 and 2014 there were a total of 73,647 button battery ingestions reported to the National Poison Data System. (4) There were 973 moderate/major outcomes and 197 total deaths. (4) Litovitz et al (2010) defined a moderate outcome as more pronounced, prolonged, or multiple signs or symptoms such as blood in the stool or emesis, or documented mucosal burns, without sequelae. (3) A major outcome was defined as life-threatening signs or symptoms, or significant residual disability resulting from the ingestion such as mucosal burns with protracted healing and/or long-term sequelae, systemic effects, perforations, or fistulas. (3) It is thought that the injury to the esophagus occurs due to the following factors: caustic injury, electrical mucosal injury/burn, absorption of toxic heavy metals, and direct pressure necrosis. (2) The clinical course depends on the location of the battery, duration of mucosal exposure, and the remaining voltage and chemical composition of the battery. (2) Lithium batteries have a higher voltage than alkali batteries so it is speculated that a higher electrical current flows through the tissue causing more severe injury. (2)

There are 3 distinct sites where an esophageal foreign body may lodge: the cervical esophagus, the aortic arch area, or the lower esophageal sphincter. (2) Battery ingestions can have a variety of symptoms

that range from vomiting, drooling, dysphagia, odynophagia, globus sensation, coughing, stridor, choking to being completely asymptomatic. (5) Vocal cord paralysis has also been described due to local infiltration by the battery and inflammation. (6) Many children with vocal cord paralysis require mechanical intubation and enteral feeding. (6)

Button battery ingestions can lead to significant damages that include: esophageal perforation, tracheoesophageal fistulas, vocal cord paralysis and aorto-esophageal fistula formation with subsequent hemorrhagic shock and death. (1) The complications that arise from the ingestions are mainly due to duration of the impaction. In a retrospective analysis by Denney et al. they found that any foreign bodies in situ for more than 24 hours were more likely to cause esophageal ulceration (46%) as compared to those in situ for less than 24 hours (23%). (7)

Whenever there is suspicion of a foreign body ingestion, anterior-posterior and lateral chest radiographs should be done to promptly identify an esophageal foreign body. (3) An urgent radiograph is only waived in asymptomatic patients older than 12 years that ingested a  $\leq 12$  mm button battery because significant complications are unlikely in this scenario. (3) In management of button battery ingestions it is crucial to perform prompt rigid esophagoscopy with removal of the battery as injury may occur in as little as 30 minutes. (2) It has also been proposed to perform a second look endoscopy about 24 to 48 hours after the removal to reassess the injury and re-grade it, which may help in further management. (2) If the battery is in the stomach or intestines in an asymptomatic patient it may be left to pass spontaneously with inspection of the stool and a repeat radiograph in 10 to 14 days to confirm passage. (3)

Even after removal the patient may still develop complications as was seen in our patient. Tracheoesophageal fistulas can become symptomatic within 9 days after removal and arterial fistulas may become symptomatic up to 18 days after removal. (3) Monitoring of the patient depends on the risk of esophageal perforation and fistula formation with neighboring structures. Those at risk should be closely monitored as inpatients with serial imaging and stool guaiac. Subsequent early intervention is required if there is any evidence of bleeding. (3) Bronchoscopy is considered superior to esophagoscopy in diagnosing tracheoesophageal fistulas because it is better at identifying small fistulas hidden behind mucosal folds. (8)

### Conclusion

A pediatric patient with new onset respiratory symptoms and decreased oral intake may easily mislead a physician to diagnose a respiratory infection. Button battery ingestions can cause significant damage with injury occurring as quickly as 30 minutes after ingestion.

**Funding :** None

**Conflict of Interest :** None

**References :**

1. Litovitz T, Whitaker N, Clark L. Preventing battery ingestions: an analysis of 8648 cases. *Pediatrics*. 2010;125(6):1178-83.
2. Ruhl DS, Cable BB, Rieth KK. Emergent Treatment of Button Batteries in the esophagus: Evolution of Management and Need for Close Second-Look Esophagoscopy. *Ann Otol Rhinol Laryngol*. 2014;123(3):206-13.
3. Litovitz T, Whitaker N, Clark L, White NC, Marsolek M. Emerging Battery-Ingestion Hazard: Clinical Implications. *Pediatrics*. 2010;125(6):1168-77.
4. Battery Ingestion Statistics. National Capital Poison Center. Available on URL: <http://www.poisson.org/battery/stats.asp>. Accessed on 13 May 2015
5. Jayachandra S, Eslick GD. A systematic review of paediatric foreign body ingestion: presentation, complications, and management. *Int J Pediatr Otorhinolaryngol*. 2013;77(3):311-7.
6. Simonin M, D'Agostino I, Lebreton M, Jughon O, Hamza J, Oualha M. Bilateral vocal palsy following coin cell lithium battery ingestion: a case report and review. *Eur J Pediatr*. 2013;172(7):991-3.
7. Denney W, Ahmad N, Dillard B, Nowicki MJ. Children will eat the strangest things: a 10-year retrospective analysis of foreign body and caustic ingestions from a single academic center. *Pediatr Emerg Care*. 2012;28(8):731-4.
8. Wurzel DF, Masters IB, Choo KL, Isles AF. A Case for Early Bronchoscopic Airway Assessment After Disc Battery Ingestion. *Pediatr Pulmonol*. 2014;49(3):E72-4.

---

**From:** Emergency Department.

**Address for Correspondence:**

Stephanie Schroter, 3020 Childrens Way, MC5124, San Diego, CA 92103, USA.



**Email :** [sschroter@ucsd.edu](mailto:sschroter@ucsd.edu)

**DOI No.** 10.7199/ped.oncall.2015.58

---