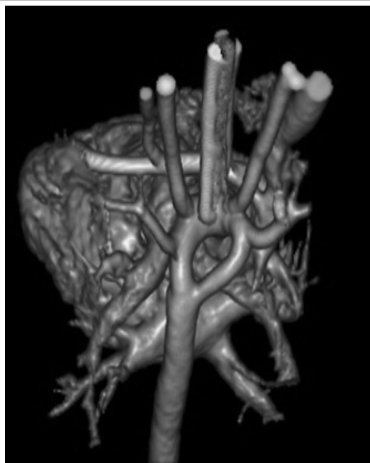


SPOT DIAGNOSIS (IMAGE GALLERY)



STRIDOR SINCE BIRTH

Marcos Vinícios Razera*, **Valéria de Carvalho Fagundes****, **Leonardo Milanesi Possamai*****, **Bruna Cogo Tempes*****, **Luciana de Oliveira*****, **Orlando Carlos Belmonte Wender******, **José Carlos Soares de Fraga*****

* Department of Pediatrics, Federal University of Rio Grande do Sul (UFRGS), Brazil** Department of Neurology, Porto Alegre Clinical Hospital, Brazil***Department of Pediatric Surgery, Porto Alegre Clinical Hospital, Brazil **** Department of Cardiovascular Surgery, Federal University of Rio Grande do Sul (UFRGS), Brazil

Address for Correspondence:

Dr Marcos Vinícios Razera, Rua Gomes Jardim, 372/501 – Bairro Santana – Porto Alegre/RS, Brasil. E-Mail: mvrzera@gmail.com

A 2950g newly born male child had episodes of stridor since the first hours of life. One month after birth, he was hospitalized with respiratory failure associated with sepsis that led to cardiorespiratory arrest. After clinical management, during a fiberoptic bronchoscopy a pulsatile structure causing tracheal compression was found. An arterial angiography (figure) showed the vascular anatomy. He underwent surgery at 3 months of age and has responded to therapy.

What is the diagnosis?

Expert opinion: Double aortic arch (DAA) compressing the trachea and the esophagus. Congenital anomalies of the aortic arch, also known as vascular rings (VR), are a group of malformations comprising 1-3 percent of all congenital heart disease. They are twice more common in males and are associated with other congenital anomalies in 50 percent of cases: ventricular septal defect, tetralogy of Fallot, aorta coarctation and patent ductus arteriosus. (1) It can compress the tracheobronchial and, or esophagus tree, causing symptoms associated with these structures. The DAA is considered a complete VR because the trachea and the esophagus are completely surrounded by the anomalous field, and represents 32-42 percent of the VR cases. (1) The ascending aorta is divided into two separate arcs: the anterior arch has a similar course to the normal left aortic arch; right attends later and left the esophagus and joins the left arc. (2) The clinical presentation varies from severe airway obstruction in neonates to asymptomatic adults. The most common respiratory symptoms are related to tracheal stridor, infections, respiratory failure, sneezing and coughing, and esophagus are dysphagia, difficulty swallowing and vomiting. (1) The sequence of diagnostic tests is not consensual. It is suggested that the chest radiograph is followed by an echocardiogram and magnetic resonance imaging to assess pulmonary pathology, the laterality of the lesion and elucidate the cardiac and vascular anatomy. Children with airway obstruction and, or stridor associated with feeding difficulties, cyanosis, apnea, failure to thrive, or pulmonary symptom must undergo a fiberoptic bronchoscopy. (3) In the differential diagnosis, tracheoesophageal fistula, gastroesophageal reflux, recurrent pneumonia, asthma, esophageal mobility disorder, mediastinal tumors or other compression causes can be suspected, especially when chest x-ray and barium swallow are done. Other differential diagnosis that can be diagnosed by laryngoscopy and, or fiberoptic bronchoscopy are laryngomalacia, laryngeal cysts, subglottic stenosis, tracheomalacia, polyps or paralysis of vocal cords. (4) The only definitive treatment is surgery, with low risk to the patient and satisfactory results. (1) It is indicated for symptomatic patients. On follow-up, 50 percent of patients may have residual pulmonary function abnormalities attributed to residual tracheomalacia and local stenoses. (5)

REFERENCES:

1. Humphrey C, Duncan K, Fletcher S. Decade of experience with vascular rings at a single institution. *Pediatrics* 2006; 117:e903.
2. Türkvatan A, Büyükbayraktar FG, Ölçer T, Cumhuri T. Congenital Anomalies of the Aortic Arch: Evaluation with the Use of Multidetector Computed Tomography. *Korean J Radiol.*2009; 10(2):176-184.
3. Longo-Santos LR, Maksoud-Filho JG, Tannuri U, Andrade WC, Gonçalves MEP, Cardoso, SR, et al. Vascular rings in childhood: diagnosis and treatment. *J Pediatr (Rio J)* 2002; 78 (3): 244-50.
4. Shah RK, Mora BN, Bacha E, Sena LM, Buonomo C, Del Nido P, et al. The presentation and management of vascular rings: an otolaryngology perspective. *Int J Pediatr Otorhinolaryngol* 2007; 71:57.
5. Jain S, Kleiner B, Moon-Grady A, Hornberger LK. Prenatal Diagnosis of Vascular Rings. *J Ultrasound in Med* 2010; 29: 287-294.

Funding: none

Conflict of Interest: none



DOI No. : 10.7199/ped.oncall.2017.29