
LETTER TO EDITOR (VIEWERS CHOICE)

GIANT JUVENILE FIBROADENOMA OF THE BREAST IN A PREADOLESCENT GIRL

Seema Dayal*, K M Shukla**, Amit Singh***

Abstract

Fibroadenomas are benign neoplasms usually seen in between the age of 15 to 25 years. Approximately 0.4% fibroadenomas arise in juvenile age group. Juvenile giant fibroadenoma is a rare benign breast tumor seen in adolescent female. It is characterized by rapid growth of mass measuring more than 5 cm or weight more than 500 grams. We present a 10 years old girl with giant juvenile fibroadenoma of right breast measuring 6.5x5x4cm in size that was surgically excised and diagnosis was made on histopathology.

Keywords : Giant juvenile fibroadenoma, pre-adolescent girl, breast

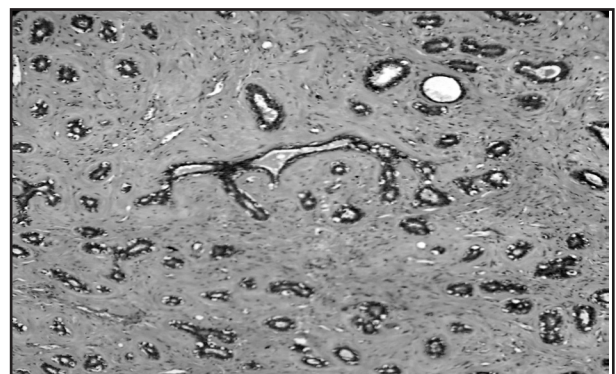
Introduction

Breast lumps are rare during the childhood and adolescent age. Most of them are due to infections, trauma and cystic swellings. Fibroadenoma is most common benign breast tumor usually encountered during puberty. It is comprises of both fibrous and glandular tissue. (1) Fibroadenoma is called giant when they attain the size more than 5 cm and/or weigh more than 500 grams. Giant fibroadenoma is classified into adult and juvenile type. Juvenile fibroadenoma is a rare variant which comprising 4% of all fibroadenomas of which giant juvenile fibroadenoma constitutes only 0.5%. (2) We report a pre-pubertal girl of 10 years who presented with giant juvenile fibroadenoma.

Case : A 10 years old pre-pubertal girl presented with lump in right breast for 5 months which was increasing in size and associated with pain. There was no history of trauma, nipple discharge, fever or weight loss. On examination, slightly tender, mass was present in right sided breast which was firm and not fixed to underlying breast. Axillary lymphadenopathy was absent. The overlying skin was tense and shiny. Routine hematology and biochemistry examinations

were normal. Ultrasonographic examination showed heterogeneous parenchymal pattern suggestive of fibroadenoma. The patient underwent total excision of right breast lump conserving the normal breast tissue, nipple and areola. Tumor measured 6.5x5x4cm on excision. Histopathology showed hyperplasia of both epithelial and stromal components suggestive of giant juvenile fibroadenoma. Glands were lined with monolayer epithelium and pericanicular pattern. Stroma was also cellular. (Figure 1)

Figure 1: Histopathology of breast showing hyperplasia of epithelial and stromal components.



Discussion

According to the Stanford school of Medicine, juvenile fibroadenoma of breast is defined as circumscribed, often large breast mass occurring in adolescent females with stromal and epithelial hypercellularity but lacking the leaf like growth pattern of phyllodes tumor. (3) Fibroadenomas of the breast are benign and typically present as firm, mobile, painless, palpable breast mass. The nomenclature of fibroadenoma in younger women is confusing and

a plethora of names exists to designate the lesion such as age related term juvenile fibroadenoma and size related term giant or massive fibroadenoma. (4) Juvenile fibroadenoma is a variant which occurs in young adults and adolescents, most patients being 10-20 years of age with a mean age of 15 years. It is frequently seen in young and black female. Exact pathology is not known, hormonal influences are thought to be contributing factor. Excessive estrogen stimulation and / or receptor sensitivity or reduced levels of estrogen antagonist during puberty have been implicated in pathogenesis. (5,6) The important differential diagnosis of giant juvenile fibroadenoma include low grade phyllodes tumor, virginal hypertrophy, lipoma, hamartoma, breast abscess, macrocyst, adenocarcinoma and pseudo angiomatous stromal hyperplasia. (7) It is important to differentiate juvenile fibroadenoma from these entities. Clinical examination along with ultrasonography are useful modalities for its diagnosis whereas histopathology examination is required to confirm the diagnoses. Total excision of lump with conservation of nipple and areola is the optimal treatment. (8)

Funding:None

Conflict of Interest :None

References :

1. Rosai J. Breast. In: Rosai and Ackerman's Textbook of surgical pathology. 9th ed, vol 2 New Delhi. Elsevier; 2004: 1769-1772.
2. Park CA, David LR, Argenta LC. Breast asymmetry: presentation of a giant fibroadenoma. Breast J. 2006; 12: 451-61.
3. Kempson RL, Rouse RV. Juvenile fibroadenoma of breast. Stanford School of Medicine. Available from URL: [http://](http://surgpathcriteria.stanford.edu/breast/juvfibroadenoma/)

surgpathcriteria.stanford.edu/breast/juvfibroadenoma/. Accessed on 8th July 2016

4. Rattan K, Kumar S, Dhull AK, Kaushal V, Kaur P. Giant Fibroadenoma Mimicking Phyllodes Tumor in a young female. A cytological dilemma. The Internet Journal of Third World Medicine 2008; 6: 2.
5. Bauer BS, Jones KM, Talbot CW. Mammary mass in the adolescent female. Surg Gynecol Obstet. 1987; 165:63-5.
6. Issam M. Giant fibroadenoma. Case report and review of the literature. Basrah J Surg. 2006; 12: 1-4.
7. Muttarak M, Chaiwaun B. Imaging of giant breast masses with pathological correlation. Singapore Med J. 2004; 45:132-9.
8. Chang DS, Mc Grath MH. Management of benign tumors of the adolescent breast. Plast Reconstr Surg. 2007; 120 :13-16.

From: *Department of Pathology, **Department of Pediatrics, ***Department of Microbiology Uttar Pradesh University of Medical Sciences, Saifai, Etawah, Uttar Pradesh, India.

Address for Correspondence:
Seema Dayal, Associate Professor (Pathology), UPUMS Saifai, Etawah, Uttar Pradesh.



Email : seemadayal5@gmail.com

DOI : [10.7199/ped.oncall.2017.1](https://doi.org/10.7199/ped.oncall.2017.1)
