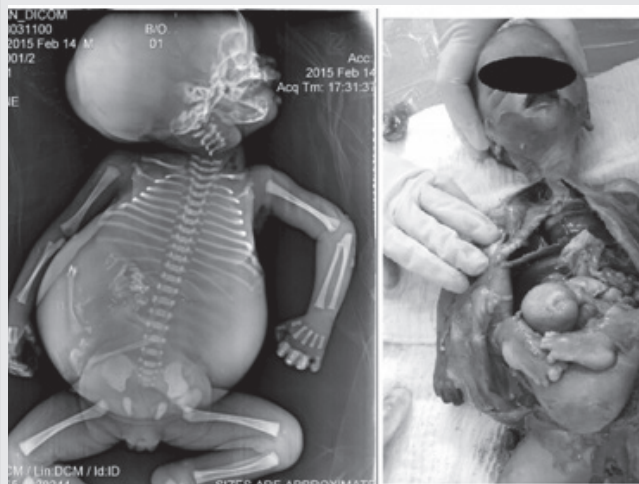


## SPOT DIAGNOSIS (IMAGE GALLERY)



### **STILL BORN WITH BONY MASS IN ABDOMEN**

**Kumaravel KS, Balaji J, Rameshbabu B, Punitha P, Gandhi G**  
*Government Dharmapuri Medical College Hospital, Dharmapuri, Tamil Nadu, India.*

**Address for Correspondence:** Dr KS Kumaravel, Department of Pediatrics, Govt. Dharmapuri Medical College, Dharmapuri, Tamilnadu, India. Email: kumaravvelks@rediffmail.com.

A 23 year old primi unbooked mother was referred to our hospital in late stage of labor and delivered a still-born female child. The examination of still born baby revealed a distended abdomen with bony hard elements on palpation. X-Ray of the still born baby revealed a mass in the abdomen with few long bones and a vertebral column (Fig 1). At autopsy, the mass was well enclosed by a sac and weighed 210 grams.

The mass contained well differentiated structures like lower limbs with toes and vertebral column (Fig 2). The mass derived blood supply from the abdominal aorta. The head and brain were rudimentary. Histopathologically the mass consisted of skin, fat, skeletal muscles and intestines. Lymph node, nerve tissue, and peripheral nerves, bones with marrow and vertebral column with cartilage were also present.

### **What is the diagnosis?**

Fetus in fetu (FIF) is a rare developmental abnormality (incidence of 1 in 5,00,000 live births) in which a mass of tissue resembling a fetus forms inside the body. (1) The FIF complex is characteristically composed of a fibrous membrane (equivalent to the chorioamniotic complex) that contains some fluids (equivalent to the amniotic fluid) and a fetus suspended by a cord or pedicle. (2) There are two main theories about the development of fetus in fetu. (3) Teratoma Theory proposes fetus in fetu as a highly differentiated form of mature teratoma and a Parasitic Twin Theory proposes Fetus in fetu as a parasitic twin fetus growing within its host twin. The parasitic twin is usually anencephalic and lacks some internal organs, and as such is almost always unable to survive on its own. Most FIF are located retroperitoneally, while other rare reported sites include the cerebral ventricles, liver, pelvis, scrotum, and mediastinum. (4) FIF is a benign condition, but the mass may compress the surrounding organs and tissue. Therefore symptoms of FIF are primarily due to its mass effect. Although the prognosis for FIF is more favorable than for cystic teratoma, the presence of immature elements nevertheless indicates the need for close clinical, radiological and serological (AFP) follow-up.

### **References:**

1. Spencer R. Parasitic conjoined twins: external, internal (fetuses in fetu and teratomas), and detached (acardiacs). *Clin Anat* 2001; 14(6):428-444.
2. Aoki K, Matsumoto Y, Hamazaki M, Sano M, Fukumoto K, Fukaya T, et al. MRI reveals fetus in fetu in the mediastinum. *Pediatr Radiol* 2004; 34(12):1017-1019.
3. Basu A, Jagdish S, Iyengar KR, Basu D. Fetus in fetu or differentiated teratomas? *Indian J Pathol Microbiol.* 2006; 49 (4): 563-5.
4. Hoeffel CC, Nguyen KQ, Phan HT, Truong NH, Nguyen TS, Tran TT, Fornes P. Fetus in fetu: a case report and literature review. *Pediatrics* 2000; 105(6):1335-1344



**E-published:** July-September2015 **DOI No. :** 10.7199/ped.oncall.2016.12