

## TEACHING FILE

### GRAND ROUNDS

Ira Shah

#### MULTIPLE ULCERS IN THE TERMINAL ILEUM

**Clinical Problem:** A 16 years old boy presented with abdominal pain and intermittent low grade fever for 3-4 months. An ultrasound (USG) abdomen showed multiple lymphnodes with bowel wall thickening of ascending colon, caecum, terminal ileum and appendix. There were no altered bowel habits on history. CT abdomen showed circumferential mural thickening involving distal ileum, caecum, proximal ascending colon with mesenteric non-necrotic lymphnodes (2.1 x 1.3 cm largest node). Ileocolonoscopy showed ulcers in terminal ileum with granulation on gross appearance. Histopathological examination revealed non-specific inflammatory ulcers with no caseous necrosis or tuberculosis (TB). He was advised intestinal resection of the diseased segment by the treating surgeon and so he presented to us for a second opinion. He had already been started on antituberculous therapy (ATT) for past 20 days. On presentation to us, his weight was 39.8 kg. He had pain and tenderness in right iliac fossa. Other systems were normal. Mantoux test was negative. Hemogram and ESR were normal. He had not been exposed to non-steroidal anti-inflammatory drugs (NSAIDs).

#### What is the cause of ulcers in the small intestine? Is it really TB?

**Expert Opinion:** Unlike other parts of the gastrointestinal tract, neoplasms are rare in the small intestine. (1) Non-specific small intestinal ulcers are usually caused by thiazides, potassium tablets or NSAIDs. (2) Cryptogenic multifocal ulcerous stenosing enteritis (CMUSE) is characterized by non-specific stenosis and superficial ulcers. (3) It is characterized by unexplained small intestinal strictures found in adolescents and middle aged subjects, superficial ulceration of the mucosa and submucosa, chronic or relapsing clinical course even after surgery, no biological signs of systemic inflammatory reaction, along with beneficial effect of steroids. (3) CMUSE is different from chronic non-specific ulcer of small intestine (CNSU). (4) CNSU is characterized by persistent anemia for more than 1 year, absence of clinical evidence suggestive of mycobacterial infection, absence of clinical evidence suggestive of Crohn's disease, and lack of any dermatologic, ophthalmologic or genital symptom suggestive of Behcet's disease with presence of non-specific intestinal ulcers. (1) Our patient also had no clinical evidence of TB or Crohn's disease nor features suggestive of Behcet disease though he had no anemia. He also had no strictures. Thus, he did not fit classically into CMUSE or CNSU but was diagnosed to have non-specific ulcers of small intestine. The abdominal lymphnodes were also non-necrotic, suggestive of non-specific inflammation. He was started on steroids and ATT was stopped. After a month, his weight had increased to 41.7 kg, USG abdomen showed same amount of bowel thickening but nodes had regressed in size to 0.9 x 0.7 cm. His pain had also decreased.

**Funding :** None

**Conflict of Interest:** None

#### References

1. Matsumoto T, Iida M Matsui T, Yao T, Watanabe H, Yao T

et al. Non-specific multiple ulcers of the small intestine unrelated to non-steroidal anti-inflammatory drugs. *J Clin Pathol* 2004;57:1145-1150

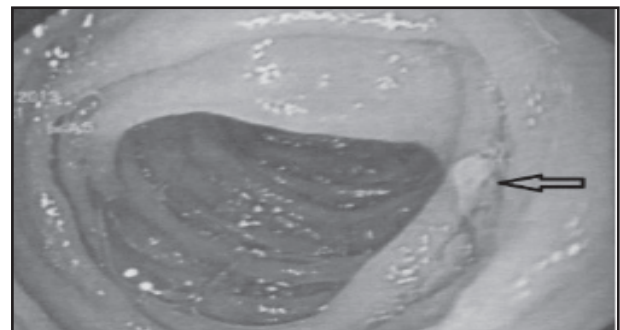
2. Morris A. Nonsteroidal anti-inflammatory drug enteropathy. *Gastrointest Endosc Clin N Am*1999;9:125-33.
3. Perlemuter G, Guillevin L, Legman P, et al. Cryptogenic multifocal ulcerous stenosing enteritis. An atypical type of vasculitis or a disease mimicking vasculitis? *Gut* 2001;48:333-8.
4. Chen Y, Ma W-Q, Chen J-M, Cai J-T. Multiple chronic non-specific ulcer of small intestine characterized by anemia and hypoalbuminemia. *World J Gastroenterol.* 2010;16:782-784.



**DOI No.:** 10.7199/ped.oncall.2017.13

#### DUODENAL AND JEJUNAL POLYPS IN EXTRA-HEPATIC PORTAL HYPERTENSION

**Clinical Problem:** A 7 years old boy suffering from extrahepatic portal hypertension had an episode of malena. An upper GI endoscopy was done. There was presence of Grade 1-2 esophageal varices without any bleeding stigmata. Stomach showed changes of portal gastropathy. There were multiple polyps in the duodenum and jejunum. One of the jejunal polyp was actively bleeding which was controlled by saline-adrenaline injection and bipolar heater probe coagulation. A duodenal polyp was resected and sent for histopathological evaluation.



#### What could be the cause of polyps in this child?

**Expert Opinion:** Histopathological evaluation of the polyp showed numerous thick-walled capillaries in its subepithelial portion, and a few vascular ectasias suggestive of portal hypertensive duodenopathy. The most common manifestations of portal hypertension are esophageal and gastric varices. Gastric mucosal changes such as presence of mosaic pattern, cherry red spots and scarlatina rash on endoscopy are called as portal hypertensive gastropathy which are also not uncommon. (1) Duodenum can also be involved and apart from duodenal varices, there may be presence of erythema, scattered petechiae, friable mucosa, erosion, ulcer and edema. (2) This is known as portal duodenopathy. On histopathology, they may present as subepithelial edema and increase of diameter and wall thickness of the capillaries. (3) Polyp can also occur due to portal hypertension duodenopathy which on histology may show presence of multiple thick walled capillaries (1) as was seen in our patient. It is postulated that multiple polyps can occur due

to angiogenesis (neovascularization) due to high portal pressure (4). Thus not all bleeding in portal hypertension is due to varices but can also be due to portal hypertensive polyps.

**References**

1. Zeitoun J-D, Chryssostalis A, Terris B, Prat F, Gaudric M, Chaussade S. Portal hypertensive duodenal polyp: A case report. *World J Gastroenterol.* 2007;13:1451-1452.
2. Misra V, Misra SP, Dwivedi M, Gupta SC. Histomorphometric study of portal hypertensive enteropathy. *Am J Clin Pathol.* 1997; 108:652-7.
3. Devadason D, Murphy MS, Brown R, Wilson D, McKiernan PJ. Duodenal capillary hemangiomas: a novel manifestation of extra hepatic portal hypertension? *J Pediatr Gastroenterol Nutr.* 2007;45:114-6.
4. Pillai SB, Ram Ganesh VR, Mohanakrishnan A, Nirmala V. Portal duodenopathy presenting as polyposis. *Indian J Pathol Microbiol.* 2010;53:558-9.



**Funding :** None

**Conflict of Interest:** None

**DOI No.:** 10.7199/ped.oncall.2017.11

**CHRONIC DIARRHEA WITH FEVER**

A 1 years old boy born of non-consanguineous marriage presented with recurrent watery, foul smelling diarrhea and fever for 2 months. He was treated with antibiotics, steroids and lactose free milk. His birth was normal and he was immunized till date. He was on exclusive breast feeds till 10 months of age and subsequently was started on weaning food. On examination, he had BCG Scar. He was malnourished (weight = 6.5 kg, < 5th centile) and had perianal excoriation. Systemic examination was normal. Investigations showed normal hemogram with normal liver function and renal function tests. His serum albumin was 4.6 mg/dl and venous blood gases were normal. Stool showed presence of mucus with fat globules. Stool for trypsin was positive. Sweat chlorides were normal. He was treated with oral antibiotics and metronidazole to which diarrhea responded. Serum immunoglobulins showed IgM 2.29 mg/dl (Normal = 41-173), IgG = 667 mg/dl (Normal = 172-1069), IgA = 70.97 mg/dl (Normal = 11 to 106).

**What is the diagnosis? How to treat this patient?**

Selective IgM deficiency. It is rare with an incidence of less than 0.03 percent in the general population and 1 percent in hospitalized patients. (1) It was previously known as type V dysgammaglobulinemia. (2) It has been described as a consequence of immunosuppression but primary antibody deficiency may be inherited as autosomal recessive partly influenced by X-chromosomal products. (3) Patients have serum IgM levels < 20 mg/dL to undetectable levels with normal levels of other immunoglobulins. (4) Infants with IgM deficiency tend to develop overwhelming and life-threatening infections with both encapsulated bacteria e.g., pneumococci, H. influenzae, meningococcal, pseudomonas and other gram negative bacteria. (5) Older children may have atopic dermatitis, autoimmune diseases or malignancy. (6) Patients with selective IgM deficiency are susceptible to chronic diarrhea and respiratory infections. (7) Our patient

had repeated diarrhea. Growth is stunted and children are malnourished secondary to recurrent infection as was seen in our patient. The cause of selective IgM deficiency is unknown. It is hypothesized that selective IgM deficiency results from either insufficient T helper cells or increased T suppressor cell function that interferes with B cell differentiation into IgM. IgM committed number of B cells and cell mediated immunity is intact. (8) Some patients are capable of normal antibody response in other immunoglobulin classes following specific immunization, whereas others respond poorly. (9) Insufficient data is available to determine the best treatment in these patients. Antibiotics should be started for all patients with infection and prophylaxis with antibiotics should be continued. (5) Since commercially available intravenous immunoglobulin (IVIg) has only traces of IgM, it may not be of much use except in patients who are unable to mount adequate antibody titers to specific antigens such as tetanus or pneumococcal vaccine. Prompt treatment of infections helps to decrease mortality and morbidity, however in patients with life-threatening infections, prognosis is poor.

**References**

1. Inoue T, Okumara Y, Shirahama M et al. Selective partial IgM deficiency: Functional assessment. *Clin Immunol* 1986; 6(2):130-135.
2. Ross IN, Thompson RA. Severe selective IgM deficiency. *Journ Clin Pathol* 1976; 29:773-777.
3. Hayward A. Immunodeficiency. In : Lachmann PJ, Peters DK edn. *Clinical Aspects of Immunology*, Vol 2, 4th Edn. Oxford : Blackwell Scientific Publications; 1982:1672-1673.
4. Cleveland M. Antibody deficiency syndromes. *Pediatr Clin North AM* 2000;47:1240.
5. Ammann AJ, Stiehm R. Antibody (B cell) Immunodeficiency Disorders. In : Daniel P Stites, Abba Terr, Trisham G Praslow eds. *Medical Immunology*. London. Prentice Hall International Inc; 1997:342.
6. Ochs HD, Winkelstein J. Disorder of B-cell system In: Steihl ER eds. *Immunologic Disorders in Infants and Children*. 4th edn. Philadelphia. WB Saunders; 1996:296-338.
7. Rao B. Immunoglobulin M Deficiency. Available at website [www.emedicine.com](http://www.emedicine.com) Accessed on 18th November 2005.
8. De la Concha EG, Garcia - Rodriguez MC, Zabay JM. Functional assessment of T and B lymphocytes and antibody deficiency. *Clin Exp Immunol* 1982;49:670-676.
9. Zaka-ur-Rab Z, Gupta P. Pseudomonas septicemia in selective IgM Deficiency. *Indian Pediatr* 2005; 42:961-962.



**Funding :** None

**Conflict of Interest:** None

**DOI No. :** 10.7199/ped.oncall.2017.12

**From:** Medical Sciences Department, Pediatric Oncall, Mumbai, India.

**Address for Correspondence** Dr. Ira Shah, 1/B, Saguna, 271/B, St. Francis Road, Vile Parle (West), Mumbai 400056 India.