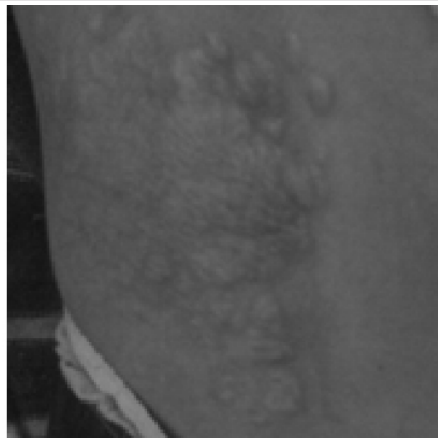


SPOT DIAGNOSIS (IMAGE GALLERY)



>>> *Ketan Kulkarni*
MD, PGIMER, Chandigarh

A 10 year old female child presented with polymorphic seizures and skin patch. She also had adenoma sebaceum. Neuroimaging demonstrated multiple subependymal nodules with candle dip appearance.

What is the diagnosis? What is the skin lesion?

The diagnosis was clearly tuberous sclerosis. Skin lesion is Shagreen patch.

E-published: December 2008