

TEACHING FILES (GRAND ROUNDS)

HEMATEMESIS IN A CHILD WITH BETA THALASSEMIA

Himali Meshram.

Pediatric Gastroenterology, Happy Gut Child Superspecialty Clinic and Pediatric Gastroenterology unit, Nagpur, Maharashtra, India.

ARTICLE HISTORY

Received 26 November 2022

Accepted 17 November 2023

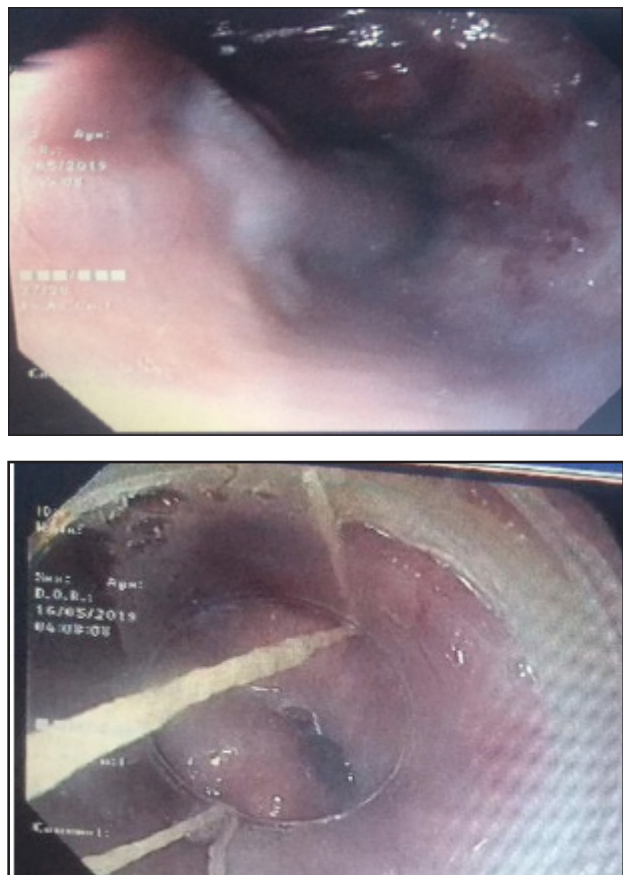
KEYWORDS

hepatomegaly, thalassemia, hematemesis, portal cavernoma.

Clinical Problem:

A 14 year old girl presented to us with hematemesis in April 2016. She was diagnosed to have heterozygous HBE thalassemia at the age of 2 years. Since then she was on regular blood transfusions. Her birth and development history is normal. On examination, weight was 32 kg (<3rd percentile), height was 147.5 cm (<3rd percentile). She had haemolytic faces. Abdominal examination revealed firm splenohepatomegaly. Other systems were normal. Complete blood count showed hemoglobin of 4.6 g/dl, total leukocyte count of 5,500 cells/mm³ (polymorphs 55%, lymphocytes 40%), platelet count of 75,000 cells/mm³, total bilirubin- 0.9 mg/dl, direct bilirubin- 0.3 mg/dl, amino transferase -26 IU/L, alanine transferases- 28 IU/L, alkaline phosphatase- 56 IU/L, total protein- 5.2 gm/dl, albumin- 3 gm/dl, prothrombin time -12 seconds and INR- 1.3. HIV, Hepatitis C Elisa and HBsAg were negative. Ultrasound (USG) abdomen and doppler revealed portal cavernoma. Upper gastroesophageal endoscopy showed grade 3 varices which required endoscopic variceal ligation (EVL). She was also started on nonselective beta blocker (propranolol). As she had requirement of repeated blood transfusions and presence of portal cavernoma and hypersplenism; she underwent splenectomy with proximal lienorenal shunt in June 2016. She received low molecular heparin for 10 months post splenectomy. Pancytopenia improved hemoglobin of 10.3 g/dl, total leukocyte count of 10,000 cells/mm³ (polymorphs 44%, lymphocytes 49%), platelet count of 2, 86,000 cells/mm³). After 3 years of surgery, she again had hematemesis. Gastroduodenoscopy (Figure 1) showed grade 3 varices requiring EVL. USG abdomen and doppler showed portal cavernoma, with non-visualisation of lienorenal shunt. She is on regular follow up.

Figure 1. Gastroduodenoscopy showing grade 3 varices requiring banding.



What is the cause of portal cavernoma in a thalassaemic child?

Discussion:

Thromboembolic events have been frequently reported in β -thalassemic patients. The incidence of these events has been reported to be from 1.1-5.3% in thalassemia major patients.¹ The hypercoagulable state in thalassemia increases the risk of venous thromboembolic events in deep veins of limbs, portal vein, cerebral veins and central venous lines.² There are various factors which contribute to hypercoagulable state in thalassemia including platelet abnormalities, defect in red cell membrane, oxidant injury, defects in

Address for Correspondance: Himali Meshram, Ground floor, Amarjyoti palace, Wardha road, Lokmat square, Nagpur-440012, India.

Email: gshimali@yahoo.com

©2024 Pediatric Oncall

coagulation inhibitors.² Splenectomy and transfusion naveity are important risk factors for thrombotic events, especially in patients with thalassemia intermedia.³ Portal vein thrombosis has rarely been reported in patients with thalassemia major.^{1,4,5} Various clinical studies have shown that splenectomised patients have a higher incidence of thromboembolic events than non-splenectomized patients.⁵ Our patient was a female with a huge splenomegaly but developed portal cavernoma before splenectomy. Thromboembolic events in thalassemia usually manifest in second or third decade of life. Our patient developed symptoms at a very young age. They usually present with symptoms of increased portal venous pressure such as gastrointestinal bleeding and abdominal pain.⁴ Similarly our patient presented with hematemesis. To diagnose this condition, many methods such as ultrasound and color doppler, CT scan, angiography, are useful.⁴ We diagnosed our patient to have portal cavernoma with ultrasound and doppler of abdomen. Transfusion therapy may be beneficial to prevent the occurrence of thrombotic events.³ Early diagnosis and treatment with thrombolytic agents in acute portal vein thrombosis can be helpful. Splenectomy in patients with β -Thallemia should be performed only when it is strongly indicated. If splenectomy has to be performed anticoagulant prophylaxis should be instituted.⁴ Our patient was on regular blood transfusions and had features of hypersplenism; and hence underwent splenectomy with proximal lienorenal shunt. She received low molecular weight heparin post splenectomy for 10 months, however her latest Doppler shows non-

visualisation of the shunt. Since splenectomy is a major factor causing thromboembolic events in thalassemia patients, reassessment of the procedure and risk benefit-evaluation is necessary.³ Similarly, our patient continued to have hematemesis post splenectomy and whether that is an additional contributing factor to the persistent portal hypertension needs to be assessed, though there is no portal thrombosis noted.

Compliance with ethical standards**Funding:** None**Conflict of Interest:** None**References:**

1. Sadeghi S, Mohammadi Ashiani A, Khalili M. Portal Vein Thrombosis Following Splenectomy in β -thalassemia Major. *IJBC* 2016; 8(3): 90-91.
2. Thromboembolic complications in b-thalassemia: beyond the horizon. Panigrahi I, Agarwal S. *Thrombosis Research* (2007); 120:783-789.
3. Thalassemia and Venous Thromboembolism. Succar J, Musallam KM, Taher AT. *Mediterr J Hematol Infect Dis* 2011; 3; Open Journal System.
4. Hassan MN, Tahereb GM, Ahmad T, Asghar DA, Reza ED, Ali B, Mohsen MN. Correlation of splenectomy with portal vein thrombosis in beta-thalassemia major. *J Pak Med Assoc.* 2011 Aug;61(8):760-2. PMID: 22355997.
5. Taher AT, Musallam KM, Karimi M, El-Beshlawy A, Belhoul K, Daar S, Saned M, Cesaretti C, Cappellini MD. Splenectomy and thrombosis: the case of thalassemia intermedia. *J Thromb Haemost* 2010; 8: 2152-8.