

CASE REPORT

NASOPHARYNGEAL CARCINOMA PRESENTING AS FACIAL NERVE PARALYSIS

Ajay Garg, Raman Wadhwa, S P Gulati, Jagjit Singh*, Rohit Goyal**

Abstract

Nasopharyngeal carcinoma (NPC) is well known for its marked invasive & metastatic potential and manifests in a variety of forms. Cranial nerve(s) involvement is seen in 20% cases of NPC. But clinically evident facial nerve paresis/palsy is a rare presentation. Authors describe a case of NPC in an 11 years female child who presented with right sided cervical mass with facial nerve paresis.

Key Words: Nasopharyngeal carcinoma (NPC), Facial nerve paresis.

Introduction

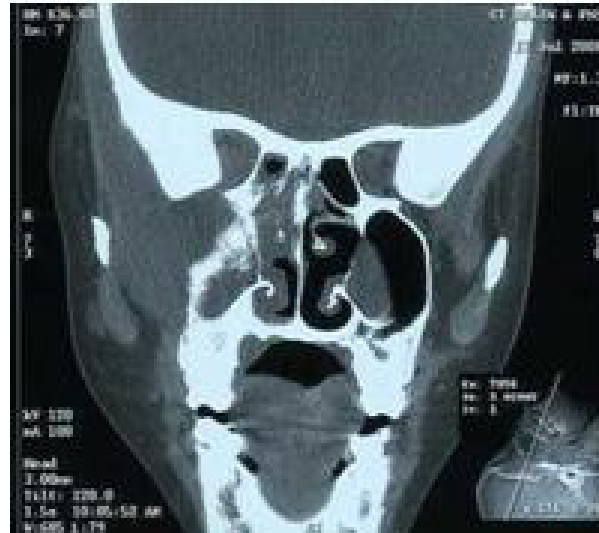Nasopharyngeal carcinoma (NPC) pragmatically refers to a specific category of carcinoma, arising from nasopharyngeal epithelium is found with highest frequency in southern China in the central Guangdong province and Guangxi Autonomous region. NPC is relatively rare neoplasm in Caucasian populations including Indians (age standardized rate is less than 1/100000). Characteristic bimodal pattern of age distribution is seen, with a small peak in late childhood and second peak in 50-60 years of age and male to female ratio being 2:3 (1). Although etiology of NPC remains obscure, but a susceptible genetic constitution clearly plays a part and some environmental co-factors are equally important. (1) The WHO (World Health Organization) has categorized NPC as: TYPE- I Squamous cell carcinoma, TYPE- II Non-keratinizing carcinoma (Transitional cell carcinoma), TYPE-III Undifferentiated carcinoma (Lymphoepithelioma, anaplastic, clear cell and spindle cell variants) (2). Facial nerve involvement by NPC is rarely reported in the literature making present case an interesting one.

Case Report

An 11 years old female child presented with 8 months history of right sided cervical mass gradually increasing in size with occasional history of nasal obstruction. There was no history of epistaxis, fever, weight loss or any other audiological symptoms. She had been taking anti-tubercular drugs for the last 6 months on prescription of a general practitioner, who diagnosed her to be a case of tuberculous lymphadenitis. She had no significant relief which prompted her parents to consult an otorhinolaryngologist. Examination revealed a single, nontender, hard, cervical mass of size 3 x 4cm in size, fixed to the underlying structures in right jugulodigastric area. Anterior rhinoscopy revealed totally obliterated bilateral choanae. Slight weakness of right orbicularis oculii muscle was also noticed when she was asked to close the eye along with deviation of angle of mouth to left suggesting right facial nerve involvement. Her further neurological, audiological, ophthalmological and laryngeal examination was normal. Fine needle aspiration cytology of the cervical mass showed features of undifferentiated carcinoma. Subsequently Non Contrast Computed tomography

scan of nose & nasopharynx demonstrated mass filling the nasopharynx (figure 1). Patient underwent nasoendoscopic biopsy, which confirmed the diagnosis of undifferentiated nasopharyngeal carcinoma (Type III). Patient was referred for radiotherapy. External beam radiation in the dosage of 66GY in 33 divided fractions were delivered to the nasopharynx with concurrent chemoradiation (carboplatin, 5 -FU).

Figure 1- Coronal CT image showing bone erosion & extension of tumor to infratemporal fossa.



Discussion

Malignant lesions of the nasopharynx are perhaps the most commonly misdiagnosed, most poorly understood, and most pessimistically regarded of all tumors of the upper respiratory tract. (3) Early diagnosis of NPC is usually difficult attributed to its insidious onset and nonspecific features in initial stages. The symptomatology of NPC varies depending on the stage of the disease at the time of presentation. Commonest presenting symptom includes painless cervical lymphadenopathy (75%), epistaxis and nasorespiratory symptoms (30%), audiological symptoms (tinnitus, otalgia, deafness) (20%), neurological symptoms (headache, cranial nerve palsies, and Horner's syndrome) (20%), and metastases which can be locoregional (paranasal sinus, parapharyngeal space, infratemporal fossa, orbit, parotid and cervical lymphadenopathy) or distant (bone, lung and liver). (1)

One fifth of patients have symptoms of cranial nerve involvement at the time of diagnosis. Proximity of fossa of rosenmuller to foramen lacerum and middle cranial fossa floor allows direct tumor extension into the cranium and involvement of the adjacent nerves. Trigeminal nerve involvement is found most frequently followed by abducent nerve producing facial pain & parasthesia and diplopia respectively. (4) Facial nerve palsy caused by NPC is uncommon; its incidence is less

than 1%. Among all cases of facial nerve paralysis, 5% have been reported to be involved by tumors. After emerging from the brainstem, the facial nerve enters the cerebellopontine angle (CPA), the temporal bone (internal auditory canal, middle ear and mastoid) and the parotid before branching out to supply the facial muscles. Tumor involvement any where along the course can cause facial palsy.(5) Swaski et al in a series of patients of NPC studied that 4.6% cases had clinically evident facial nerve palsy. (6) Facial nerve involvement at CPA is by metastasis (via hematogenous, CSF, or leptomeningeal), while in middle ear it is either direct spread (via Eustachian tube or direct invasion from parapharyngeal space) or by metastasis. Facial nerve involvement at parotid attributes to lymphatic dissemination of tumor to the parotid lymph nodes via retropharyngeal group of lymph nodes as seen in our case. (5) Various syndromes involving multiple cranial nerves in association of NPC have also been described in the literature. Gradenigo's syndrome is defined by triad of sixth nerve palsy, pain and parasthesia in the distribution of fifth nerve and otitis media. Involvement of cranial nerves III & IV indicates more advanced disease along cavernous sinus called as cavernous sinus syndrome. Rarely, NPC may affect IX, X, & XI cranial nerves in parapharyngeal space, causing jugular foramen syndrome.(4) NPC involving nine cranial nerves in a patient has also been reported in the literature.(7)

NPC is extremely radiosensitive tumor and the mainstay of treatment for primary local and regional disease is invariably radiotherapy, almost irrespective of the stage of the disease. Additional chemotherapy is advocated in patients with advanced disease to improve overall results. Local & regional failures are controlled by surgical salvage. (1)

Conclusion

Early diagnosis of NPC is difficult attributes to the hidden location of the disease & wide spectrum of nonspecific and sparse symptoms. So an otolaryngologist should be well acquainted with this situation; if a

patient presents with isolated or multiple cranial nerve palsies.

References

1. Woo JKS, Hasselt CAV. Nasopharyngeal carcinoma. In: Glesson M ed. Scott's-Brown Otorhinolaryngology, Head and surgery, 7th ed., Hodder Arnold, London, 2008 Vol.2 : 2448-2474.
2. Shanmugaratnam K, Jobin LH. Histological typing of upper respiratory tract tumors, No. 19. Geneva, World Health Organisation, 1978: 32-33.
3. Scanlon PW, Devine KD, Woolner LB. Malignant lesions of the nasopharynx. *Ann Otol Rhinol Laryngol.* 1958; 67: 1005-1021
4. Peters LG, Rischin D, Corry J, Harari PM. Cancer of the nasopharynx. In: Harrison LB, Sessions RB, Hong WK eds. *Head & Neck cancer- a multidisciplinary approach*, 2nd ed. Lippincott Williams, Williams & Wilkins, Philadelphia. 2004: 529-559.
5. Wong-Kein Low "Facial palsy from metastatic nasopharyngeal carcinoma at various sites: Three reports _ Original Article - Brief Article". *Ear, Nose & Throat Journal.* FindArticles.com. 01 Sep.2008. http://findarticles.com/p/articles/mi_mOBUM/is_2_81/ai_83516035
6. Swaski S, Sugano H, Hirayama T. Analytical aspects of symptoms of nasopharyngeal malignancies. In: de-The G, Ito Y, eds. *Nasopharyngeal carcinoma: etiology and control.* IARC Sci Pub 1978; 20: 147-163.
7. Kaushik ML, Pandey D, Sood BR, Thakur S. Nasopharyngeal carcinoma presenting as multiple cranial involvement. *JIACM* 2003; 4: 61-63.

From: Departments of Otorhinolaryngology & Pediatrics*, PGIMS, Rohtak & Deen Dayal Upadachay Hospital, New Delhi**

Address for Correspondence: Dr. Jagjit Singh, H.No.44, Street No.11, Jawahar Nagar, Hisar, Haryana-125001, India. E-mail: drjagjitsingh@hotmail.com

E-published: April 2010. **Art#**21

CASE REPORT

A CONGENITAL LIVER MASS

Mark R. Corkins¹, Kimberly E Applegate², Karen West³

Abstract

A prenatal ultrasound at 28 weeks gestation demonstrated a heterogeneous mass in the inferior aspect of the liver. The infant was delivered at full term and had no clinical findings other than the palpable liver mass. All laboratory studies were normal. At a month of age the patient underwent resection of the mass which represented an in utero ovarian torsion that had adhered to the liver.

Keywords: congenital liver mass

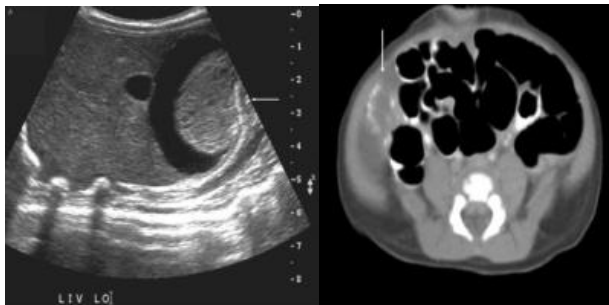
Introduction

Prenatal ultrasound has become a standard practice in obstetrical care. The technology of these devices has improved and therefore the ability of the ultrasound to detect a variety of anomalies before birth. The prenatal ultrasound can help guide preparation for anomalies that may require medical intervention but can also lead to parental anxiety when the findings are ambiguous. Finding a liver mass on a prenatal ultrasound raises a variety of diagnostic possibilities. There is a mixture of benign and malignant lesions that have a range of prognostic outcomes.

Case Report

The patient was a day old female referred for evaluation of a liver mass. This mass was noted on a prenatal ultrasound at 28 weeks gestation. This mass was a 3.2 cm diameter cystic mass in the right side of the abdomen at the lower edge of the liver. After delivery, an ultrasound demonstrated a 4.4 x 3.4 x 4.8 cm multi-cystic mass at the inferior aspect of the right lobe of the liver (A). Laboratory studies showed normal clotting studies, liver functions and blood counts. Alpha fetal protein level was not excessive for age. The patient's examination was normal except for the palpable mass in the right upper quadrant of the abdomen. A subsequent CT scan showed similar findings and peripheral calcification in the lesion's wall (B). The patient fed well with excellent growth and at one month of age the patient underwent surgical resection. The liver lesion actually represented a case of ovarian torsion. In the operating room the patient was found to have an old torsion of the right ovary apparently due to an ovarian cyst. The torsed ovary was affixed to the lower aspect of the liver. The pathology confirmed the tissue to be ovarian.

Figure A: Ultrasound showing multi-cystic mass at inferior aspect of liver. Figure B: CT scan showing peripheral calcification



Discussion

The University of San Francisco Fetal Treatment center reviewed ten years of data for 1316 patients referred for congenital defects found on imaging (1). Sixteen had fetal tumors and only three were in the liver (1). The largest perinatal necropsy series covering 30 years and 17,417 infants found 46 tumors, including one hepatic adenoma and two liver hemangiomas (2). The most frequent liver tumors found in newborns are hepatoblastoma, hemangioendothelioma and mesenchymal hamartoma (3). Applegate and her colleagues reported a cystic liver lesion found during the third trimester of pregnancy on ultrasound that proved to be a hepatic adenoma (3). This lesion was in the anterior superior parenchyma of the right liver lobe. The vascular lesions of a congenital hemangioendothelioma has been described on prenatal ultrasound at 19 weeks gestation (4) and a giant hemangiomas has been described at 29 weeks gestation (5) both were associated with evidence of vascular shunting. A prenatal ultrasound of a hepatoblastoma has been reported at 36 weeks gestation with the description

of a solid polylobular tumor in the right liver lobe with areas of hemorrhage, necrosis and small calcifications (6). In 2003, Kamata and his colleagues had tallied a total of 13 reported cases of prenatally detected mesenchymal hamartoma (7). These usually presented as a large, rapidly growing asymptomatic mass which in the majority of cases were cystic (7). These lesions may appear exophytic and it may be difficult to determine the organ of origin on pre-operative imaging.

The clue that this was an "extra-hepatic" mass was the finding that the mass appeared oval-shaped and contained many small cysts that are typical of ovarian follicles. The mass was cystic, free of blood flow on ultrasound, and contained a peripheral calcification that may be seen with infarcted ovarian torsion. The size of the lesion varied very little from the time it was first found at 28 weeks gestation until delivery at full term. The completely normal laboratory studies also suggested that this might not be hepatic in origin. It is critical that investigation of neonatal cystic masses in girls include documentation of the normal ovaries in order to exclude this etiology in the differential diagnosis. Ovarian cysts in the newborn are commonly located in the abdomen due to the relatively small size of the pelvis and the long ovarian pedicle.

Financial disclosures: None

Conflict of interest: None

References

1. Sbragia L, Paek BW, Feldstein VA, Farrell JA, Harrison MR, Albanese CT, et al. Outcome of prenatally diagnosed solid fetal tumors. *J Pediatr Surg* 2001; 36: 1244-1247.
2. Werb P, Scurry J, Ostor A, Fortune D, Attwood H. Survey of congenital tumors in perinatal necropsies. *Pathology* 1992;24:247-253.
3. Applegate KE, Ghei M, Perez-Atayde AR. Prenatal detection of a solitary liver adenoma. *Pediatr Radiol* 1999;29:92-94.
4. Meirwitz NB, Guzman ER, Underberg-Davis SJ, Pellegrino JE, Vintzileos AM. Hepatic hemangioendothelioma: prenatal sonographic findings and evolution of the lesions. *J Clin Ultrasound* 2000;28(5):258-263.
5. Pott Bartsch E.M., Paek BW, Yoshizawa J, Goldstein RB, Ferrell LD, Coakley FV, et al. Giant fetal hepatic hemangioma. Case report and literature review. *Fetal Diagn Ther* 2003;18: 59-64.
6. Shih JC, Tsao PN, Huang SF, Yen BL, Lin JH, Lee CN, et al. Antenatal diagnosis of congenital hepatoblastoma in utero. *Ultrasound Obstet Gynecol* 2000;16: 94-97.
7. Kamata S, Nose K, Sawai T, Hasegawa T, Kuroda S, Sasaki T, et al. Fetal mesenchymal hamartoma of the liver: report of a case. *J Pediatr Surg* 2003;38:639-641.

From: ¹Division of Pediatric Gastroenterology & ³Department of Surgery/Section of Pediatric Surgery, Riley Hospital for Children/Indiana Univ., Indianapolis, IN, ²Department of Radiology, Emory University, Atlanta, GA

Address for Correspondence: Mark R Corkins, Riley Hospital for Children, 702 Barnhill Drive, ROC 4210, Indianapolis, IN 46202. USA. Email: mcorkins@iupui.edu

E-published: 2010. **Art#**27

CASE REPORT

ISOLATED DEMYELINATING OPTIC NEURITIS IN NEUROTUBERCULOSIS

Mitra Souvik, Samanta Moumita, Sarkar Mihir, Chatterjee Sukanta

Abstract

Isolated demyelinating optic neuritis is a rare presenting feature of neurotuberculosis in the pediatric population. Most of the optic neuritis cases that are reported in pediatric tuberculosis are usually associated with other focal neurodeficits or follow anti-tubercular therapy, especially ethambutol. Here we report a 9 year old boy presenting with fever, headache and rapid onset blindness with no focal neurodeficits. He was diagnosed with demyelinating optic neuritis with evidence of neurotuberculosis and was managed successfully with anti tubercular drug therapy and corticosteroids. Being an endemic country, neurotuberculosis should be considered as a potential cause of demyelinating optic neuritis in the pediatric population.

Key Words: isolated optic neuritis, neurotuberculosis, demyelination

Introduction

Neurotuberculosis is a very common but equally serious form of tuberculosis affecting the pediatric population of India. It accounts for upto 10% of all cases of pediatric tuberculosis in this country (1). Isolated optic nerve lesion with rapid onset blindness in a case of neurotuberculosis is rarely reported in the pediatric population.

Case Report

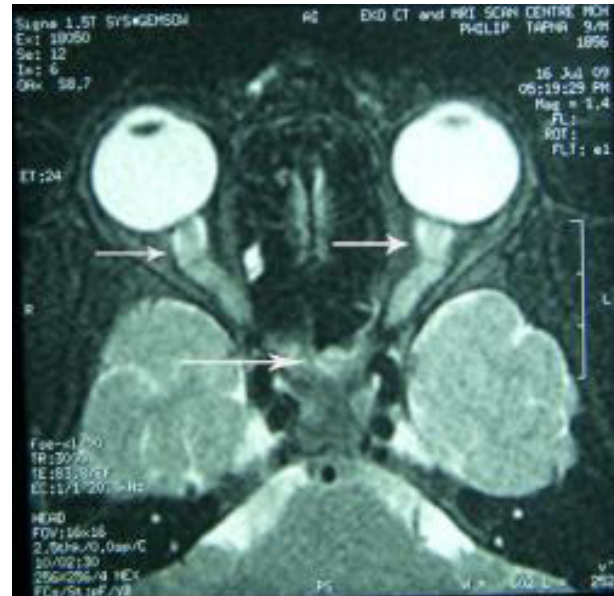A nine year old boy presented with a history of low grade fever for 14 days associated with intense headache and pain on moving the eyes followed by rapid onset blindness affecting both eyes. There was no associated convulsions, altered sensorium, neurodeficits, bladder or bowel dysfunction. There was also no history of head injury, drug intake or any similar complaints in the past. There was no similar history in any of the family members but the child had multiple positive history of contact with tuberculosis. Both his father and paternal grandfather had been on anti-tubercular drugs (ATD) in the past one and half years.

On examination the child was conscious and oriented. There were no focal neurodeficits. On ocular examination, perception of light (PL) was present but projection of rays (PR) was absent. Pupils were bilaterally dilated, sluggishly reacting and there was evidence of relative afferent pupillary defect. Field of vision and colour vision could not be tested due to poor visual acuity. Direct ophthalmoscopy revealed diffuse hyperemia and edema of the optic disc in both the eyes with a normal macula and retina, suggestive of bilateral papillitis. There was no evidence of any other cranial nerve involvement. Other systems were within normal limits. On anthropometric examination his height was 127cm and weight was 19kgs.

Baseline hematological investigations revealed anemia (Hemoglobin 9.5 gm %) with a moderately raised ESR (65mm in the first hour). Cerebrospinal fluid (CSF) analysis revealed a normal cell count (5

cells; all lymphocytes), normal sugar (67mg% with a corresponding blood sugar of 78 mg %) and raised protein (103 mg %). Mantoux test was positive (+10mm). Chest X Ray was normal. No acid-fast bacilli were found on Zeihl-Neilsen staining and microscopy of 3 consecutive gastric aspirates. CT scan brain was normal. MRI brain revealed bilaterally swollen optic nerves and diffuse high signal intensities in the region of the optic nerves and optic chiasma on T2 weighted images suggestive of optic neuritis. (Fig. 1) Visual Evoked Potential (VEP) showed bilateral demyelination of the optic nerves. CSF study for oligoclonal bands was negative. DNA Polymerase Chain Reaction (PCR) study for Mycobacterium tuberculosis antigen from the CSF was positive.

Fig 1. MRI brain showing bilaterally swollen optic nerves with high signal intensities in the region of the optic nerves and optic chiasma



Hence the patient was put on DOTS (Directly Observed Treatment, Short Course) therapy with a four drug anti-tubercular regime (Isoniazid, Rifampicin, Pyrazinamide, Streptomycin) on alternate days for the initial 2 months followed by Isoniazid and Rifampicin on alternate days for the next 4 months according Category 1 of the Revised National Tuberculosis Control Programme (RNTCP) guidelines. The patient was simultaneously put on a 3 day course of pulse Methylprednisolone (at 30mg/kg/day) followed by oral prednisolone (at 2mg/kg/day) in 3 divided doses for 6 weeks with slow tapering over the next 2 weeks.

Ocular examination at the end of the second week of therapy revealed a normal PL and PR, slightly dilated pupils with normal direct and consensual light reflex in both the eyes. Vision was 6/60 bilaterally without any apparent field defects or dyschromatopsia. The hyperemia and edema of the optic disc had also

resolved. At the end of 3 months the child had gained weight appreciably (22.5 kgs), vision was 6/12 in both eyes and CSF study was negative for *M. tuberculosis* by DNA PCR method. After 6 months of ATD, MRI brain revealed a normal study, visual acuity was 6/6 in both the eyes with a normal color vision and field of vision.

Discussion

Loss of vision is a well documented sequelae of neurotuberculosis. The tubercle bacilli may cause loss of vision by affecting the central nervous system (CNS) directly. This occurs in cases of involvement of the optic nerve and optic chiasma by tuberculomas, in miliary tuberculosis and optochiasmatic arachnoiditis (2,3). But the bacilli may also affect the CNS by producing a hypersensitivity reaction to the tuberculoprotein leading to "allergic tuberculous encephalopathy". This hypersensitivity reaction may induce perivascular demyelination of white matter and may present with optic neuritis (4). Similar cases have been reported in the adult population by Balal et al and Stechschulte et al where the presenting feature of tuberculosis was isolated optic neuritis which responded dramatically to ATD with corticosteroids (5,6). But little is known about similar presentations in the pediatric population.

Optic neuritis in pediatric population is mostly due to demyelinating diseases like acute demyelinating encephalomyelitis, multiple sclerosis and Devic's disease (neuromyelitis optica). Optic neuritis has been known to occur with the use of Ethambutol and hence was avoided in our patient (7). Therapy includes a pulse therapy of methylprednisolone for 3 days followed by oral prednisolone for 11 days (8). But in view of definitive evidence of neurotuberculosis in our case by positive DNA PCR study in CSF, prednisolone was continued for 8 weeks along with ATD with promising results.

Thus, in an endemic country like India, where tuberculosis presents with various forms of clinical manifestations, neurotuberculosis should always be ruled out in a child presenting with sudden onset of blindness.

Contributors: S Mitra and M Samanta were involved in the diagnosis and management of the case. S Mitra drafted the article with help of M Sarkar. S Chatterjee critically evaluated the manuscript.

Funding: None

Competing interests: None stated

References

1. Gulati S, Kalra V, Seth R, Seth V. Neurotuberculosis - Clinical manifestations, diagnosis and Management. In: Seth V, Kabra SK (eds). Essentials of Tuberculosis in Children. 3rd Edn. Jaypee. New Delhi. 2006; 157- 228
2. Kadioglu HH, Gundogdu C, Deniz O, Takci E, Tuzun Y, Aydin IH. Optochiasmatic tuberculoma--case report and review. Zentralbl Neurochir. 1996; 57: 30-36
3. Scott RM, Sonntag VK, Wilcox LM, Adelman LS, Rockel TH. Visual loss from optochiasmatic arachnoiditis after tuberculous meningitis. Case report. J Neurosurg. 1977; 46: 524-526
4. Dastur DK, Manghani DK, Udani PM. Pathology and pathogenetic mechanisms in neurotuberculosis. Radiol Clin North Am. 1995; 33: 733-752
5. Stechschulte SU, Kim RY, Cunningham ET Jr. Tuberculous neuroretinitis. J Neuroophthalmol. 1999; 19: 201-204
6. Balal M, Paydas S, Seyrek N, Karayaylali I. Loss of vision and renal function in a patient with miliary tuberculosis. Mt Sinai J Med. 2005; 72: 124-126
7. Filipovic T, Bujanic-Cuculic S, Boskovic I. Optic nerve damage caused by administration of ethambutol. Lijec Vjesn. 1997; 119: 273-274.
8. Kanski JJ. Neuro-ophthalmology. In: Kanski, JJ ed. Clinical Ophthalmology. A Systemic Approach. 3rd ed. Oxford, England: Butterworth-Heinemann Ltd. 1994: 601-603

From: Department of Pediatrics, Medical College, Kolkata, India

Address for Correspondence: Souvik Mitra, 618, Block "O", New Alipore, Kolkata - 700 053, West Bengal, India. Email: souvik4sphs@yahoo.com

E-published: June 2010. **Art#**32
