

## CASE REPORTS

# CONGENITAL TUBERCULOSIS WITH PARADOXICAL REACTION

Rishika Sakaria<sup>1</sup>, Ira Shah<sup>2</sup>.

<sup>1</sup>Seth G S Medical College, KEM Hospital, Mumbai, India, <sup>2</sup>Pediatric Infectious Diseases, Levioza Healthcare, Mumbai, India.

### ABSTRACT

Paradoxical reactions with congenital tuberculosis (TB) are rare. We hereby report a case of 5 month old premature infant with progressive pulmonary tuberculosis who developed paradoxical reaction in the form of increasing respiratory distress after 3 months of Anti-Tuberculosis Therapy (ATT). The condition responded favorably to a high dose course of steroids taken over a period of 2 months with the ATT remaining unaltered.

### ARTICLE HISTORY

Received 2 August 2022

Accepted 15 December 2022

### KEYWORDS

congenital tuberculosis,  
paradoxical reaction

### Introduction

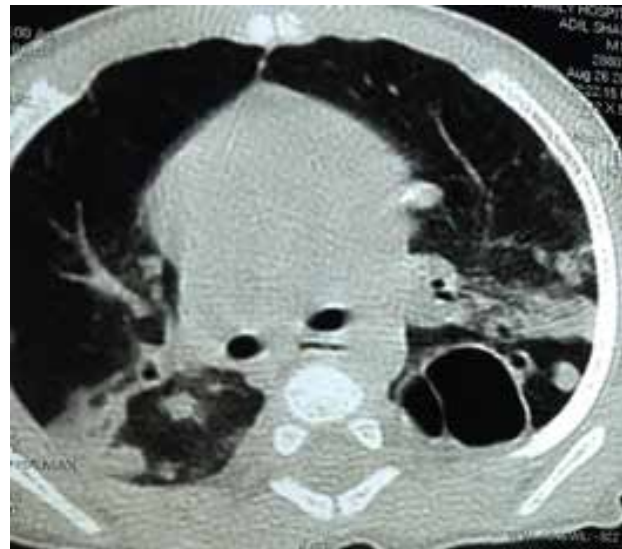A paradoxical reaction in tuberculosis (TB) has been defined as the clinical or radiological worsening of a pre-existing tuberculosis lesions or the development of new lesions during Anti-Tuberculosis Therapy (ATT).<sup>1</sup> Congenital TB is defined as infection of the fetus with tubercle bacilli in intra-uterine life or before complete passage through the birth canal.<sup>2</sup> Despite the high prevalence of genital TB in the world, congenital TB is a rare occurrence. It is thought to be acquired by hematogenous route or through amniotic fluid aspiration by the fetus. Very few cases of paradoxical reactions have been reported in congenital tuberculosis.<sup>1</sup> We hereby report a case of 5 month old premature infant with progressive pulmonary tuberculosis who developed paradoxical reaction and responded to steroids.

### Case Report

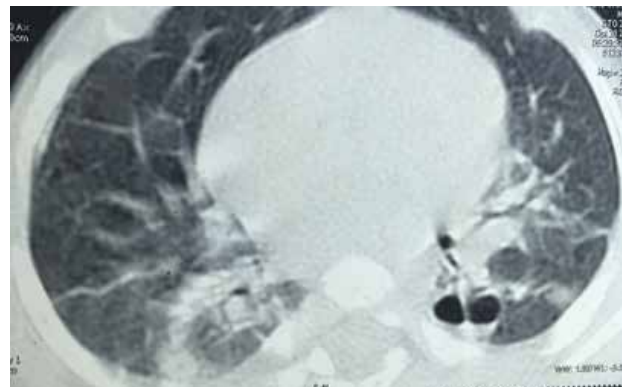
A 5-month-old boy presented with increasing breathlessness in October 2010. The boy was born preterm at 7.5 months of gestation with a birth weight of 1.7 kg. Mother had uterine TB diagnosed at the time of caesarean section and she was started on ATT consisting of isoniazid(H), rifampicin (R), pyrazinamide (Z) & ethambutol (E) at the time of birth of the child and the child was put on isoniazid prophylaxis. At 2 months of age, he was diagnosed as progressive pulmonary tuberculosis on basis of CT chest that showed fibrocystic lesions in left lower lobe with consolidation and air bronchogram in right upper lobe (figure 1). Gastric lavage for genexpert showed presence of mycobacterium tuberculosis (MTB) sensitive to rifampicin. he was started on anti-tuberculosis therapy (ATT) consisting of HRZ and ofloxacin (Ofx). At 2 months of age his weight was 2.2 kg. On examination at 5 months of age, weight was 3.8 kg, he had tachypnea with alae nasi flaring and bilateral crepts. Other systems were normal. CT Chest showed decrease in the fibrocystic lesions (figure 2). He was

continued on the same ATT and started on steroids (1 mg/kg/day) to which he had a dramatic response. He was shifted to HR after a month and steroids were omitted after 2 months. He completed his ATT in August 2011 and at 1 year of age his weight was 8.1 kg.

**Figure 1.** CT chest showing fibrocystic lesions in left lower lobe with consolidation and air bronchogram in right upper lobe



**Figure 2.** CT chest showing decrease in the lesions as compared to previous CT chest



**Address for Correspondance:** Dr Rishika Sakaria,  
Seth G S Medical College, KEM Hospital, Parel,  
Mumbai, India.

**Email:** rishika.sakaria@gmail.com

©2021 Pediatric Oncall



## Discussion

Paradoxical reactions are more commonly reported in HIV-infected patients where they are supposed to occur due to immune reconstitution (Immune Reconstitution Inflammatory Syndrome) in previously immunocompromised patients following Anti-Retroviral Therapy (ART). However they are also reported during ATT in HIV-negative patients.<sup>3</sup> Paradoxical reactions occur in around 16% tuberculosis patients receiving anti tuberculosis therapy (ATT)<sup>4</sup> However, paradoxical reactions in congenital TB have been rarely reported.<sup>1</sup>

Congenital TB is diagnosed based on revised Beitzke's criteria proposed by Antwell et al.<sup>5</sup> Our patient is a premature infant born to a tuberculosis infected mother with uterine TB diagnosed of having progressive pulmonary tuberculosis at the age of 2 months. Since our patient had no contact with other patients having tuberculosis, it is most likely that he acquired TB while passing through the birth canal.

A paradoxical reaction needs to be differentiated from secondary infections, drug resistant TB, malabsorption of ATT and noncompliance.<sup>6</sup> This is because paradoxical reactions require no change in ATT, however the above conditions may require addition/omission of certain drugs. In our patient, the reaction occurred in the form of increasing respiratory distress 3 months after the beginning of ATT (i.e. at 5 months of age) and the child had weight gain. There was marked radiological worsening in the left lower lobe characterised by fibrocystic cavities seen on Chest CT which responded to steroids suggestive of paradoxical reaction.

These reactions are usually self limiting but if severe, may sometimes prove fatal. Hence it is important to recognize and manage them promptly. Most paradoxical reactions respond to a course of steroids probably due to suppression of the inflammatory responses.<sup>1,7,8</sup> Our patient had a dramatic response to steroid therapy

taken over a period of 2 months while continuing the same ATT.

## Conclusion

In patients with congenital TB, paradoxical reactions can occur while on ATT and a close watch should be kept for the same.

## Compliance with Ethical Standards

Funding None

Conflict of Interest None

## References:

1. Park JA, Park SS, Park SE. A paradoxical reaction during therapy for congenital tuberculosis. *Int J Inf Dis* 2009;13:e279-e281.
2. Ray M, Dixit A, Vaipai K, Singhi PD. Congenital Tuberculosis. *Indian Pediatr* 2002;39:1167-1168.
3. Breen RA, Smith CJ, Bettinson H, Dart S, Bannister B, Johnson MA, et al. Paradoxical reactions during tuberculosis treatment in patients with and without tuberculosis. *Thorax* 2004;59:704-707.
4. Cheng VC, Yam WC, Woo PC, Lau SK, Hung IF, Wong SP, et al. Risk factors for development of paradoxical responses during antituberculosis therapy in HIV-negative patients. *Eur J Clin Microbiol Infect Dis* 2003;22:597-602.
5. Cantwell MF, Shehab ZM, Costello AM, Sands I, Green WF, Ewing EP Jr, et al. Brief report: Congenital tuberculosis. *N Engl J Med*. 1994;330:1051-1054.
6. Chien JW, Johnson JL. Paradoxical reactions in HIV and pulmonary TB. *Chest* 1998;114:933-936.
7. Shah I, Chilkar S, Patil M, Ali U. Acute respiratory distress during paradoxical reaction to antituberculosis therapy in an 8-month-old child. *Lung India* 2012; 29:381-383.
8. Janmeja AK, Das SK. Cervico-mediastinal lymphadenopathy as a paradoxical response to chemotherapy in pulmonary tuberculosis. A case report. *Respiration* 2003; 70:219-230.