

---

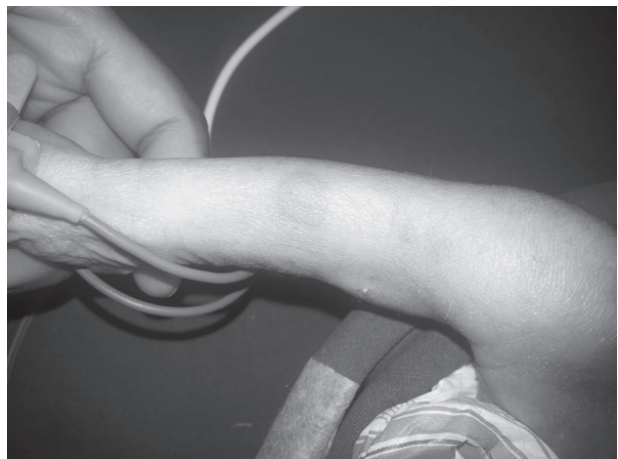
## LETTER TO EDITOR (VIEWERS CHOICE)

### **ERYTHEMA MULTIFORME – A RARE PRESENTATION OF NEONATAL FUNGAL UTI**

*Kalane Shilpa, Suryawanshi Pradeep, Vaidya Umesh*

An 8-days-old male preterm infant was admitted to our hospital on day 1 of life for respiratory distress. Distress settled over next 2 days. On day 11 of life, baby developed skin lesions on lower limbs that spread to his entire body within a day. His entire body was covered with well-defined annular erythematous patches of variable size, which were typical targetoid shape. The center of the round erythematous patches was darker than the periphery (Fig. 1). However, the face, palms, soles and mucous membranes were spared. The rest of his physical examination was normal. Septic screen was sent. Hemogram was normal. Urine routine showed fungal hyphae and culture grew candida albicans. Serologic findings, including antibodies to herpes simplex virus was negative. A skin biopsy specimen obtained from his right lower leg revealed a lymphohistiocytic infiltration in the upper dermis with papillary edema. Vacuolar degeneration of the basal cell layer and necrotic keratinocytes within the epidermis were also observed. These findings were compatible with the diagnosis of erythema multiforme. The patient improved rapidly upon administration of intravenous Fluconazole. The skin lesions cleared without scarring within a few days, urine culture was sterile. At 3 months of follow up, there had been no recurrence or other systemic sequelae.

**Figure 1: Typical targetoid lesion on right leg**



Erythema multiforme (EM) is an acute, self-limited disorder involving the skin and mucous membranes with common recurrences. EM occurs commonly in adolescents and young adults. EM affects males more often than females, with a male: female ratio ranging from 3:2 to 2:1. Although it can occur in all ages, EM

rarely occurs during infancy and childhood. Indeed, there have been only four cases of biopsy-proven EM during the neonatal period in the literature. (1-5) Many factors, including infections, medications, malignancy, autoimmune disease, immunizations, radiation, sarcoidosis, and menstruation have been linked to the development of erythema multiforme (EM). (6) Infections account for approximately 90 percent of cases. (6) However, it has rarely been reported in neonates and infants. (1,2) Moreover, to our knowledge, there have been only four cases of biopsy-proven EM during the neonatal period, and no such cases have been reported in India. Suggested etiologic factors of these cases included cow's milk protein, drugs, hepatitis vaccination and candida infection. (7-10) An unusual association of EM with BCG vaccination was demonstrated in 4th case of 36 days old preterm baby. (11)

In this case, the patient did not show any systemic symptoms except for rash. Considering that EM is a reactive phenomenon, fungal urinary tract infection (UTI), could have been related to development of the skin lesions. Dermatological complications after fungal infection are commonly seen. To date, there have not been reports suggesting EM due to fungal infection in neonates. Further studies are needed to evaluate the etiologies and treatment of neonatal EM, and dermatologists should pay attention to this rare event.

**Funding:** None

**Conflict of Interest :** None

**References :**

1. Weston WL, Morelli JG. Herpes simplex virus-associated erythema multiforme in prepubertal children. Arch Pediatr Adolesc Med. 1997;151:1014-1016.
2. Brice SL, Huff JC, Weston WL. Erythema multiforme. Curr Probl Dermatol. 1990;2:5-25.
3. Dikland WJ, Oranje AP, Stolz E, van Joost T. Erythema multiforme in childhood and early infancy. Pediatr

4. Johnston GA, Ghura HS, Carter E, Graham-Brown RA. Neonatal erythema multiforme major. Clin Exp Dermatol. 2002;27:661-664.
5. Torrelo A, Moreno M, Prada I, Celma ML, Zambrano A. Erythema multiforme in a neonate. J Am Acad Dermatol. 2003;48(5 Suppl):S78-S79.
6. Huff JC, Weston WL, Tonnesen MG. Erythema multiforme: a clinical review of characteristics, diagnostic criteria, and causes. J Am Acad Dermatol. 1983;8(6):763.
7. Ashkenazi S, Metzker A, Rachmel A, Nitzan M. Erythema multiforme as a single manifestation of cow's milk intolerance. Acta Paediatr 1992;81:729-730.
8. Nanda S, Pandhi D, Reddy BS. Erythema multiforme in a 9-day-old neonate. Pediatr Dermatol 2003;20:454-455.
9. Wine E, Ballin A, Dalal I. Infantile erythema multiforme following hepatitis B vaccine. Acta Paediatr 2006;95:890-891.
10. Korting HC, Vieluf D. Erythema multiforme and dermatitis seborrhoides infantum as concomitant id-reactions to widespread candidosis in a suckling. Mycoses 1991;34:415-417.
11. Young Joon Cho, Sun Young Huh, Jong Soo Hong, Jae Yoon Jung, Dae Hun Suh. Neonatal erythema multiforme : A case report. Ann Dermatol 2011; 239(3):382-385.

---

**From:** Department of Neonatology, Sahyadri Speciality Hospital, Pune, Maharashtra, India.

**Address for Correspondence:** Dr Shilpa Kalane, Flat No. 202, G Building, Wondercity society, Katraj, Pune 411046.

**Email:** shilpauk1@gmail.com



**DOI No.** 10.7199/ped.oncall.2015.5

---