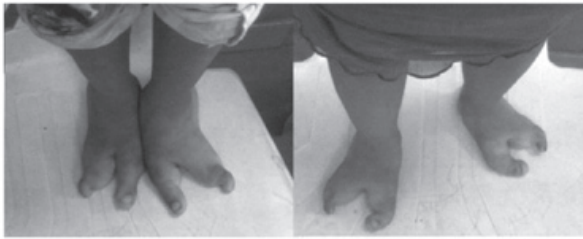
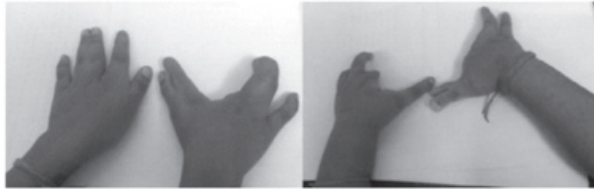


## SPOT DIAGNOSIS (IMAGE GALLERY)



**Fig 1** Image showing feet (a) 7 yr (b) 3 yr old female siblings with median cleft of both the feet.



**Fig 2** Image showing hands (a) 7 yr girl with syndactyly of middle finger and ring finger of left hand, and median cleft of the right hand. (b) 3 yr girl with hypoplastic little finger, middle finger and index finger of left hand, median cleft, hypoplasia and syndactyly in right hand.

### FAMILIAL CASE OF DEFORMED LIMBS

**Sunil Taneja, Purvi Mittal\*, Rakhi Jain, Gulnaz Nadri, Ruchi Puri, Shailendra Singh Rathore**

*Department of Pediatrics, Madhuraj hospital Pvt (Ltd), Kanpur and \*Department of Pediatrics, Ganesh Shankar Vidyarthi Memorial Medical college, Kanpur, UP, India.*

**Address for Correspondence:** Purvi Mittal, Flat No. 7 Panch Ratan App. 7/128 Swaroop Nagar Kanpur, 208002, India. Email: purvimittal@gmail.com.

Two sisters, one 3 years old and the elder one 7 years old, born of non-consanguineous marriage presented to us with deformed hands and feet since birth. Both the girls had deep median cleft of the feet. Hands also had similar deformities. Mother of both the sisters, who is a teacher by profession, also had similar deformities of hands and feet. In the left hand, thumb and index finger were deformed, in the right hand, there was syndactyly of the middle finger and ring finger with hypoplasia of thumb and index finger. The X-rays of the left hand showed hypoplastic metacarpals and all the phalanges of thumb along with hypoplastic distal phalanx of index finger. X-ray

of the right hand showed absent distal phalanx of thumb and index finger. Both the feet also had a deep midline cleft. There was syndactyly with absence of multiple metatarsals and phalanges in both the feet.

### What is the diagnosis?

Split-hand split-foot malformation (SHFM) or ectrodactyly, also known as "lobster claw hand," is a limb malformation involving the central rays of the autopod and presenting with syndactyly, median clefts of the hands and feet and aplasia or hypoplasia of the phalanges, metacarpals and metatarsals. There is median cleft in the hand and feet due to the absence of the central digital rays, which gives the appearance of a lobster. (1) This is a rare genetic disorder with an incidence of 1:90,000. (2) In ectrodactyly, the hand or foot or both appear split into two halves with failure of development of the phalanx, metacarpal and or metatarsal bones of one or more fingers and or toes. The spectrum of expression can be in form of just cutaneous syndactyly of digits to absence of the entire autopod. (3-5) and several instances of non-penetrance have been documented. (4) A large number of human gene defects can cause SHFM. In 2011, a novel mutation in DLX5 was found to be involved in SHFM. (6) A mutation in 7q21-q22 and chromosome 3q27 (p63 gene) is found in families affected by SHFM syndrome and in families affected by EEC syndrome (ectrodactyly-ectodermal dysplasia-cleft syndrome). (7) In majority of cases SHFM undergoes autosomal dominant mode of inheritance with reduced penetrance but other types of inheritance have also been reported. (1) Common anomalies associated with ectrodactyly include tibial aplasia, craniofacial defects, and genitourinary abnormalities. (3) Ectrodactyly-ectodermal dysplasia-clefting syndrome (EEC) is the prototypical example of ectrodactyly syndrome accompanied by multiple organ defects. It is defined by a triad of ectrodactyly, ectodermal dysplasia and cleft lip and palate. (3) Since this malformation has an identified gene TP63 ideally efforts should be made to screen all the family members for this gene mutation. Ectrodactyly is a complex malformation and molecular diagnosis is important for complete evaluation of each case. It also requires a complete genetic evaluation along with a multi disciplinary team to manage the various associated anomalies.

### References

1. Seidler M, Socha M, Jamsheer A. Split-hand, foot malformation - molecular cause and implications in genetic counseling. *J Appl Genetics*.2014; 55: 105-115
2. Köhler R, Sousa P, Jorge CS. Prenatal diagnosis of the ectrodactyly, ectodermal dysplasia, cleft palate (EEC) syndrome. *J Ultrasound Med*. 1989; 8: 337-339
3. Pinette M, Garcia L, Wax JR, Cartin A. Blackstone J. Familial ectrodactyly. *J Ultrasound Med* 2006; 25: 1465-1467
4. Duijf P, van Bokhoven H, Brunner HG. Pathogenesis of split-hand, split-foot malformation. *Hum Mol Genet* 2003; 12: 51-60
5. Elliott AM, Evans JA, Chudley AE. Split hand foot malformation (SHFM). *Clin Genet* 2005; 68: 501-505
6. Shamseldin, HE, Faden MA, Alashram W, Alkuraya FS. Identification of a novel DLX5 mutation in a family with autosomal recessive split hand and foot malformation. *J Med Genet*. 2012; 49:16-20
7. Katarincic JA. Cleft Hand. *J Hand Surg (Am)*. 2003; 3: 108-116



**E-published:** January-March 2015. **DOI No. :** 10.7199/ped.oncall.2015.2