

CASE REPORTS

SIGMOID SINUS THROMBOSIS COMPLICATED WITH SUBDURAL SUBJACENT HEMATOMA AFTER A MINOR TRAUMA IN A CHILD - HOW TO MANAGE?

Mariana Oliveira Pereira¹, Mariana Benita Afonso², Ângela Pereira¹, Cláudia Patraquim¹, Josué Pereira^{3,4}.

¹Department of Paediatrics, Hospital de Braga, Braga, Portugal,

²Department of Immunotherapy, Hospital de Braga, Braga, Portugal,

³Paediatric Neurosurgery Unit, Department of Neurosurgery, Centro Hospitalar Universitário do São João, Porto, Portugal,

⁴Faculty of Medicine, University of Porto, Porto, Portugal.

ABSTRACT

Cerebral venous sinus thrombosis (CVST) is a rare but potentially life-threatening condition, particularly in children. We present a case of a 6-year-old boy who presented to the emergency department with headache and vomiting following a minor head injury. Initial computed tomography scan showed a small retrocerebellar subdural hematoma and further investigation revealed thrombosis of the right sigmoid sinus. Despite the presence of associated hematomas, the patient was initiated on anticoagulation therapy and demonstrated clinical and radiological improvement. CVST following head trauma is rare in children but should be considered in cases where symptoms persist despite normal initial imaging. Early diagnosis and anticoagulation therapy can lead to successful outcomes.

Introduction

A 6-year-old boy, with no prior medical history, presented to our emergency department after falling from his bed two days prior. The fall was not witnessed, but he sustained an injury to the right temporo-occipital region of his head, with a small hematoma. He was observed in another hospital on the day of the fall and a head computed tomography (CT) scan 1.5 hours after the fall was normal. However, the following day, he began experiencing symptoms including headache, vomiting in an upright position, gait imbalance and prostration. His vital signs were stable, with no other neurological deficits. He had no papilledema. He repeated simple CT scan that showed a small retrocerebellar subdural hematoma with 4 mm, with no mass effect (Figure 1). He was admitted for observation but showed no improvement. Due to the discrepancy between his clinical presentation and imaging, a head magnetic resonance image (MRI) was performed, which revealed a thrombosis of the right sigmoid sinus. Blood tests showed no signs of coagulation disorders. He was diagnosed with cerebral venous sinus thrombosis (CVST) and retrocerebellar subdural hematoma, attributed to vascular damage caused by the apparently minor head trauma. He was transferred to a specialized hospital to monitor and initiate anticoagulation therapy. After starting unfractionated heparin, he demonstrated clinical improvement on the third day of hospitalization. On the seventh day, a CT scan showed symmetrical blood flow in the sigmoid sinus. He was switched to

Address for Correspondance: Mariana Oliveira Pereira, Rua Paio Peres, n26, Fraião, 4715-145 - Braga.

Email: mariana69055@gmail.com

©2023 Pediatric Oncall

ARTICLE HISTORY

Received 19 July 2023

Accepted 24 August 2023

KEYWORDS

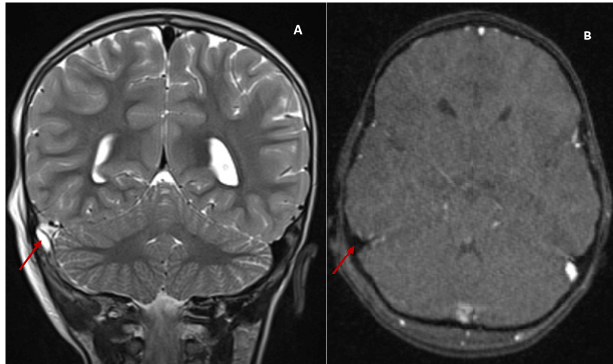
cerebral venous sinus thrombosis, sigmoid sinus thrombosis, head trauma, pediatric, anticoagulation.

a vitamin K antagonist (VKA) on the fifteenth day, that was continued for six months and maintained heparin until reaching a therapeutic INR (International Normalized Ratio). He was discharged on the twenty-first day with no deficits. Six months later, a head venous MRI revealed complete recanalization of the sigmoid sinus and coagulation studies did not reveal other possible underlying causes.

Figure 1. Initial noncontrast head CT performed in the emergency department showed a small retrocerebellar subdural hematoma, with 4 mm, with focal hyperdensity (arrow).

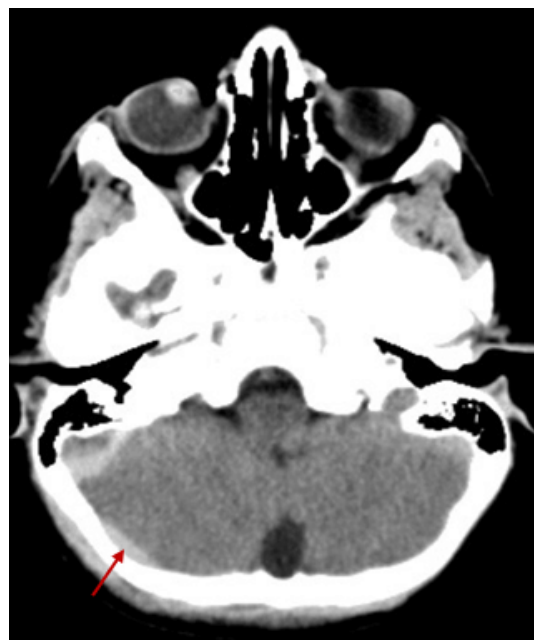

Figure 2. Contrast-enhanced MRI venography of the head. The thrombus is depicted as having increased signal intensity on the T2-weighted coronal phase contrast image (A) and hypointense signal on the T1-weighted axial phase contrast image (B), as indicated by the red arrows. The normal flow of the left sigmoid sinus is depicted by the white arrows.



Discussion

CVST is a rare but potentially life-threatening condition that affects children and adults. The incidence of CVST in children is lower than in adults, with about seven cases per million children per year. However, the risk is higher in neonates than in older children. In children, the most common risk factors for CVST are head and neck infections, such as otitis media and mastoiditis. Unlike in adults, idiopathic events are less common. Other frequent risk factors in children include underlying medical conditions that affect blood clotting, such as nephrotic syndrome, sickle cell anaemia, autoimmune diseases such as systemic lupus erythematosus, malignancy or head trauma. Children with a family history of blood clots are also at increased risk of developing CVST.^{1,2,3/} Head injury is a rare cause of CVST, accounting for only 3-4% of cases. Patients after head injury are thought to have an increased tendency to form blood clots, which can potentially lead to thrombosis. Medical research has suggested that blood clot formation resulting from head injuries may be triggered by damage to the sinus endothelium, extension of thrombi from abrasions on the scalp or injury to the emissary veins. Children are more likely than adults to develop post-traumatic dural sinus thrombosis due to the immaturity of their cerebral venous collateral vasculature and this greater fragility may justify easier rupture and concomitant subdural hemorrhage in CVST.^{1,2} The most frequently involved sinuses in CVST are the major dural superficial sinuses, particularly the superior sagittal and the transverse sinuses. Although some reports have described an association between closed-head injury and superior sagittal and transverse sinus thrombosis, clinical descriptions of sigmoid sinus thrombosis after closed-head injury are rare. No clinical series have related traumatic sigmoid sinus thrombosis with the severity of the injury, as both mild and severe head trauma have been described.^{3,4,5} Symptoms of CVST can vary and may develop gradually or suddenly. The most common symptoms in children include headache, nausea, vomiting, seizures, vision changes and weakness or numbness in the limbs. In severe cases, CVST can lead to a coma or death. Generally, the symptoms of CVST in

children are similar to those in adults, but children are more likely to experience neurological deficits and seizures are more frequent in neonates. Most lateral or sigmoid sinus occlusions do not produce neurological deficits, especially when the sinus involved is nondominant or if rich collateral circulation exists.^{1,2,3,4} Diagnosing CVST can be a challenging task because its symptoms are similar to those of other conditions. However, if a child has recently suffered a head injury and is showing signs of CVST, head CT is likely to be used as an initial diagnostic tool for head trauma as it is quick and widely available. CVST can be detected by observing clots in cortical veins, known as the "cord sign" or filling defects in the superior sagittal sinus, known as the "empty triangle sign" or "empty delta sign". An increased density in the affected sinus and cerebral edema may be present in some cases. Unfortunately, the sensitivity of a simple CT scan for CVST is only between 20-43%. If skull fractures across the sinus and epidural hematoma are detected on the CT scan, it indicates a high risk for CVST and additional imaging examinations such as venous CT and MRI should be considered. T1- and T2-weighted MRI signals will often show isointense and hypointense signals, respectively, with acute blood clots and increased signal on both T1- and T2-weighted studies as the clot ages. There are no specific clinical features or clear guidelines for the diagnosis of CVST, but it is crucial to consider this diagnosis when a fracture or hematoma around the sinus is observed.^{1,2,6,7} Treatment for CVST typically involves the use of anticoagulant medications to dissolve the blood clot and prevent the formation of new clots. Current guidelines state that intracranial hemorrhage does not represent a contraindication to anticoagulant therapy in the acute phase of CVST, but there is no consensus on which type of heparin is superior. In this case, the hypocoagulation in the acute phase was conditioned by the coexistence of a post-traumatic hematoma. In the presence of bleeding complications, intravenous administration of heparin allows a more adequate adjustment of hypocoagulation. Although there are no randomized controlled trials on anticoagulant treatment in children with CVST, current guidelines suggest using therapeutic doses of heparin regardless of any concomitant intracranial hemorrhage. Endovascular treatment is recommended for patients experiencing rapidly deteriorating neurological function despite adequate anticoagulation, similar to the approach used in adults.^{3,6} According to current guidelines, patients with CVST caused by a temporary risk factor should be treated with anticoagulant therapy using a VKA for a period of 3 to 6 months, while maintaining an INR range between 2 and 3. On the other hand, those with unprovoked CVST should receive therapy for 6 to 12 months. Repeat imaging using CT or MRI is recommended 3 to 6 months from the initial event or if persistent or recurrent symptoms suggestive of CVST occur during anticoagulation therapy. If complete recanalization occurs, no further neuroimaging is necessary, but if partial recanalization occurs, extending anticoagulation until a reassessment at 12 months from the event should be considered.³

Conclusion

CVST is a potentially life-threatening and infrequent condition that can rarely occur after a closed head injury



in children. Identifying the disorder can be difficult since the symptoms are vague and nonspecific. Therefore, in cases of head trauma where signs and symptoms of increased intracranial pressure, seizures, vision changes or weakness or numbness in the limbs are present and there are no major cerebral CT lesions, the diagnosis of CVST should be considered, even if initial brain imaging results are negative. Early diagnosis and treatment can lead to successful outcomes, with most children fully recovering and leading healthy lives.

Compliance with Ethical Standards**Funding:** None**Conflict of Interest:** None**References**

1. Ochiai K, Nishiyama K. Post-traumatic cerebral sinus thrombosis. *BMJ Case Rep.* 2021;14(2):e239783. doi:10.1136/bcr-2020-239783.
2. Lebowitz DC, Ko MW, Cameron EK, et al. Cerebral sinus thrombosis in a 6-year-old boy after a minor head injury. *Pediatr Emerg Care.* 2014;30(3):177-179. doi:10.1097/PEC.000000000000088.
3. Capecchi M, Abbattista M, Martinelli I. Cerebral venous sinus thrombosis. *J Thromb Haemost.* 2018;16(10):1918-1931. doi:10.1111/jth.14210.
4. Taha JM, Crone KR, Berger TS, et al. Sigmoid Sinus Thrombosis after Closed Head Injury in Children. *Neurosurgery.* 1993;32(4):541-545.
5. Awad AW, Bhardwaj R. Acute posttraumatic pediatric cerebral venous thrombosis: Case report and review of literature. *Surg Neurol Int.* 2014;5(Suppl):S42-S45. doi:10.4103/2152-7806.130908.
6. Jackson B, Porcher F, Zaption D, et al. Cerebral Sinovenous Thrombosis in Children and Neonates - Diagnosis and Treatment. *Pediatr Emerg Care.* 2015;27(9):874-883. doi:10.1177/1076029614523491.
7. Hersh DS, Shimony N, Groves ML, et al. Pediatric cerebral venous sinus thrombosis or compression in the setting of skull fractures from blunt head trauma. *J Neurosurg Pediatr.* 2018;21(3):258-269. doi:10.3171/2017.9.PEDS17311.