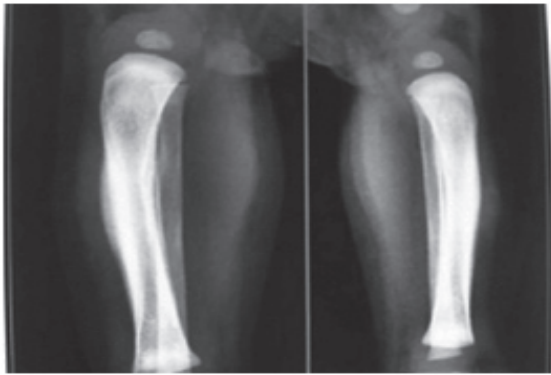


## SPOT DIAGNOSIS (IMAGE GALLERY)

**TIBIAL PERIOSTEAL REACTION**

**Sunil Taneja, Rakhi Jain, Gulnai Nadri, Shailendra Singh Rathore**

*Madhuraj Hospital, Kanpur, India.*

**Address for Correspondence:** Dr. Rakhi Jain, 98, YI, Kidwai Nagar, Kanpur, India. Email: drrakhi09@gmail.com

A one and a half month old male child presented with irritability and localized swelling over both lower limbs for one week, discovered by the mother while oil massage. There was no history of fever and trauma. The child was born at term by normal delivery. Immunization was complete for age and the baby was exclusively breast fed. There was no history of intake of vitamin supplements. There was no

similar history in the parents or sibling nor was there any social problem in the family. On examination, the child was irritable. There was no dysmorphism. Weight, length and head circumference were 4.6 kg, 59 cm and 37.5 cm respectively which were normal for age. There was firm swelling over the medial surface of tibia on both lower limbs which was tender to touch. There was no other swelling over rest of the body. Systemic examination was normal. Investigations showed hemoglobin 11.7gm/dl, total leucocyte count 8400 cells/cumm, platelet count 2,75,000 cells/cumm, ESR 12mm at end of 1 hour, serum calcium 7.8 mg/dl, phosphorus 2mmol/l and alkaline phosphatase 469 IU/L. VDRL of mother was negative. X ray of both lower limbs showed periosteal reaction and sclerotic changes of both tibial bones but there were no osteolytic changes. X ray skull and mandible were normal. MRI of leg showed mild periosteal elevation.

**What is the diagnosis?**

Caffey's disease or Infantile Cortical Hyperostosis (ICH). It is a rare disorder of unknown etiology. Among the proposed causes are, infections, immunological defects and genetic abnormalities. (1) It is characterized by cortical hyperostosis along with inflammation of the adjacent muscle and fascia. Usually sporadic in nature but may be autosomal dominant or autosomal recessive. (2) Mutations of the COL1A1 gene (codes for the  $\alpha$ 1 chain of type I collagen) has been reported. (3,4) It usually presents in infancy with sudden irritability, soft tissue swelling over the involved bones having a woody induration without suppuration, fever and anorexia. Mandible is the most commonly involved site followed by scapula, clavicle, ribs and long bones. There are usually no other signs and symptoms. (1) The disease may be self-limiting but is also known to have an unpredictable course with remissions and relapses. A high index of suspicion with a good radiology and laboratory backup is thus necessary to make a diagnosis and plan treatment. Differential diagnosis includes osteomyelitis, hypervitaminosis A, syphilis, scurvy, hyperphosphatemia, bone tumors and child abuse. Radiography is the most valuable diagnostic study in ICH showing cortical new bone formation (cortical hyperostosis) beneath the regions of soft tissue swelling, which is the characteristic feature. While no laboratory tests are specific for diagnosis of ICH, the present case had the typical radiological features while normal laboratory parameters helped rule out other differential diagnosis. Caffey's disease is mostly self-limiting and resolves within six months to one year and may not need any treatment. However, indomethacin or naproxen could be used in really symptomatic cases. (5) This case highlights the involvement of long bones in Caffey's Disease.

**Funding:** None

**Conflict of interest:** None

**References:**

1. Kuttly N, Thomas D, George L, John TB. Caffey Disease or Infantile Cortical Hyperostosis: A Case Report. *Oman Med J*. 2010; 25: 134-136
2. Kleigman RM, Berhman RE, Jenson HB, Stanton BF. *Nelson Textbook of Paediatrics*. 18th ed. Philadelphia: Saunders; 2008: 2885
3. Glorieux FH. Caffey disease: an unlikely collagenopathy. *J Clin Invest* 2005;115: 1142-1144
4. Cerruti-Mainardi P, Venturi G, Spunton M, Favaron E, Zignani M, Provera S, et al. Infantile cortical hyperostosis and COL1A1 mutation in four generations. *Eur J Pediatr*. 2011; 170: 1385-1390.
5. Dutta S, Jain N, Bhattacharya A, Mukhopadhyaya K. Infantile Cortical Hyperostosis. *Indian Pediatr*. 2002; 39:1057

**DOI No. :** 10.7199/ped.oncall.2014.18

Quick Response Code

