

LETTER TO EDITOR (VIEWERS CHOICE)

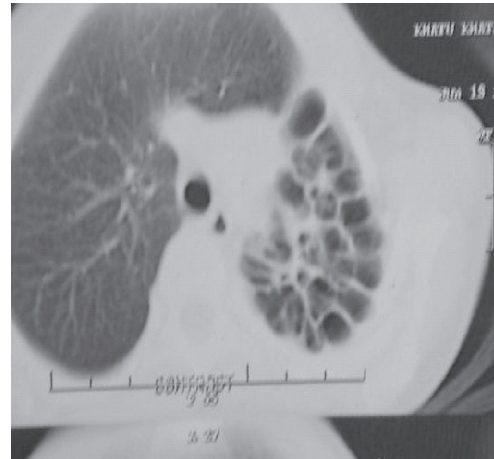
CONGENITAL CYSTIC ADENOMATOID MALFORMATION OF LUNG AND ECTOPIC KIDNEY IN A CASE OF SECKEL'S SYNDROME

Sutapa Ganguly, Tryambak Samanta

Keywords: Seckel's syndrome, cystic adenomatoid malformation of lung (CAM), ectopic kidney.

An eleven-year-old Bengali Muslim girl attended the pediatric medicine OPD for cough & cold for 2 weeks. Her short stature, bird like head and the characteristic facial features attracted our attention and she was admitted in the pediatric medicine ward. She was a product of consanguineous marriage with death of seven siblings in the neonatal period or early infancy. Two of the siblings were reported to be very small in size. At present she has two elder sisters 18 years and 16 years old and one younger sister and one younger brother 6 years and 3 years old respectively. The anthropometric measurement of the parents and living siblings are within normal limit. She was home delivered at 37 weeks of gestation and her size was as small as her mother's palm. There was history of delayed development of motor and mental milestones. On examination, her height was 76 cm (50% of expected), upper segment was 39 cms, lower segment 37 cms (US: LS ratio 1.05), and arm span was 75 cms. Her weight was 5 kg (13% of expected) and head circumference 38 cms. She had a beak like protrusion of the central area of face, prominent beaked nose, large eyes and ears, sparse hair and clubbing of fingers and toes. She was afebrile and active. Her respiratory rate was 38/min. There was shifting of mediastinum, to the left and there was coarse crepitation on the left side of chest. Laboratory studies revealed, Hb - 10.1 gm%, TLC- 10,400/cmm, neutrophil 38%, lymphocyte 60%, eosinophil 02%, ESR - 50 mm /1st hour. Blood culture yielded no organism. Mantoux test (with 5 TU) was negative. Skeletal survey revealed her bone age to be of 11 years. Thyroid function tests were normal. Basal level of pituitary growth hormone was normal (12 µg/dl) and that after producing hypoglycemia by subcutaneous human insulin was 19 mg/dl. Sweat chloride test was normal. Chest X-ray showed fibrosis of the left lung with same sided mediastinal shift. HRCT thorax revealed destruction of left lung parenchyma, which was replaced by numerous thin walled cystic lesions of almost uniform sizes with contraction of lung volume and ipsilateral mediastinal shifting. There was herniation of the right lung into the left and crowding of ribs on the left side. The findings were suggestive of congenital cystic adenomatoid malformation (CAM) of the left lung (Figure 1). USG of abdomen showed left sided ectopic kidney in the pelvis with normal corticomedullary differentiation. In 6 months follow up there was no gain in height and weight of the child.

Figure 1. HRCT vertical section showing cystic adenomatoid malformation of left lung and shifting of mediastinum to same side.



This condition was given two names, bird-headed dwarfism and nanocephaly by Rudolf Virchow (1). Seckel in 1960 described the disease picture on the basis of two cases he had studied in Chicago, as well as thirteen cases of nanocephalic dwarfs reported in literature over 200 year period (2). In addition to dwarfism of low birth weight type, the features are small head, large eyes, beak-like protrusion of the nose, narrow face and receding lower jaw. Mental retardation is not as marked as might be expected in view of the very small brain. Multiple occurrences in the same siblings, increased frequency of parenteral consanguinity, occurrence in both sexes and normal parents suggest autosomal recessive inheritance (3-5). Various associations with Seckel's syndrome are reported. Hayani et al described a female who was diagnosed as Seckel's syndrome at 2 years of age. At 26 years she was diagnosed as acute myeloid leukemia (AML) (6). Different malformations of cortical development as documented by magnetic resonance imaging were described by Capovilla G et al (7). One case was associated with Legg-Calve-Perthes disease (8). There has been a report of association of Seckel's syndrome with CAM of the lung (9). Our patient similarly had Seckel's syndrome with CAM in addition to ectopic kidney.

Contributors: SG was involved in clinical diagnosis, search of literature and finalizing the manuscript. TS was involved in management of the case and drafting of the manuscript.

Conflict of Interest: None

Funding: None

Acknowledgement: Arunava Bhattacharya for data collection

References

1. Virchow R. Zwergenkind. Zeitschrift fur Ethnologie, Berlin, 1882, 14: 215.
2. Seckel HPG. In: Bird-headed Dwarfs: Studies in Developmental Anthropology Including Human Proportions. Eds: Springfield C, Thomas C. S. Karger, Basel-New York, 1960.
3. Black J. Low birth weight dwarfism. Arch Dis Child 1961; 36: 633-644.
4. Harper RG, Orti E, Baker RK. Bird-beaded dwarfs (Seckel's syndrome). A familial pattern of developmental, dental, skeletal, genital, and central nervous system anomalies. J Pediatr. 1967; 70: 799-804.
5. McKusick VA, Mahloudji M, Abbott MH, Lindenberg R, Kepas D. Seckel's bird-headed dwarfism. N Engl J Med. 1967; 277: 279-286.
6. Hayani A, Suarez CR, Molnar Z, LeBeau M, Godwin J. Acute myeloid leukaemia in a patient with Seckel syndrome. J Med Genet. 1994; 31: 148-149.
7. Capovilla G, Lorenzetti ME, Montagnini A, Borgatti R, Piccinelli P, Giordano L, et al. Seckel's syndrome and malformations of cortical development: report of three new cases and review of the literature. J Child Neurol. 2001; 16: 382-386.
8. Rubbini L, Preti P, Sudanese A, Brillante C. Seckel's syndrome: presentation of one case associated with Legg-Calve-Perthes disease. Chir Organi Mov. 1991; 76: 193-195
9. Aslan Y, Aynaci FM, Baki A, Soylu H, Harova G. Seckel's syndrome associated with congenital cystic adenomatoid malformation of the lung. Acta Paediatr. 1995; 84: 839-840.

From : Department of Pediatric Medicine, NRS Medical College, Kolkata, West Bengal, India.

Address for Correspondence: Dr Tryambak Samanta, 15/D, Lenin Sarani, Serampore, Dist Hooghly, WB-712203. Email: ts_ped@rediffmail.com

E-published : February 2010

LETTER TO EDITOR (VIEWERS CHOICE)

HYPHIDROTIC ECTODERMAL DYSPLASIA

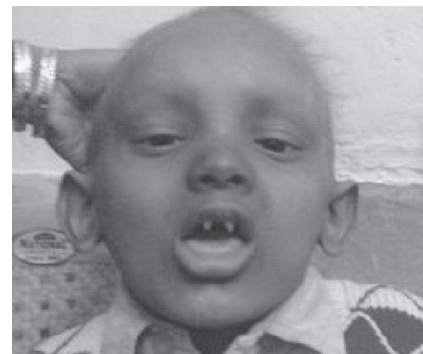
Neerupam Gupta, Shirin Nomani**, Vikram Gupta***, Sanjeev Kumar Digra*****

Key Words: Ectodermal Dysplasia, Hypohydrotic, Anodontia

We report two male sibs one 6 years and another 3 years of age from a nonconsanguineous married Hindu family. Both were admitted in department of Pediatrics, SMGS hospital, Govt Medical College, Jammu with history of high grade fever and cough of short duration with a background history of frequent rise of body temperature since early infancy. Absence of sweating even in hot summer, lack of hair and abnormal dentition were associated complaints. Family history revealed healthy parents with these two sons without history of similar illness in relatives. Clinical examination revealed thin strands of silky hair, sparse eyelash, frontal bossing, depressed nasal bridge and dry skin but normal nails in both of them. Elder brother had only two conical upper incisor teeth (Figure 1) but the younger had one. Systemic examinations revealed no abnormality except for few crackles in lungs. Skin biopsy of both the brothers showed thinned out epidermis, absence of sweat glands and pilosebaceous unit in dermis suggestive of hypohidrotic (anhidrotic) Ectodermal dysplasia. Other investigations were nonconclusive. The chest infection in both of these sibs responded to appropriate antibiotics and were discharged after 15 days of hospital stay with advice to avoid high ambient temperatures as far as possible.

Ectodermal dysplasia is a heterogeneous group of disorders characterized by a constellation of findings involving defects of two or more of the following :

Figure 1: Sparse hair and eyelashes with only 2 conical incisor teeth



teeth, skin, and appendageal structures including hair, nails, and eccrine and sebaceous glands. Although 170 ectodermal dysplasias have been described, the majority are rare and only 30 have been genetically defined (1). Hypohidrotic ectodermal dysplasia is also known as anhidrotic ectodermal dysplasia (EDA I) and Christ-Siemens-Touraine syndrome (2). Hypohidrotic ectodermal dysplasia was described as early as 1848 by British physician J. Thurnam (3). The incidence has been reported to be 1 per 10,000 to 1 per 100,000 live births (4). Hypohidrotic ectodermal dysplasia is manifested as a triad of defects: partial or complete absence of sweat glands, anomalous dentition and hypotrichosis. Anodontia or hypodontia with widely spaced, conical teeth is a constant feature (1). Episodes