

## CASE REPORT

### FETAL ADRENAL HEMORRHAGE PRESENTING AS ADRENAL INSUFFICIENCY

Shenoy V, Prabhu R, Padmini Bhat

#### Abstract

Adrenal hemorrhage is not uncommon in newborns. Adrenal insufficiency usually occurs when there is bilateral adrenal hemorrhage. Adrenal insufficiency due to unilateral adrenal hemorrhage is rare. We are presenting a case of fetal unilateral adrenal hemorrhage presenting with features of adrenal insufficiency.

**Keywords:** Adrenal insufficiency, fetal unilateral adrenal hemorrhage

#### Introduction

Adrenal hemorrhage is not uncommon in newborns and is one of the most common causes of adrenal mass in neonatal age group. Incidence of adrenal hemorrhage based on extensive necropsy has been estimated as about 1.7 per 1000 births (1). Adrenal insufficiency usually occurs when there is bilateral adrenal hemorrhage and has not been reported until at least 90% of adrenal tissue is destroyed. Unilateral adrenal hemorrhage is rarely of clinical significance. Adrenal insufficiency due to unilateral adrenal hemorrhage is rare. We are presenting a case of fetal unilateral adrenal hemorrhage presenting with features of adrenal insufficiency.

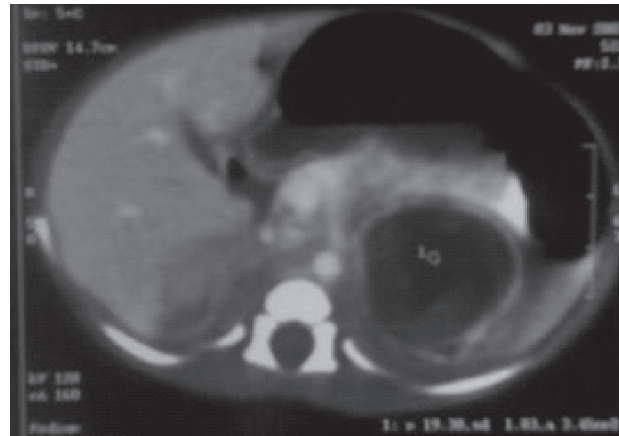
#### Case Report

A 25 years old primigravida presented at 38 weeks of gestation with an antenatally diagnosed fetal left suprarenal mass measuring 3.6cm x 2.4cm mildly with few hypoechoic areas within the lesion displacing left kidney laterally during routine real time Ultrasonogram. No obvious increase in vascularity was noted. Fetal biophysical profile, fetal structures & amniotic index were all normal. Mother had an uneventful antenatal period. An elective lower segment caesarian section was done at 38 weeks. A male baby weighing 2.8kg was delivered. Apgar was 7 & 9 at 1 & 5 minutes respectively.

Physical examination of newborn was normal. There was no pigmentation of nipple, scrotal or axillary areas. There was no palpable mass per abdomen. Postnatally the ultrasonography of newborn showed same features as the antenatal ultrasound. CT scan showed evidence of well defined hypodense mass lesion with peripheral rim enhancement noted in left suprarenal region measuring 3.2 x 3.1cm size. There was no calcification. The lesion was mildly indenting and displacing left kidney inferiorly. (Figure 1). A possibility of left suprarenal haemorrhage was thought of with the differential diagnosis of neural crest tumor. Basic investigations like hemoglobin, blood counts, blood urea, and serum calcium were normal. Coagulation profile and platelet counts were normal. There was persistent hyperkalemia (values being 5.5, 6, 6.7, 6.3mmol/L on 4 occasions) & hyponatremia (serum sodium values being 128.5, 121, 121.2, 129.8 mmol/L). Random serum cortisol was 1.6 mcgm/dl. ACTH stimulation test did not significantly raise the cortisol level. 24 hour urinary VMA levels were normal. In view of persistent hyperkalemia and hyponatremia, low serum cortisol

and abnormal ACTH test, a possibility of left suprarenal haemorrhage with adrenal insufficiency was considered. Hyperkalemia was managed with intravenous calcium gluconate, potassium exchange resin and salbutamol nebulization. Patient was also put on hydrocortisone 5mg/day and fludrocortisone 0.05mg/day after which the potassium levels stabilized. Baby was sent home on these medications. The baby was reviewed on 30th day of life. Weight gain and development were normal. Ultrasonography at follow up showed 50% decrease in size of mass suggesting that we were indeed dealing with adrenal hemorrhage. Sodium and potassium levels were normal at follow up. The medications were continued. At 4 months of age, a repeat ACTH stimulation test was done after stopping medications for a week. Following ACTH, the cortisol levels raised to adequate levels. This suggested recovery and the medications were tapered off. At further follow up, the baby was normal.

**Figure 1: CT scan of abdomen showing left adrenal hemorrhage**



#### Discussion

Adrenal hemorrhage is not uncommonly seen in newborn babies. It can occur prenatally as a result of difficult labour or delivery in infants of diabetic mother or infants who are large for their gestational age. Other causes which can be considered are asphyxia, hypoxia, septicemia or hemorrhagic disorders. Sometimes it can occur in association with renal vein thrombosis. (2) Occasionally the bleeding may be sufficient enough to form a palpable mass which can be mistaken for a tumour. Rarely it may rupture into peritoneum & cause intestinal obstruction or scrotal haematoma. Clinically the child may present with features of acute blood loss, anemia or jaundice. If both glands are involved the newborn may be acutely ill with features of hypoadrenalism. In our patient the cause for fetal adrenal hemorrhage was not identified as there was no thrombocytopenia or coagulopathy. (3) No definite causes for fetal adrenal hemorrhage have been reported in literature. In this case the hemorrhage may have been spontaneous without trauma and intrauterine complications, because of susceptibility

to hemorrhage due to the size and vascularity of the fetal adrenal gland. (4)

Congenital neuroblastoma is an important differential diagnosis. There are no pathognomonic sonographic features of neonatal hemorrhage but serial ultrasound examinations can help to differentiate between these two conditions. A hematoma decreases in size within one to two weeks whereas neuroblastoma tends to retain its echogenicity and does not change in size. Urinary catecholamines are elevated in the majority of cases of neuroblastoma. Colour coded Doppler sonography is useful to differentiate between congenital neuroblastoma and adrenal haemorrhage. In neuroblastoma it shows a network of microscopic vessels that invade the tumour and provide blood supply essential for its growth. This network gives rise to characteristic high velocity doppler shifts. In contrast to neuroblastoma, adrenal haemorrhage is characterized by diminished or absent blood flow. (3) Investigations include imaging in form of ultrasound, CT scan and MRI. MRI can determine the age of the hematoma. (2)

There are no reports in literature whether adrenal insufficiency is transient or chronic following neonatal adrenal hemorrhage. In our patient it was transient

and recovery occurred within 4 months. A short ACTH stimulation test has to be done at regular intervals for monitoring adrenal recovery.

#### References

1. DeSa DJ, Nicholls S. Hemorrhagic necrosis of the adrenal gland in perinatal infants: a clinico-pathological study. *J Pathol.* 1972;106: 133-149
2. Raghavan A. Imaging in adrenal hemorrhage review and protocol. Manipal hospital, Bangalore. CME Art # 11.
3. Patankar JZ, Mali VP, Prabhakaran K. Neonatal adrenal haemorrhagic pseudocyst. *J Postgrad Med.* 2002; 48: 239-240.
4. Smith JA Jr, Middleton RG. Neonatal adrenal hemorrhage. *J Urol.* 1979; 122: 674-677.

---

**From :** K. S. Hegde Medical Academy (KSHEMA), Mangalore, India

**Address for Correspondence:** Dr Vijaya Shenoy. KS Hegde Medical Academy, Deralakatte, Mangalore, Karnataka, India. Email: vijaypaed@yahoo.com

**E-published:** January 2010

---

---

## CASE REPORT

### MARGINAL MANDIBULAR NERVE PALSY AS AN UNUSUAL COMPLICATION IN LUDWIG'S ANGINA

*Dipankar Sarkar\*, Shruti Sarkar\*, Ashutosh S Mangalgiri\*\*, Gagan Thakur\*\*\*, Vijaya Beohar\**

---

#### Abstract

Ludwig's angina is a rapidly spreading cellulitis of the floor of the mouth characterized by firm induration and elevation of the tongue. The cellulitis may spread and cause life-threatening complication by obstructing the airway. Several other complications have been reported secondary to the progress of cellulitis in different anatomical plains. We describe a case of a two year old girl with Ludwig's angina who developed left sided marginal mandibular nerve palsy. This complication has never been reported before.

**Keywords:** Marginal mandibular nerve palsy, Ludwig's angina, complication

#### Introduction

Ludwig's angina is a potentially life-threatening infection of submandibular space characterized by hardness of floor of mouth (1). It presents most often with fever, neck mass or swelling and has a varying degree of systemic toxic symptoms. The spreading cellulitis may cause complications like life threatening obstruction of airway. Cellulitis may progress in different anatomical spaces extending to the lateral pharyngeal space, retropharyngeal space and may even descend to the mediastinum. We present here a case report of a two year old child with Ludwig's angina who had an

unusual complication of paresis of marginal mandibular branch of facial nerve.

#### Case Report

A two year old female child presented with fever for last 4 days along with swelling of the lower part of the face which was progressively increasing in size. She had mild cough and occasional vomiting. She was not taking any oral feeds and was quite irritable. She was the only child of her parents. She was born by normal delivery and her immediate neonatal period was uneventful. She was vaccinated with BCG, OPV, DPT and MMR. Her development was normal and she had not had any significant illness before. On examination she was irritable, febrile and had pallor. She had a brawny, indurated and markedly tender significant swelling in the submandibular region extending both sides up to the parotid region. The floor of the mouth was raised. There was no pharyngeal or tonsillar inflammation. There were multiple enlarged lymph nodes in the neck region. She also had palsy of the left lower part of the face as her angle of mouth was getting deviated to the right side while crying indicating involvement of left marginal mandibular nerve, a branch of cervicofacial division of facial nerve (Figure 1). A clinical diagnosis of Ludwig's Angina was made.