

IMAGES IN CLINICAL PRACTICE

DEPRESSED SKULL FRACTURE CONGENITAL

Patrícia Campos¹, Patrícia Gomes Pereira¹, José Gustavo Soares², Marta Mesquita¹.

¹Pediatrics Department, Centro Hospitalar do Baixo Vouga, Aveiro, Portugal,

²Neurosurgery Department, Hospital Pediátrico, Centro Hospitalar e Universitário de Coimbra, Coimbra, Portugal.

KEYWORDS

Depressed skull fracture, Ping-pong fracture, Congenital fracture, Spontaneous fracture, Newborn, Neurosurgery.

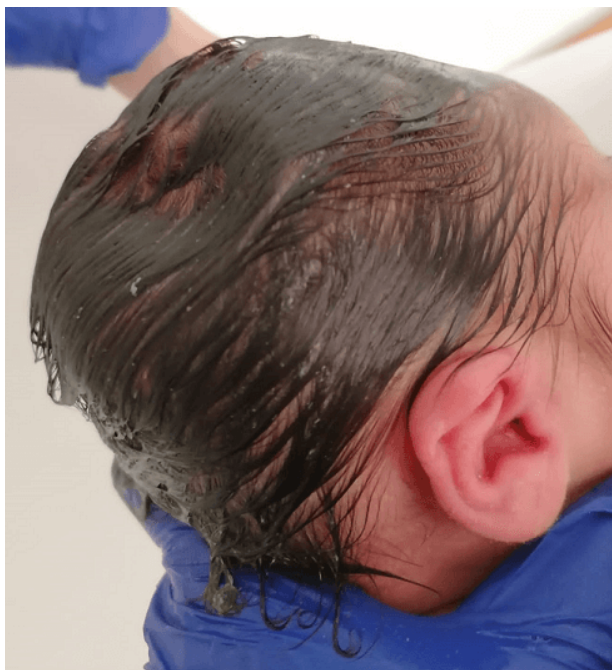ARTICLE HISTORY

Received 27 May 2023

Accepted 1 June 2023

A male term newborn was delivered at 39 weeks of gestation from a 43-year-old woman by an urgent caesarean for fetal bradycardia. Pregnancy was complicated with gestacional diabetes controlled with metformin. Fetal ultrasounds were normal and there was no history of prenatal maternal trauma. The fetus was difficult to extract but no obstetric instruments were used during delievery. He adapted well with an Apgar score of 9 and 10 at first and fifth minutes, respectively. Somatometry at birth was adequate for gestational age: weight of 3500g (50th percentile), length of 48 cm (15th-50th percentile) and head circumference of 35,5 cm (50th-85th percentile). Postbirth physical examination revealed a depression in the right parietal region measuring 4 x 3 cm with 2 cm depth (Figure 1). No local bruising or soft tissue swelling was evident. His neurological examination was normal and there were no other congenital abnormalities.

Figure 1. Depression in the newborn's right parietal bone (at birth).

*What is the diagnosis?*

The diagnosis of depressed skull fracture (DSF) was considered and skull radiography confirmed an abnormal concavity in the right parietal bone (Figure 2). Cranial ultrasound showed no intracranial hemorrhages (ICH) or cerebral edema. Given his good clinical condition, the newborn was discharged home after 48 hours of hospitalization with weekly neurosurgery follow-up consultations. After a 3-week period there was no evident spontaneous remodelling of the skull. Given the fracture's dimensions, surgical elevation of the bone was performed after parental consent with a good clinical outcome (Figure 3). No post-operative complications were reported and the child showed an adequate growth and neurodevelopment over the first year of life.

Figure 2. Skull radiography after birth showing a concavity in the right parietal bone (arrows).

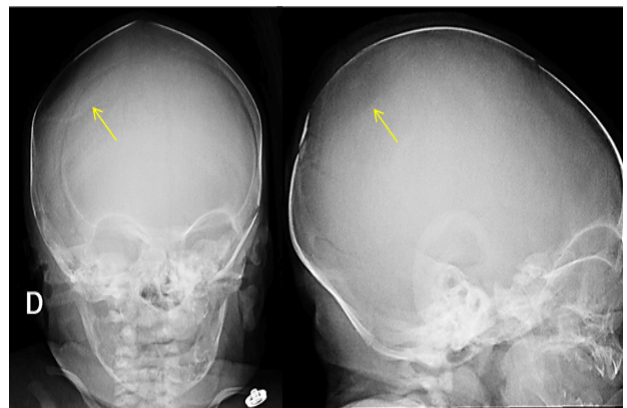
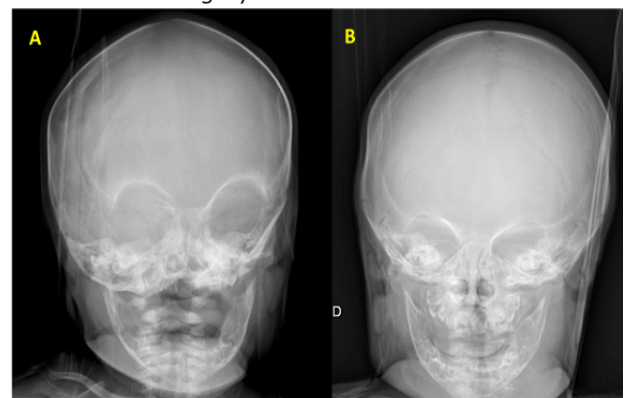


Figure 3. Skull radiography after surgical elevation of the parietal bone. **A.** - One week after surgery. **B.** - Two months after surgery.



Address for Correspondance: Patrícia Campos, Av. Artur Ravara 35, 3810-164 Aveiro, Portugal.

Email: appcampos94@gmail.com

©2026 Pediatric Oncall

DSF, also called *ping-pong* fractures, are a rare condition that occurs in 1-2,5/100.000 neonates. Congenital DSF are commonly associated to birth trauma (instrumentation or maternal bone structures), causing inward buckling of the bones during delivery. Although rare, sometimes they can be observed in newborns following a non-traumatic delivery and are therefore described as spontaneous DSF; these are believed to be caused by prolonged focal pressure on the neonatal skull by structures on the mother's pelvis (ischial bone, sacral promontory, symphysis pubis, uterine fibroid, the fifth lumbar vertebrae, etc.).^{1,2,3} Most cases reported in the literature affect the parietal or frontal bones, as it is believed that the location of the fracture correlates with the presentation of the fetal head to the pelvic inlet.⁴ A concavity in a newborn's skull should always evoke the diagnosis of DSF. Detailed birth history and postnatal examination for evidence of acute injury are crucial to distinguish between spontaneous and traumatic lesions.

Skull radiography often shows the degree of deformation but no fracture line is seen, as there is undisrupted bone continuity.⁵ Cranial ultrasound can identify ICH, hematomas or cerebral edema, that are significantly more frequent in DSF secondary to instrumental delivery. Although a computed tomography scan is a more sensitive exam, given the high radiation exposure it should be performed only if there is diagnostic doubt or associated complications.¹ Some rare but serious complications have been described after compound traumatic DSF, such as cerebral contusions, parenchymal lesions and long-term deficits like epilepsy or brain tumours^{6,7,8} In the present case, the parietal area was involved without any intracranial pathology or neurological deficits, and there was no history of trauma or instrument-assisted delivery, although the fetus was difficult to extract. As there was no local bruising or soft tissue swelling, a traumatic etiology seemed less likely.

Management of this condition is still controversial as there is no standard protocol at the current moment. Since the bone progressively remodels into a normal shape, DSF can be managed expectantly, as described in some previous case reports.^{2,3,9,10} Other treatment options include non-surgical interventions, such as digital pressure or vacuum extractor, and surgical elevation. The choice is usually based on clinical symptoms, the severity of the fracture and the existence of underlying brain injury or increased intracranial pressure.^{3,4}

Spontaneous DSF and those affecting children with a normal neurological examination are associated with a good prognosis and most cases resolve spontaneously within the first six months of life.^{3,10} It has been suggested that a depression greater than 5 mm on

the neonatal skull could lead to a focal area of tissue hypoperfusion and cerebral edema¹¹; however, a critical measurement has not been yet established to indicate the need for intervention. Corrective surgery may be required when no spontaneous remodeling of the skull is observed or in large lesions with a mass effect on brain structures. Further comments and reports on neonates with DSF may be required to enlighten the most adequate treatment approach for each case.

Compliance with ethical standards

Funding: None

Conflict of Interest: None

References:

1. Preston D, Jackson S, Gandhi S. Non-traumatic depressed skull fracture in a neonate or "ping pong" fracture. *BMJ Case Rep.* 2015;2015: bcr2014207077.
2. Ilhan O, Bor M, Yukkaldiran P. Spontaneous resolution of a 'pingpong' fracture at birth. *BMJ Case Rep.* 2018;2018: bcr2018226264.
3. Sorar M, Fesli R, Güner B, Kertmen H, Sekerci Z. Spontaneous elevation of a ping-pong fracture: Case report and review of the literature. *Pediatr Neurosurg.* 2013;48:324-6.
4. Veeravagu A, Azad TD, Jiang B, Edwards MSB. Spontaneous intrauterine depressed skull fractures: report of 2 cases requiring neurosurgical intervention and literature review. *World Neurosurg* 2018; 110: 256-262.
5. Lunt CMB, Roth K, Eich G, et al. Neonatal ping pong fracture. *Swiss Society of Neonatology*, 2006.
6. Dupuis O, Silveira R, Dupont C, et al. Comparison of "instrument-associated" and "spontaneous" obstetric depressed skull fractures in a cohort of 68 neonates. *Am J Obstet Gynecol* 2005;192: 165-70.
7. Tervilä L, Huhmar EO, Krokfors E. Cerebral birth injury as a cause of epilepsy. *Ann Chir Gynaecol Fenn* 1975;64: 118-22.
8. Gurney JG, Preston-Martin S, McDaniel AM, et al. Head injury as a risk factor for brain tumors in children: results from a multicenter case-control study. *Epidemiology* 1996;7:485-9.
9. Basaldella L, Marton E, Bekelis K, et al. Spontaneous resolution of atraumatic intrauterine ping-pong fractures in newborns delivered by cesarean section. *J Child Neurol* 2011;26:1449-51.
10. Loire M, Barat M, Mangyanda Kinkembo L, Lenhardt F, M'buila C. Spontaneous ping-pong parietal fracture in a newborn. *Arch Dis Child Fetal Neonatal Ed.* 2017;102: F160-1.
11. Ben-Ari Y, Merlob P, Hirsch M, et al. Congenital depression of the neonatal skull. *Eur J Obstet Gynecol Reprod Biol* 1986;22: 249-55.