

LETTER TO EDITOR (VIEWERS CHOICE)

DENGUE OR HEPATITIS A? "WHEN THE ANSWER IS BOTH"Deepika P¹, Sivani D K¹, Prabhuraj A², Suresh Kannan K³, Suresh Kannan K³.¹Junior Resident, Department of Pediatrics, Govt. Mohan Kumaramangalam Medical College, Salem,²Asst Professor, Department of Pediatrics, Govt. Mohan Kumaramangalam Medical College, Salem,³Professor, Department of Pediatrics, Govt. Mohan Kumaramangalam Medical College, Salem.**KEYWORDS**

Coinfection, Pleural effusion, Fever.

ARTICLE HISTORY

Received

Accepted

Viral infections, common in tropical countries, can coinfect a child and pose challenges for the treating clinician. Dengue fever is a vector-borne disease transmitted by the *Aedes aegypti* mosquito and is a common cause of acute febrile illness in children.¹ Hepatitis A virus is a water-borne pathogen that is also common in children. Both diseases are endemic in India and can coinfect a child.² These coinfections often lead to clinical confusion because the signs and symptoms overlap. In a study by RK Jain et al., coinfection with Dengue and Hepatitis A was observed in 22 children.³ Dengue fever usually presents with fever, thrombocytopenia, bleeding, hemoconcentration, capillary leak, third-space fluid loss, and a mild to moderate rise in liver enzymes.¹ Jaundice, though less common, can occur in dengue fever and mimic viral hepatitis. Viral hepatitis usually begins with a prodrome of vomiting, fever, and diarrhoea, and the rise in liver enzymes is more than 10 to 15 times the normal. The clinical pointers to coinfection include prolonged fever, highly elevated liver enzymes, and the absence of hemoconcentration/thrombocytopenia.⁴

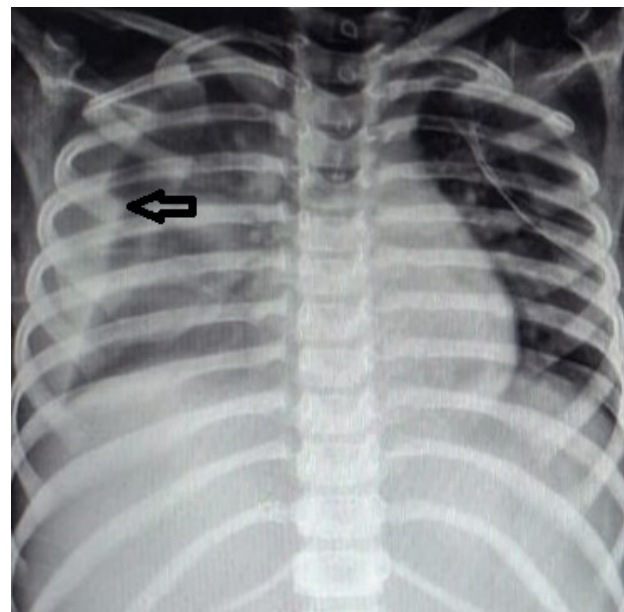
We report one such instance in an eight-year-old girl who was admitted with a 5-day history of fever and abdominal pain, and a 3-day history of vomiting. She also had a history of passing dark urine. On admission, she had compensated shock and was treated with two intravenous boluses of normal saline. On examination, she was febrile (38.5 °C) and had tender hepatomegaly. Examination of other systems was normal. Her Liver Function Tests (LFT) were deranged – increased total bilirubin, direct bilirubin, Serum Glutamic-Oxaloacetic Transaminase (SGOT), Serum Glutamic-Pyruvic Transaminase (SGPT), and serum Alkaline Phosphatase (SAP) were observed. Complete Blood Counts (CBC) showed leucopenia and a normal platelet count on day 1. Serial blood counts and LFT during her hospital stay are shown in Table 1.

Serum IgM anti-Hepatitis A Virus was positive, and other viral hepatitis markers were negative. On day 3 of hospitalization, the girl developed periorbital puffiness, abdominal distension, and reduced air entry over

Table 1: Serial laboratory parameters

Tests	Day 1	Day 3	Day 5	Day 7	Day 9	Day 13
Total WBC count (per cu.mm)	3,700	3,100	8,000	4,900	2,900	4,600
Platelet count (per cu.mm)	1,89,000	77,000	1,20,000	1,70,000	3,12,000	3,89,000
Hb (gms%)	10.4	10.1	9.9	9.4	9.6	10.5
PCV (%)	35.3 %	29.9 %	35.2 %	31.1 %	31.5 %	33.1
SGOT (IU/ml)	137	3480	100	125	90	90
SGPT (IU/ml)	142	2390	241	441	295	140
Total Bilirubin (mg%)	2.5	3.3	4.0	4.9	3.9	1.8

SGOT: Serum Glutamic-Oxaloacetic Transaminase, **SGPT:** Serum Glutamic-Pyruvic Transaminase.

Fig 1: Chest radiograph of the patient

Pleural effusion (Arrow)

Address for Correspondance: K.S.Kumaravel, M.D (Paediatrics), 191A, Shankar Nagar, Salem, Tamil Nadu, India. PIN: 636 007.

Email: kumaravelks@rediffmail.com

©2026 Pediatric Oncall



the lung fields. The chest X-ray showed a right-sided pleural effusion (Fig. 1). Ultrasound abdomen revealed gallbladder wall edema, moderate ascites, and a right-sided pleural effusion. Persistent leukopenia, along with clinical signs of third-space fluid loss, prompted us to consider dengue fever as a differential diagnosis, and a positive anti-Dengue IgM antibody confirmed the diagnosis. In view of increased work of breathing, the child required non-invasive ventilatory support for 3 days. Supportive and symptomatic management was provided for the next 6 days. The girl continued to have a fever until day 12. Her coagulation profile was normal, and she did not manifest any bleeding manifestations throughout the stay. She was also hemodynamically stable throughout her stay. Defervescence was achieved on day 13, with improvement in liver function test values. She was discharged on day 15. This case underlines the need for physicians to understand the typical presentations of these diseases and to consider the possibility of coinfections in atypical presentations.

Compliance with Ethical Standards**Funding:** None**Conflict of Interest:** None**References:**

1. Vagha K, Uke P, Varma A, Javvaji CK, Malik A, Murhekar S, Varma Sr A. Concurrently affected by Dengue and Hepatitis A: exploring the intricacies of co-infection in a Comprehensive Case Series. *Cureus*. 2024 Jun 6;16(6).
2. Das MN, Sharma S. Dual Viral Assault: Unraveling the Complexities of Dengue and Hepatitis E Co-Infection in a Tropical Setting. *Journal of Rehabilitation Research Current Updates*. 2025 Jun 16;1(1):1-3.
3. Jain RK, Shrivastava R, Kapoor G, Chaurasia D, Ahirwar KK, Agarwal A. Co-infection of dengue and hepatitis A virus among pediatric population: A study from a tertiary care center in central India during 2022–2023. *Journal of Vector Borne Diseases*. 2025 Jul 1;62(3):332-7.
4. Shah I & Dey A: Hepatitis A and dengue coinfection. *J Vector Borne Dis*. 2015, 52:265-6.