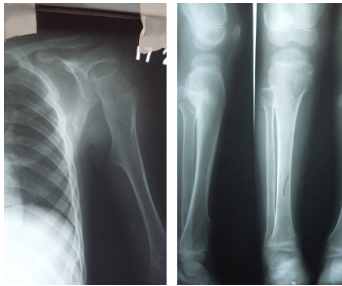


SPOT DIAGNOSIS (IMAGE GALLERY)



BONE SWELLINGS

Altaf Naseem, Sindhu Somireddy

Department of Pediatrics, Department of Radiology, Deccan College of Medical Sciences, Hyderabad, India.

Address for Correspondence: Dr. Altaf Naseem, Associate Professor, Department of Pediatrics, Princess Esra Hospital, Shah Ali Banda, Hyderabad - 500002, Andhra Pradesh. India.
Email ID: docaltaf@rediffmail.com

A six years old male child born of nonconsanguinous marriage presented with multiple swellings over the body, pain and short stature. There was no history of similar complaints in other family members. On examination his general condition and vitals were stable. His height was less than 3rd percentile. There were multiple swellings over proximal and distal end of long bones. His systemic examination was normal. X-rays are depicted above.

What is the diagnosis?

Radiological examination revealed multiple osteochondromas around the knee at the pelvis and humerus suggestive of multiple exostoses. Hereditary multiple exostoses {HME} is a rare medical condition in which multiple bony spurs or lumps develop on the bones of a child. HME is estimated to occur in 1 in 50000 people {1}. HME is an autosomal dominant hereditary disorder. Approximately 10 to 20 percent of individuals with HME have the condition as a result of spontaneous mutation and are thus the first person in their family to be affected {2}. HME begins to manifest in childhood and currently has no cure {3}. It is characterized by the growth of cartilage capped benign bone tumors around areas of active bone growth, particularly the metaphysis of long bones. Depending on location they can cause pain or numbness from nerve compression, vascular compromise, inequality of limb length {4,5}. HME has an increased risk of developing a rare form of bone cancer called chondrosarcoma as an adult {1,3}. Surgery, physiotherapy and pain management are currently the only option available. It is not uncommon for HME patients to undergo numerous surgical procedures throughout their lives to remove painful or deforming exostoses, correct limb length discrepancies or to improve range of motion.

Contributors: AN collected the data and drafted the article and revised the manuscript for important intellectual content. He will act as guarantor of the study. SS helped in manuscript writing.

Funding: nil

Competing interests: nil

References

1. Black B, Dooley J, Pyper A, Reed M. Multiple hereditary exostoses. An epidemiologic study of an isolated community in Manitoba. Clin Orthop 1993; 287: 212-217
2. Cook A, Raskind W, Blanton SH, et al. Genetic heterogeneity in families with hereditary multiple exostoses. Am J Hum Genet. 1993; 53: 71-79
3. Schmale GA, Conrad EU 3rd, Raskind WH. The natural history of hereditary multiple exostoses. J Bone Joint Surg Am. 1994; 76: 986-992
4. Shapiro F, Simon S, Glimcher MJ. Hereditary multiple exostoses. Anthropometric, roentgenographic, and clinical aspects. J Bone Joint Surg Am. 1979; 61: 815-824
5. Vasseur MA, Fabre O. Vascular complications of osteochondromas. J Vasc Surg. 2000; 31: 532-538

E-published: February 2011 . **Art#11**