

## SPOT DIAGNOSIS (IMAGE GALLERY)

Figure 1: At presentation on Day 1 of life

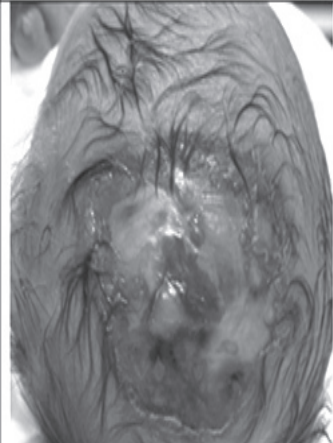
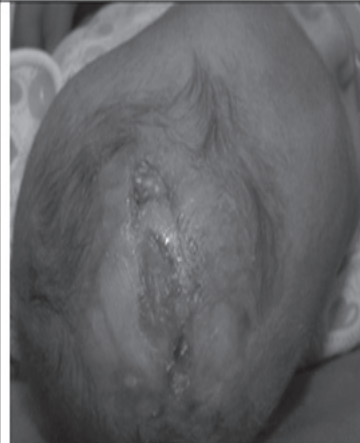


Figure 2: On follow up at 2 months of age



### SCALP DEFECT

**Albahri Z\*, Krylová K\*, Al Mawiri A\*\*, Bartonová J\*\*\*, Štefácková Š\*\*\*\*, Docekalová Š #**

*\*Department of Pediatrics, \*\*Internal Medicine, \*\*\*Pediatric Dermatology, \*\*\*\*Neurology, #Pediatric Surgery, Faculty hospital, Charles University in Hradec Králové, Czech Republic.*

**Address for Correspondence:** Ziad Albahri, MD, PhD, Department of Pediatrics, Faculty hospital, Charles University in Hradec Králové, Sokolská 581, 500 05 Hradec Králové, Czech Republic. Email: marziadmar@seznam.cz

A full term male newborn, born by normal delivery after an uncomplicated pregnancy presented with extensive tissue defect of the scalp (measuring 8 x 9cm) and large underlying bony defect, the affected area consisted of a membranous and crusts cover over the entire posterior-parietal region (Figure 1). He showed no signs of acute distress or neurological impairment. MRI of brain revealed no abnormalities. There were no other organ abnormalities. Routine laboratory data, infection, metabolic and hematological laboratory panels were normal. Karyotype was 46XY. Affected area was treated conservatively [gentle cleansing of the denuded area with saline-antibiotic-impregnated non-adherent dressing (dermacyn) to promote healing in a moist environment]. The dressing was changed every 3-4 days for two months, after that he was discharged home with ambulatory follow-up ( Figure 2).

### What is the diagnosis?

Aplasia cutis congenita (ACC). It is a rare disease of unknown etiology, usually affects the scalp (up to 84 percent), but any part of the body may be affected, most commonly presents as a solitary defect, can have variable extent ranging from 0.5 to 10 cm or more. It is reported that only 15 to 20 percent of cases of scalp ACC are associated with an underlying bony defect. (1) ACC affecting large portions of the scalp (>3x5cm) are very rare. In the cases of extensive scalp ACC, it was reported that 75 percent had skull defects. CNS malformations with ACC are rare. Non-scalp lesions may involve the trunk and, or extremities, and may be associated with epidermolysis bullosa or other congenital anomalies. (2) Complications of large scalp ACC with bony defect include sagittal sinus hemorrhage or thrombosis, site infection or meningitis. Mortality has been estimated to be as high as 25 to 55 percent. Clinical manifestation of intractable seizures and developmental delay are reported. (3) Our patient presented with an extensive area of scalp ACC large underlying bone defect without CNS malformation. No family history of similar condition and no history of medications (alcohol or drugs) or disease during pregnancy could be elicited in our patient. The patient's skin and bone defects were treated with conservative dressing, with gradual epithelialization, no complications of infection or thrombosis were noted. By 1.5 year of age, the area of ACC was well-healed and the underlying parietal bone partially ossified. Clinical examination at 18 months revealed normal growth and development, neurologically, the infant had no obvious deficit. Most lesions of ACC heal spontaneously with conservative dressing, small areas of ACC usually heal well with alopecic scars and with no residual problems, but large lesions may necessitate surgical interference with skin grafts or local skin flaps. (4)

### References

1. Burkhead A, Poindexter G, Morrell DS. A case of extensive Aplasia Cutis Congenita with underlying skull defect and central nervous system malformation: discussion of large skin defects, complications, treatment and outcome. *J Perinatol.* 2009;29:582-584
2. Evers ME, Steijlen PM, Hamel BC. Aplasia cutis congenita and associated disorders: an update. *Clin Genet* 1995;47: 295-301.
3. Maillet-Declerck M, Vinchon M, Guerreschi P, Pasquesoone L, Dhellemmes P, Duquennoy-Martinot V, et al. Aplasia cutis congenita: review of 29 cases and proposal of a therapeutic strategy. *Eur J Pediatr Surg.* 2013;23:89-93
4. Blunk K, Quan V, Carr C. Aplasia cutis congenita: a clinical review and associated defects. *Neonatal Network.* 1992;11:17-27.

**E-published:** July-September2015 **DOI No. :** 110.7199/ped.oncall.2015.42

