

CASE REPORTS

NEONATAL EMPYEMA THORACIS

Seema Sharma, Ajay Sharma, Milap Sharma, Saugat Ghosh

Abstract

There are very few cases of neonatal empyema described in medical literature. There is no standard treatment protocol currently available. We report 3 neonates with late onset sepsis and thoracic empyema. Two had one sided and one had bilateral thoracic empyema. All 3 of them grew staphylococcus aureus on culture. All the three neonates required initial chest tube drainage along with administration of antibiotics. They responded to the treatment.

Keywords : Antibiotics, Empyema, Neonate, Pneumonia

Introduction

Empyema is defined as pus in the pleural space. It is typically a complication of pneumonia. However, it can also arise from penetrating chest trauma, esophageal rupture, complication from lung surgery, or inoculation of the pleural cavity after thoracentesis or chest tube placement. An empyema can also occur from a sub-diaphragmatic or paravertebral abscess via an extension. It is seen frequently in children but is less common in neonates. (1) Various modalities of treatment from intravenous antibiotics, chest tube

drainage, intra-pleural fibrinolytic agent instillation, video-assisted thoracostomy (VAT) to surgical decortication have been suggested to treat different stages of empyema in children, but management of progressive empyema in neonates is still at the stage of antimicrobial therapy and tube thoracostomy. (2) We present three neonates with empyema thoracis.

Case Report

Three term, appropriate for gestational age neonates were admitted with signs of respiratory distress in the neonatal intensive care unit at 13, 6 and 14 days of life respectively. The clinical characteristics are given in Table 1. The clinical impression was pleural effusion with late onset neonatal septicaemia. X-ray chest and ultrasound of thorax were suggestive of pleural effusion unilaterally in two patients (Figure 1) and bilateral in one patient. Diagnostic pleural tap was suggestive of empyema thoracis. All the three patients were started on antibiotic therapy at the time of admission and continued for 3 weeks. Thoracentesis was performed in all the patients. They received mechanical ventilation for 7-10 days. The hospital stay was from 3-4 weeks (Table 1). All of them responded to therapy and were discharged.

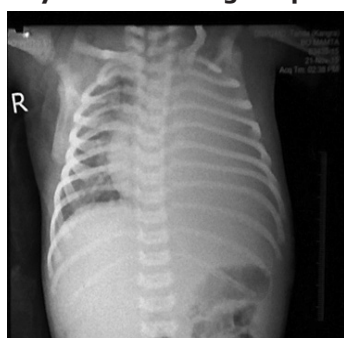
Table 1- Patients Characteristics

SR NO	Patient Characteristics	CASE 1	CASE 2	CASE 3
[A]	History			
1	Age (days)	13	6	14
2	Fever	Yes	Yes	No
3	Lethargy	Yes	Yes	Yes
4	Poor feeding	Yes	No	Yes
5	Premature rupture of membranes duration (days)	18	24	16
6	Period of gestation (Weeks)	41 + 2 days	36	39 + 3 days
7	Maternal fever	No	No	No
8	Mode of delivery	Vaginal delivery	Emergency LSCS in view of acute fetal distress	Vaginal delivery
9	Birth asphyxia	No	No	No
10	Birth weight (kg)	2.75	3.475	3.6
[B]	Clinical Characteristics on presentation			
1	Heart rate (Minute)	154	180	168
2	Temperature	Afebrile	104o F	Afebrile
3	Respiratory rate (Minute)	84	66	86
4	SpO2 at room air	76%	85%	87%
5	SpO2 with oxygen	92%	93%	99%
6	Subcostal /intercostal recession	Yes	No	Yes
7	Stridor	No	No	Yes

SR NO	Patient Characteristics	CASE 1	CASE 2	CASE 3
8	Respiratory System	Absent air entry(left) with dull note on percussion	Absent air entry in right infra-axillary, infra-mammary area with dull note on percussion	Absent air entry in lower lung fields bilateral with dull note on percussion
9	Other systems	Normal	Normal	Normal
[C]	Laboratory parameters			
	Hemogram			
	Hemoglobin (gm/dl)	15.9	16	16.4
	White cell count (cells/cumm)	18,900	26,500	16,900
	Polymorph (%)	66	76	88
	Platelet count (cells/cumm)	1,25,000	75,000	114,000
	C-reactive protein (mg/dl)	>48	<6	Between 6-12
	Pleural fluid			
	Gross appearance	Turbid	Turbid	Turbid
	White cell count (cells/cumm)	97,600	192000	84,300
	Polymorph (%)	94	92	87
	Protein (gm/dl)	4.2	3.7	4
	Sugar (mg/dl)	2.8	2	2.4
	Gram stain	Negative	Negative	Negative
	Culture	No growth	<i>Staphylococcus aureus</i>	<i>Staphylococcus aureus</i>
	Endotracheal tube culture	<i>Staphylococcus aureus</i>	No growth	<i>Citrobacter spp</i>
	Blood culture	Sterile	Sterile	Sterile
[D]	Treatment			
	Antibiotics	Vancomycin-21 days Meropenem-14 days Ciprofloxacin-10 days	Vancomycin-21 days Cefotaxime-21 days	Vancomycin-21 days Meropenem-14 days Ciprofloxacin-10 days
	Duration of hospital stay	23 days	27 days	23 days

Note: LSCS =Lower segment caesarean section, SpO2 = Saturation of oxygen

Figure 1-X-ray Chest showing left pleural effusion



Discussion

There is an increased risk of parapneumonic empyema with extremes of age with rates of 7.6 and 9.9 cases per 100,000 for ages younger than 5 years and older than 64 years, respectively. Most pediatric patients with empyema are less than two years of age; however, fortunately neonatal pleural empyema is rare. (3) Empyema is more common in the poor socioeconomic group. The incidence peaks between 0-3 years of age. (4) It has variable predisposing factors, uncertain pathogenesis, rapid course, high mortality and there is lack of management protocol in neonates. The pathogens isolated from children

with pleural empyema are Hemophilus influenzae, Streptococcus pneumoniae, Staphylococcus aureus, Bacteroides species and other anaerobes. (5) All our patients had infection with S. aureus, which is one of the most common community acquired bacterial pathogens resulting into empyema infection.

The clinical signs may be limited in the newborn period; therefore, the typical stony dull percussion note observed in older children may be absent in the newborn. (6) All our patients had a dull note on percussion.

Key for the successful management lies in two basic principles, one is to start effective antibiotic therapy for 3-6 weeks duration along with effective pleural evacuation (for up to 1 week/ till tube thoracostomy yield is less than 50 ml of fluid per day) and the other is re-expansion of lungs. (7) Antibiotic should be continued until patient is afebrile, white cell count is normal and radiograph show consider-able clearing. Normally, H. influenzae and S. pneumoniae need 7-14 days course of antibiotics while S. aureus needs 3-4 weeks. (8) Other modalities that can be used are intrapleural fibrinolytics and video assisted thoracoscopic surgery (VATS). The management of complicated parapneumonic effusions by conventional first-line treatment with closed intercostal tube drainage and antibiotic therapy may fail because of thick viscous fluid and multiple pleural space loculations. Intra-pleural fibrinolytic treatment is a non-invasive therapeutic option that avoids surgical intervention, although its use in neonates has not been studied extensively. Successful outcome have been reported following the use of fibrinolytics in neonates. (8) VATS can be a safe and effective treatment option for neonatal empyema. (9) All our patients responded to intercostal tube drainage and IV antibiotics.

Conclusion

Neonatal empyema thoracis is rare and most patients have S. aureus infection. Treatment with intercostal tube drainage with antibiotics is successful in these patients though a standard protocol with other treatment modalities needs to be established.

Funding: None

Conflict of Interest : None

References :

1. Mazumdar J, Sen S. Neonatal Empyema Thoracis. J Nepal Paediatr Soc 2014; 34(1):65-67.
2. Kaiser JR, Shrager JB. Video assisted thoracic surgery: The current state of the art. Am J Roentgenol 1995; 165: 1111-1117.
3. Freij BJ, Kusmiesz H, Nelson JD, McCracken GH. Parapneumonic effusions and empyema in hospitalized children: a retrospective review of 227 cases. Pediatr Infect Dis 1984;3:578-91.
4. Mangete EDO, Kombo BB, Legg-Jack TE. Thoracic empyema: A study of 56 patients. Arch Dis child 1993; 69: 587-588.
5. Brusck JL, Weinstein L. Pleural empyemas. In: Feigin RD, Cherry JD, eds. Paediatric Infectious Diseases, 3rd edn. Philadelphia. WB Saunders. 1992:315-20.
6. Jain SN, Banavaliker J. Bacteriological analysis of pleural fluid from the largest chest hospital in Delhi. J Empyema Thoracis. 2013;3:6-10.
7. Winter RH. Non-malignant pleural effusion. In: Fishman FA (eds). Fishman's Pulmonary Diseases and Dis-orders. 3rd edn. New York. McGraw Hill. 1998: 1411-1428.
8. Cha LMJ, Choi S, Kim T, Yoon SW. Intrapleural urokinase therapy in a neonate with pleural empyema. Pediatrics International. 2016; 58: 616-619.
9. Leung C, Chang YC. Video-assisted thoracoscopic surgery in a 1-month-old infant with pleural empyema. J Formos Med Assoc. 2006;105: 936-40.

From: Department of Pediatrics, Dr Rajendra Prasad Government Medical College, Himachal Pradesh, India.

Address for Correspondence:

Dr Seema Sharma, House no 23, Block-B, Type-V, Dr Rajendra Prasad Government Medical College, Kangra at Tanda, Himachal Pradesh, India.



Email : seema406@rediffmail.com

DOI : 10.7199/ped.oncall.2018.2
