

LETTER TO EDITOR (VIEWERS CHOICE)

LITTRE'S HERNIA-MECKEL'S DIVERTICULUM STRANGULATED IN AN UMBILICAL HERNIA

Nihil Edavana Lohidakshan¹, Sruthi Alanghat¹, Guruswamy Rajamani².

¹Department of paediatrics, Masonic Medical Centre for Children, Coimbatore, Tamil Nadu,

²Department of paediatric surgery, Masonic Medical Centre For Children, Coimbatore, Tamilnadu.

KEYWORDS

Littre's hernia, Meckel's diverticulum, Umbilical hernia

ARTICLE HISTORY

Received 9 September 2021

Accepted 27 November 2021

A 3 months 17 days old infant boy came to our emergency room with complaints of painful umbilical swelling of 1 day duration. On examination, there was an induration of 5 cm around the umbilicus which was warm and tender with a shiny skin over the swelling. However, his vitals were stable and the rest of systemic examination was unremarkable. On investigation blood counts, CRP, serum electrolytes were all normal. USG abdomen was suggestive of strangulated umbilical hernia (UH) with probable small bowel necrosis. Laparoscopically, the content of umbilical hernial sac was pulled down and noted to have Meckel's diverticulum (MD) (Figure 1, 2) located 10 cm from anti-mesenteric border of terminal ileum. The base was 2 cm wide and 1 cm long and it was completely gangrenous throughout its length (Figure 3). Laparotomy through a sub-umbilical incision was done, the MD was resected and end-to-end anastomosis

(Figure 4) was done followed by umbilicoplasty. The postoperative period was uneventful and child was discharged after seven days.

Figure 1.

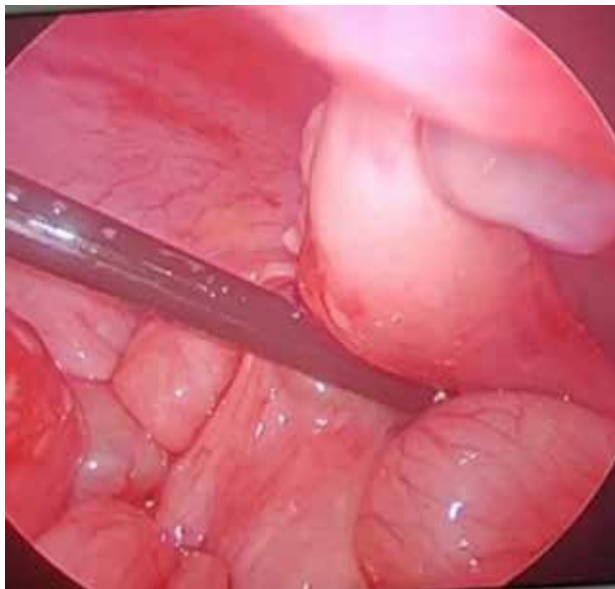


Figure 2.

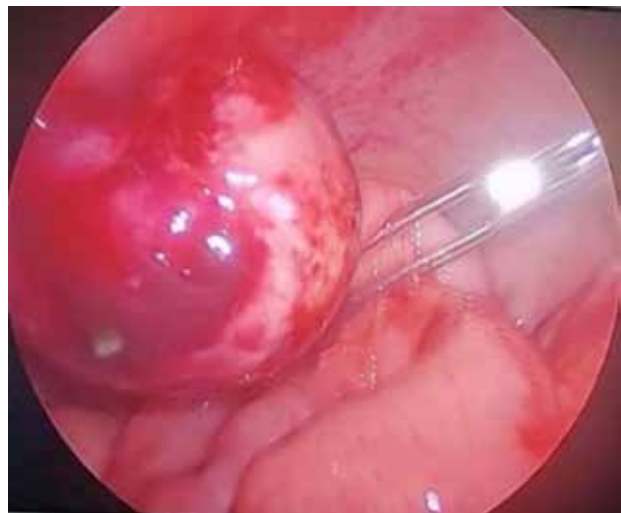
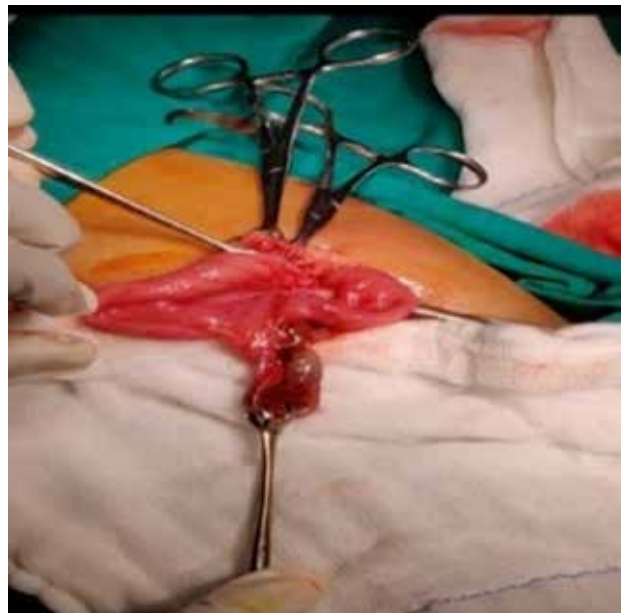


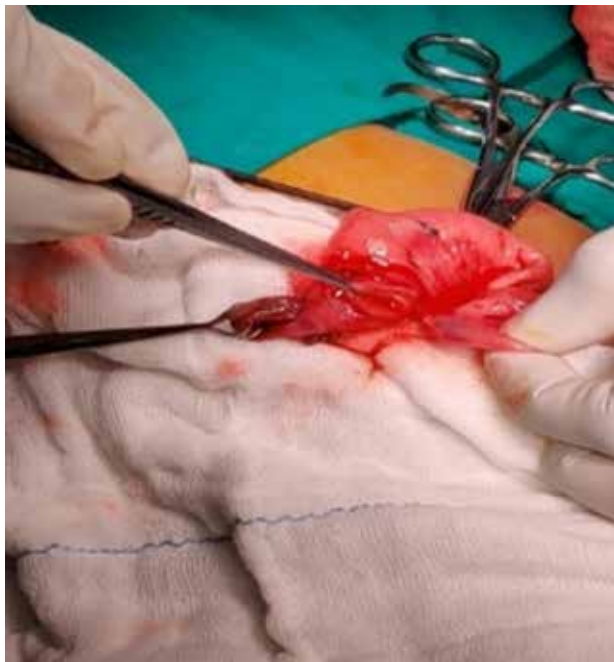Figure 3.



Address for Correspondance: Dr. Sruthi Alanghat,
Department of Pediatrics, Masonic Medical Centre For
Children, Coimbatore, Tamil Nadu, INDIA

Email: sruthialanghat@gmail.com

©2021 Pediatric Oncall

Figure 4.

Littre's hernia (LH) is the protrusion of MD through a potential abdominal opening with a container sac.¹ The common site being inguinal and rarely umbilical.² MD is a remnant of persistent vitello-

intestinal duct or omphalomesenteric duct which is seen in the antimesenteric border and is the most common congenital abnormality of the gastrointestinal tract. The clinical presentation of MD includes hemorrhage, obstruction, diverticulitis, intussusception or perforation. Congenital UH is due to an incomplete closure of the umbilical ring or due to the weakness of the fascia around the ring leading to the protrusion of the abdominal viscera.³ Very often, umbilical hernia closes spontaneously in the first three to four years of life; thus, they are rarely operated.

The strangulation of umbilical hernia is rare & strangulation of a MD in an UH is even rarer.

Preoperative diagnosis of Littre's hernia and its clinical differentiation from other forms of hernia are still almost impossible. We hereby report a case of strangulated MD contained in an UH.

Compliance with Ethical Standards

Funding: None

Conflict of Interest: None

References:

1. Sahoo PK, Rout SS, Littres hernia : a rare complication of meckel's diverticulum. *Int Surg J.*2017;4(4):1481-83.
2. Yagmur Y, Akbulut S, Can MA. Gastrointestinal perforation due to incarcerated Meckel's diverticulum in right femoral canal. *World J Clin cases.* 2014;2(6)232-4.
3. Marinković S, Bukarica S. Umbilical hernia in children. *Med Pregl* 2003;56:291-4.