

LETTER TO EDITOR (VIEWERS CHOICE)

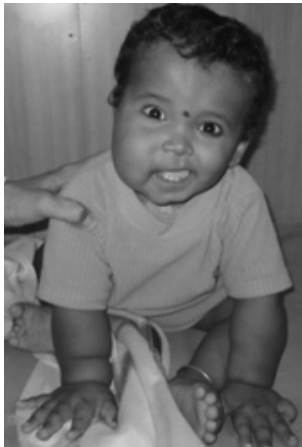**MEGALENCEPHALY-CAPILLARY MALFORMATION SYNDROME**

*Prashant Nigwekar, Santosh Yadav, Col. D Y Shrikhande, B Bora*

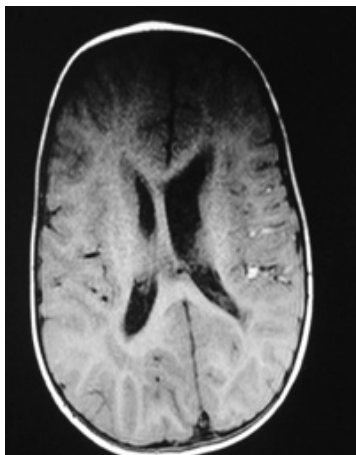
**Keywords:** Over growth syndromes, M-CM.

A 1 year old male child presented with complaints of overgrowth on right side of face, right upper and lower limbs since birth and delayed milestones. Examination showed macrocephaly, frontal bossing and right side hemihypertrophy, macrodactyly of the right great toe and syndactyly of 2nd and 3rd toes. (figure 1) Generalized hypotonia was noted. MRI of whole body and brain (figure 2) revealed asymmetry between right and left side of body. This included hypertrophy of the cranium, brain, facial, tongue, limbs and entire half of the body on right side. There was mild ventriculomegaly on left side with persistent cavum septum pellucidum and cavum septum vergae. There was evidence of triangular shape tonsil seen below the level of foramen magnum by about 9mm (normal 6mm) into upper cervical spinal canal. No abnormal arteriovenous malformation or dilated vessels are seen on MRI angiography. As per Martinez-Glez Criteria (1) the diagnosis of Megalencephaly - Capillary Malformation Syndrome was confirmed.

**Figure 1: Right hemihypertrophy seen**



**Figure 2: MRI brain showing left ventriculomegaly with hypertrophy of brain on right side**



Megalencephaly-capillary malformation syndrome (M-CM) was first described in the medical literature in 1997. M-CM was formerly known as macrocephaly-cutis marmorata telangiectatica congenita (M-CMTC). Recently, the name was modified to "megalencephaly-capillary malformation" (M-CM) because the term "macrocephaly" refers to a large head due various causes, whereas "megalencephaly" is a more specific and accurate term as the brain is large. (2) Approximately 140 cases have been reported in world literature, but there are likely many more affected individuals who have been misdiagnosed or have not been published in the medical literature. (3). Only 3 cases have been reported from India. (4) It occurs due to mutation in the PIK3CA gene. (5,6) The clinical diagnosis is based on Martinez-Glez criteria as given in (table 1) with at least 3 major and 2 minor criteria required. (1)

**Table 1: Martinez-Glez Criteria (1)**

Major Criteria	Minor Criteria
Macrocephaly	Developmental delay
Capillary malformation	Midline capillary malformation
Overgrowth/asymmetry	Neonatal hypotonia
Neuroimaging alteration like: <ul style="list-style-type: none"> <li>• Ventriculomegaly</li> <li>• Cavum septum pellucidum or cavum septum vergae,</li> <li>• Cerebellar tonsillar herniation, Cerebral and or cerebellar asymmetry</li> </ul>	<ul style="list-style-type: none"> <li>• Syndactyly/polydactyly</li> <li>• Connective tissue abnormality</li> <li>• Frontal bossing</li> <li>• Hydrocephalus</li> </ul>

Hydrocephalus and cerebellar tonsillar herniation need immediate surgical intervention. Minimally-invasive 4th ventriculostomy may benefit some patients. Skin anomalies if few or small undergo spontaneous remission within the first few years of life. In some patients laser ablation therapy for lesions is helpful.

**Funding :** None

**Conflict of Interest:** None

**References :**

1. Martínez-Glez V, Romanelli V, Mori MA, Gracia R, Segovia M, González-Meneses A, et al. Macrocephaly-capillary malformation: Analysis of 13 patients and review of the diagnostic criteria. *Am J Med Genet A*. 2010; 152A: 3101-3106
2. NORD. Megalencephaly-Capillary Malformation. Available at URL: <http://www.rarediseases.org/rare-disease-information/rare-diseases/byID/1166/viewFullReport>. Accessed on 27th March 2014
3. M-CM network. Available at URL: <https://www.m-cm.net/>. Accessed on 27th March 2014
4. Panigrahi I, Bhushan M, Yadav M, Khandelwal N, Singhi P. Macrocephaly-capillary malformation syndrome: three new cases. *J Neurol Sci*. 2012;313:178-181
5. Rivière JB, Mirzaa GM, O'Roak BJ, Beddaoui M, Alcantara D, Conway RL, et al. De novo germline and postzygotic mutations in AKT3, PIK3R2 and PIK3CA cause a spectrum of related megalencephaly syndromes. *Nat Genet*. 2012; 44: 934-940
6. Mirzaa GM, Rivière JB, Dobyns WB. Megalencephaly syndromes and activating mutations in the PI3K-AKT pathway: MPPH and MCAP. *Am J Med Genet C Semin Med Genet*. 2013; 163C: 122-130

---

**From:** Department of Pediatrics, Rural Medical College, Pravara Institute of Medical Science, Loni, India.

**Address for Correspondence:** Dr Prashant Nigwekar, Department of Pediatrics, Rural Medical College, Pravara Institute of Medical Science, Loni-413736, India.

**Email :** [nprashant59@gmail.com](mailto:nprashant59@gmail.com)

**DOI :** 10.7199/ped.oncall.2014.40



---

Quick Response Code