
CASE REPORTS

ANEURYSM OF PERSISTENT RIGHT VITELLINE VEIN IN A CASE OF OMPHALOCELE

Sunita Tibrewala, Mayur Vira, Hemant Deshmukh

Abstract

Embryology of inferior vena cava (IVC) is a complex developmental process and occurs from numerous vascular structures. Numerous anomalies of IVC are known due to deviation in this developmental process. We note an additional anomaly to those previously reported in a seven month old infant. He was detected to have omphalocele at birth and was referred for cardiac CT in view of a thoracic vascular mass which was detected on echocardiography. On CT, a large dilated vascular structure was noted lying retro-sternally, postero-superior to the liver which was continuous with the supradiaphragmatic portion of the IVC and was a remnant of the right supra-hepatic channel which develops from the right vitelline vein. Report of such a structure has not been previously reported and hence adds to our knowledge of IVC malformations.

Keywords: inferior vena cava anomalies, omphalocele associations, persistent right vitelline vein.

Introduction

The inferior vena cava (IVC) is the main conduit of venous return to the right atrium from the lower extremities and abdominal viscera. It is often an overlooked structure at abdominal imaging.

It is associated with a wide variety of congenital and pathologic processes and can be a source of vital information for referring clinicians. (1) The embryogenesis of the IVC is a complex process involving the formation of several anastomoses between three paired embryonic veins. The result is numerous variations in the basic venous plan of the abdomen and pelvis. (2) Initial evaluation of the IVC is most likely to occur at computed tomography performed for another indication. (1) Since the development of cross-sectional imaging, congenital anomalies of the IVC and its tributaries have become more frequently encountered in patients. (2)

Patients having omphaloceles are screened by echocardiography for associated cardiac anomalies of which atrial septal defect (ASD) is the commonest. (3) They rarely present for CT. However, in our patient, an usual vascular structure was seen on echocardiography, which was believed to be of cardiac origin. Ultrasound (USG) thorax, was not able to detect it because of the immediate retro-sternal location. Hence, this patient with omphalocele, was sent for CT and the mass was detected to be an aneurysm of Persistent Right Vitelline Vein.

Case Report

A 7 month old infant was detected to have omphalocele at birth (Figure 1). He was referred for

cardiac CT in view of a probable thoracic vascular mass arising from heart when screened by echocardiography for an associated cardiac anomaly. USG of the thorax did not show the vascular lesion. Contrast CT scan was performed on a 64 slice Philips multidetector CT scanner, after giving intravenous contrast and sedation. On CT an omphalocele was noted with the liver as its content. Liver was rotated in superoinferior direction with caudate lobe seen postero-superiorly. A large dilated vascular channel was noted lying postero-superior to the liver with a blind lower end. Superiorly, it passed retro-sternally through the diaphragm, to enter into the right atrium. It measured 36 mm in length and 21.6 x 17.4 mm in cross section, till its entry into the right atrium (Figure 2). The three hepatic veins were seen joining to form a common hepatic vein which entered this structure anteriorly and infra-diaphragmatically. The infrahepatic portion of the IVC was seen entering this vascular structure posteriorly, inferior to the diaphragm (Figure 3). IVC measured 5 mm proximally with a mild constriction seen at its entry into this vascular structure. This structure was seen to continue through the diaphragm as the supra-diaphragmatic IVC and entered the right atrium. Superior vena cava was normal. Portal venous system was unremarkable. The heart was shifted to left and apex was rotated posteriorly in order to accommodate the anterior location of the IVC into the right atrium. Partial collapse of the left lung was noted. Kidneys were seen lying high postero-superiorly, below the diaphragm. Aneurysm of the right vitelline vein remnant (hepato-cardiac channel) was concluded from above imaging findings.

Figure 1: Seven month old infant with omphalocele.

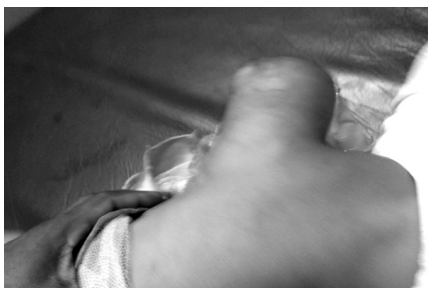

Figure 2: A large dilated vascular channel noted lying postero-superior to the liver, extending retro-sternally for a length of approx. 36 mm.

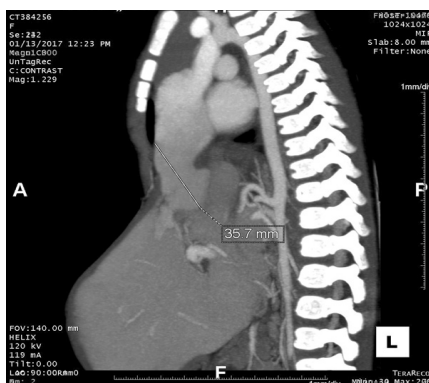
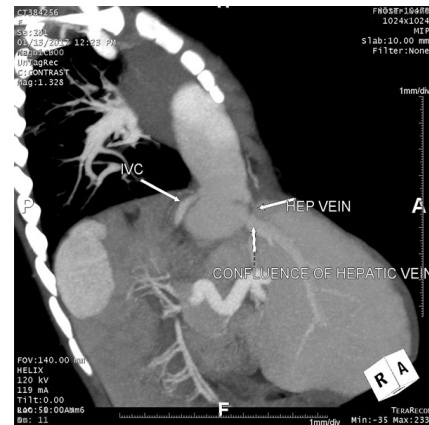


Figure 3: The common hepatic vein and infra-hepatic inferior vena cava (IVC) are seen entering this vascular structure inferior to the diaphragm. Portal vein is unremarkable.



Discussion

At 4 weeks of life, 3 distinct paired venous channels form. The vitelline system drains the gut, the umbilical system drains the placenta, and the cardinal system drains the rest of the embryo. (4) With the development of liver in the septum transversum, the proximal parts of vitelline and umbilical veins become broken up to form sinusoids. These sinusoids drain into the sinus venosus, through the persisting terminal parts of the vitelline veins that are now called the right and left hepatocardiac channels. The left horn of the sinus venosus undergoes regression and as result the left hepatocardiac channel disappears. All blood from the umbilical and vitelline veins now enters the sinus venosus through the right hepatocardiac channel. (5) The suprahepatic IVC, retrohepatic IVC and hepatic veins are derived from the cranial segment of the right hepatocardiac channel. The infrahepatic IVC develops from a set of 3 paired parallel veins appearing consecutively between 4 and 8 weeks of life, namely the posterior cardinal, subcardinal and supra cardinal veins. The renal collar is formed from anastomoses between the supra cardinal veins posteriorly and the subcardinal veins anteriorly. The infrarenal portions disappear on the left but form the infrarenal portion of the IVC on the right. (4) Thus, formation of the IVC involves complex anastomoses and regression of multiple embryonic veins.

There are a number of congenital IVC variants described in literature. To name a few, these include its absence, duplication, left sided IVC, anomalous continuation of IVC, webs and Abernethy malformation (extrahepatic portocaval shunt). (1) Because CT is used to evaluate a wide variety of abdominal symptoms, it is likely to be the most common imaging modality for initial detection of IVC variants and pathologic findings. In our case, the sub-hepatic (pre renal, renal and post renal) segments of IVC, which develop from the subcardinal veins, are normally seen. The hepatic veins that develop from the vitelline veins are also normally

seen, however forming a common hepatic vein, before joining the abnormal vascular channel. Normally the junction between the suprahepatic and retrohepatic portion is seen posterior to the liver. However in our patient, because of abnormal location of development of the liver anteriorly and the kidneys lying high up in a subdiaphragmatic location, this junction was seen lying subdiaphragmatically as well as retro-sternally. Therefore, the remnant of retrohepatic portion of the hepatocardiac channel as well as common hepatic vein are seen persisting. The structure is dilated and is seen continuing as IVC in the thorax. The cardiac apex is rotated posteriorly as the IVC is entering into right atrium retro-sternally. The entire channel is dilated and hence a diagnosis of aneurysm of right hepatocardiac channel was made. Anomalies in the form of interrupted IVC with omphalocele have been described and reported previously. (6) However, no similar abnormality of the cranial segment of right hepatocardiac channel along with aneurysmal dilatation of the same, has been reported in literature till date. This case alerts us to conduct an active search for other anomalies/disorders, in a case of omphalocele.

Conclusion

Anomalies of the IVC are usually by non-invasive imaging techniques like CT and MRI, and these can be misdiagnosed as a mass lesion. (7) Accurate characterization of systemic venous anomalies plays a major role in the appropriate labelling and management. A thorough knowledge of the relevant embryology is the best way to understand these anomalies. Perinatal identification of omphalocele should alert one to the possibility associated vascular anomalies.

Funding : None

Conflict of Interest: None

References :

1. Smillie RP, Shetty M, Boyer AC, Madrazo B, Jafri SZ. Imaging evaluation of the inferior vena cava. *Radiographics*. 2015; 35(2): 578-92.
2. Bass JE, Redwine MD, Kramer LA, Huynh PT, Harris JH Jr. Spectrum of congenital anomalies of the inferior vena cava: cross-sectional imaging findings. *Radiographics*. 2000; 20(3):639-52.
3. Chen CP. Syndromes and disorders associated with omphalocele (III): single gene disorders, neural tube defects, diaphragmatic defects and others. *Taiwan J Obstet Gynecol*. 2007;46(2):111-20.
4. Ghandour A, Partovi S, Karuppasamy K, Rajiah P. Congenital anomalies of the IVC - embryological perspectives and clinical relevance. *Cardiovasc Diagn Ther* 2016;6(6):482-492.
5. Singh I, Pal G P. Cardiovascular System. In: *Human Embryology*. India. Macmillan. 2001. p. 250-262.
6. Mlczech E, Carvalho JS. Interrupted inferior vena cava in fetuses with omphalocele. Case series of fetuses referred for fetal echocardiography and review of the literature. *Early Hum Dev*. 2015;91(1):1-6.
7. Petik B. Inferior vena cava anomalies and variations: imaging and rare clinical findings. *Insights Imaging*. 2015; 6:631-639.

From: Department of Radiology, King Edward Memorial (KEM) Hospital, Mumbai, India.

Address for Correspondence:

Dr Mayur Vira, Dept. of Radiology, King KEM Hospital and Seth Gordhandas Sunderdas Medical College, Acharya Donde Marg, Parel, Mumbai - 400012, Maharashtra, India.



Email : drmayurvira@gmail.com

DOI: 10.7199/ped.oncall.2018.20
