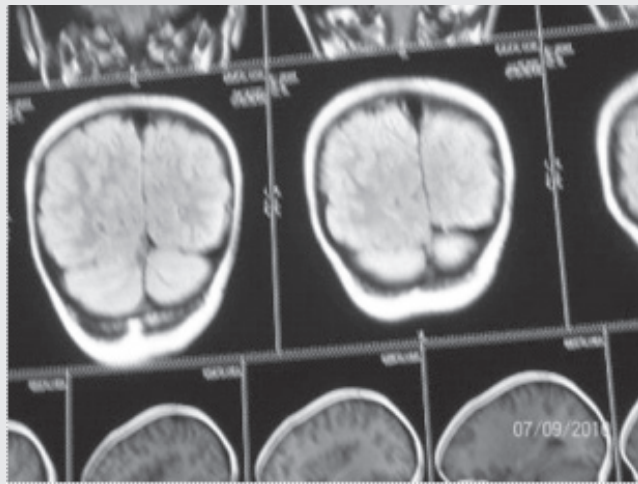


SPOT DIAGNOSIS (IMAGE GALLERY)



LIMB ASYMMETRY

**Gautam Ghosh, Archana Vyas,
Tarun Chowdhury**

*B R Singh Hospital for Medical Education &
Research, Sealdah, Kolkata, India.*

Address for Correspondence: Dr. Gautam Ghosh,
23 Ramesh Mitra Road, Kolkata 700025, West Bengal,
India. Email: gautamghosh1957@yahoo.co.in.

A 7 years old girl born of non-consanguineous marriage presented with painful, non pitting progressive swelling over left thigh and leg along with popliteal cyst for 9 months. She had asymmetric non pitting swelling of right half of face and hand for past 3 years. She had an epidermal nevus on right chest since birth. Development was normal. On anthropometry, her right upper limb circumference was 2 cm more than left side, mid forearm circumference was 1.5 cm

more on right than left, mid thigh circumference was 1 cm more on left than right, and mid leg circumference was 3.5 cm more on left than right. Her right palm and mid face also showed hypertrophy as compared to the left. Systemic examination was normal. Doppler of limbs was normal. Tele- lymphangiography of both hands & legs, karyotype for Turner's Syndrome, mutation in AKT1 kinase for Milroy-Meig's disease were negative. CT brain showed hemi-megalencephaly on right side (figure 1) and whole body bone scan showed mild asymmetric thickening of long bones in right upper limb and left lower limb. CT abdomen was normal. Muscle biopsy from affected lower limb showed the typical histology of unique muscular dysgenesis, where abnormal zones were adjacent to zones of normal muscle formation and did not follow anatomic boundaries, which clinched the diagnosis.

What is the diagnosis?

Proteus syndrome, also known as Wiedemann's syndrome is named after the German pediatrician Hans-Rudolf Wiedemann. (1) It is a disturbance of cellular growth involving ectodermal and mesodermal tissues. (1) The cause is unknown but it is not a mendelian trait. It presents as asymptomatic overgrowth of extremities, verrucous cutaneous lesions, angiomas of various size, thickening of bones, hemimegalencephaly and excessive growth of muscles without weakness. (2) The diagnosis of Proteus syndrome in this patient was made in view of general criteria (mosaic distribution, sporadic occurrence and progressive course) with 2 specific criteria category B- Linear epidermal nevus, asymmetric and disproportionate overgrowth of two of limbs. Patients with Proteus syndrome may have other specific criteria such as category A - cerebriform connective tissue nevus, category B - disproportionate overgrowth of skull, external auditory canal, vertebrae or viscera or specific tumors in the first decade of life or monomorphic parotid adenomas, or Category C - dysregulated adipose tissue or vascular malformations or lung bullae or typical facial phenotype of long face, dolichocephaly, down-slanted palpebral fissures, low nasal bridge, wide or anteverted nares, open mouth at rest. (3) A multi-specialist approach was initiated for follow up and supportive therapy in this patient (orthopaedic follow up for leg length discrepancy, scoliosis and muscle weakness, periodic evaluation of subcutaneous swellings, observation for hematological complications such as thrombocytopenia and thrombosis and periodic follow up for occurrence of lung or brain cysts. Although data are not available at present about long term survival, internal complications may cause early mortality. (3)

References

1. Cohen MM, Hayden PW. Hamartomatous syndrome. In: William J, Timothy B, Dirk E (eds). *Andrews; Diseases of the Skin: Clinical Dermatology*. 10th edn. Philadelphia. Saunders. 2005: 554-555
2. Sarnat HB. Neuromuscular disorders. In: Kleigman RM, Behrman RE, Jewson HB, Stanton BF. (eds) *Nelson's Textbook of Pediatrics*. 18th edn, vol 2. Elsevier. Philadelphia. 2008: 2539.
3. Biesecker L, Happle R, Mulliken J, Weksberg R, Graham J, Viljoen D, Cohen M. Proteus syndrome: differential diagnosis, and patient evaluation. *Am J Med Genet*. 1999; 84: 389-395

E-published: January-March 2015. **DOI No. :** 10.7199/ped.oncall.2015.1

