

CASE REPORTS

AIR GUN BULLET RELATED LUNG INJURY

Ravi Sharma¹, Vijendra Chaturvedi², Neha Jangid², Sunita Ojha³.

¹Department of Pediatrics & Pediatric Critical Care, Santokba Durlabhji Memorial Hospital, Jaipur, Rajasthan, India,

²Department of Pediatrics & Pediatric Critical Care, Santokba Durlabhji Memorial Hospital, Jaipur, Rajasthan, India,

³Department of Pediatric Surgery, Santokba Durlabhji Memorial Hospital, Jaipur, Rajasthan, India.

ABSTRACT

The popularity of air gun is increasing. They are often viewed as toys rather than potentially lethal weapons. A 2-year-old girl child was referred from outside facility for alleged air gun metallic bullet injury chest. The elder sibling, 6-year-old shot towards the girl's left side chest while playing. Patient underwent right thoracoscopic foreign body removal from right upper lobe peripheral part of posterior segment. We conclude that air gun shot injuries should not be considered non-fatal and such air gun should be kept away from reach of children, never to be placed loaded when not in use. The fatality of metallic bullet injury used for air gun depends on angulations at which it is fired and wound path structures.

ARTICLE HISTORY

Received 8 August 2020

Accepted 13 August 2020

KEYWORDS

Air gun shot, pellet, thoracoscopy, accidental, child

Introduction

The popularity of air gun is increasing. They are often viewed as toys rather than potentially lethal weapons.¹ Regulations on purchase and ownership of these weapons differ from country to country. The majority of fatal and non-fatal air gun accidents involve children less than 16 year of age.² We present a young female child who was shot at close range with a low-caliber air rifle accidentally shot at her chest with entry wound and pawn shaped bullet which impacted into the right upper lobe of lung.

Case Report

A 2-year-old girl child was referred from outside facility for alleged airgun metallic bullet injury over the chest. There was an alleged history of accidentally being shot by air gun while playing with her elder sibling. Mother was cleaning the wardrobe containing an old air gun loaded with metallic pawn shaped bullet commonly used for shoeing away wild animals. Gone unnoticed by mother, kids took away the loaded air gun rifle. The elder sibling, 6-year-old shot towards the girl's left side chest while playing. Mother noticed girl had one entry wound sized less than ½ a cm in upper part of left chest looking like an open site for entry of bullet. She took the child to nearby hospital for evaluation. Since the child was asymptomatic, doctor opined that the bullet has not entered the body, it probably made an impact on chest and fell down. Since parents could not recover any bullet from the site, they went to another hospital,

where chest radiographs were done which showed right sided pawn shaped bullet, appearing to be impacted in either the rib or the right lung. Ultrasound (USG) chest could not visualize any foreign body in chest. After radiological observation of the bullet, patient was immediately referred to our center for further management. At admission in our hospital, patient was conscious, hemodynamically stable with marginal decreased air entry in right side chest and had a small ½ cm entry site wound on left side of upper chest. NCCT chest (figure 1) revealed location of bullet in posterior segment of right upper lobe adjoining right 4th rib with surrounding areas of ground glass haze suggesting alveolar hemorrhage. Patient underwent right thoracoscopic foreign body removal from right upper lobe peripheral part of posterior segment. On thoracoscopy, blood collection in apex and mediastinal side of pleura was noted, hematoma was noted in right upper lobe basal area and wound path was visualized. There were no major injury to vessels but right upper lobe contusion was noted. Intercostal drainage ICD was inserted and gradually patient showed improvement with chest physiotherapy. Serial chest radiographs over next 48 hours showed resolution of right lung contusion. Entry wound on skin was managed conservatively with daily use of aseptic antibacterial ointment.

Discussion

Thoracic gunshot injuries are rare in India compared to west, but they are associated with significant morbidity and mortality. Fatal accidents from air weapons are rare, and minor or major bodily injuries, especially eye injuries, occur more often.^{3,4} In most cases, shooting is accidental by a friend, relative, or a self-injury, usually in the absence of adult supervision. Children are the most frequent victims of air gun injuries or fatalities, and the assailant is also most often a child.⁴ In all fatal or non-fatal cases, boys are far more often involved

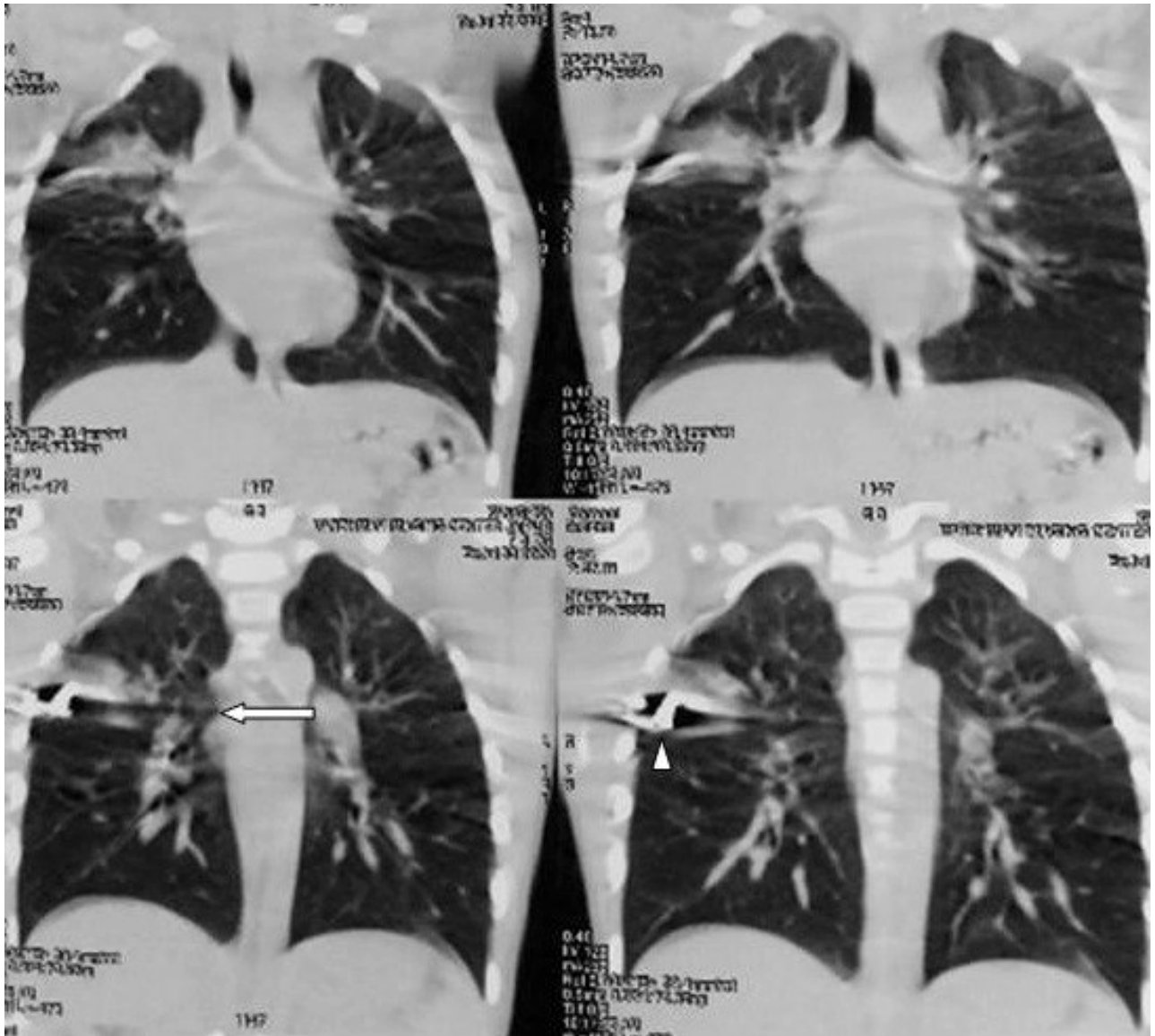
CONTACT Dr Ravi Sharma

Email: dravisharma@gmail.com

Address for Correspondence: Dr Ravi Sharma, 2nd Floor PICU, SDM Hospital, Bhawani Singh Marg, Jaipur-302015, Rajasthan, India.

©2020 Pediatric Oncall

Figure 1. Coronal section in HRCT chest shows impacted bullet (arrowhead) in lower part of upper lobe of right lung and the bullet track (arrow). The bullet track is surrounded by hyaline opacity due to alveolar hemorrhage.



than girls. The victims and assailants are most often aged 10 to 14.^{5,6} According to a review by Di Maio, the critical projectile velocity of 70 m/s is needed for penetration of the human skin.⁷ However, the projectile velocity of modern air weapons is often greater than that and muzzle velocity of many modern air rifles can be similar to that of a conventional hand gun.^{8,9} The air gun in our case report was 0.177 caliber with 4.5 mm pellet with muzzle velocity of 180 m/s. The projectile entered the thorax through the intercostal space to the left of sternal angle with subsequent investigations demonstrating the pawn shaped bullet near right 4th rib and the pellet was retrieved after thoracoscopic assistance from right upper lobe.

Thus, we conclude that air gun shot injuries are uncommon in pediatrics. Further such injuries on chest in pediatrics are rarely reported. However major concern is fatal injury if shot on chest due to

the complexity of underlying structures with risk of hematoma, pneumothorax, hemothorax and vessel puncture. Air gun shot injuries should not be considered non-fatal and such air gun should be kept away from reach of children, never to be placed loaded when not in use. The fatality of metallic bullet injury used for air gun depends on angulations at which it is fired & wound path structures. Further we believe that air guns should be regulated by the same laws that apply to firearms.

Compliance with Ethical Standards

Funding: None

Conflict of Interest: None

References:

1. Aslan S, Uzkeser M, Katirci Y, Cakir Z, Bilir O, Bilge F et al. Air guns: toys or weapons? *Am J Forensic Med Pathol.*

- 2006;27:260-262.
2. Ceylan H, Mc Gowan A, Stringer MD. Air weapon injuries: a serious and persistent problem. *Arch Dis Child.* 2002;86:234-235.
 3. Centers for Disease Control and Prevention. BB and pellet gun-related injuries-United States. June 1992-May 1994. *MMWR Morb Mortal Wkly Rep.* 1995;44:909-913
 4. Harris W, Luterman A, Curreri PW. BB and pellet guns-toys or deadly weapons? *J Trauma.* 1983;23:566-569
 5. Christoffel KK, Tanz R, Sagerman S, Hahn Y. Childhood injuries caused by nonpowder firearms. *Am J Dis Child.* 1984;138:557-561
 6. McNeill AM, Annest JL. The ongoing hazard of BB and pellet gun-related injuries in the United States. *Ann Emerg Med.* 1995;26:187-194
 7. Di Maio VJM, Copeland AR, Besant-Matthews PE, Fletcher LA, Jones A. Minimal velocities necessary for perforation of skin by air gun pellets and bullets. *J Forensic Sci.* 1982;27:894-898
 8. Naude GP, Bongard FS. From deadly weapon to toy and back again: the danger of air rifles. *J Trauma.* 1996;41:1039-1043
 9. Robson WJ, Kumar K. Air weapon injuries in children: a case for education. *Arch Emerg Med.* 1985;2:17-24