

TEACHING FILES (GRAND ROUNDS)

STARRY SKY INTRACRANIAL GRANULOMAS WITH SPINAL GRANULOMAS

Tsering Yangchen¹, Ira Shah².

¹Seth G S Medical College, Mumbai, India

²Pediatric Infectious Diseases, Levioza Health Care, Levioza Health Care, Mumbai, India

Clinical Problem

An 8 years old female, presented in Feb 2015 with fever and headache for 15 days. She was admitted in a hospital a week ago after she developed right lateral rectus palsy. There was no contact with a patient having TB. CT brain showed nodular area with surrounding hypodensity in left anterior gangliocapsular region. MRI brain showed granulomas in cerebral, cerebellar hemispheres and brain stem along with moderate obstructive hydrocephalus with meningeal enhancement like a starry sky appearance (Figure 1). The lesions were hyperintense on T1 and hypointense on T2 and Flair. There were also spinal granulomas. (Figure 2) X-Ray chest was normal, Mantoux test was negative and Dengue IgM positive. Cerebrospinal fluid (CSF) was cloudy with 800 cells (95% polymorphs and 5% lymphocytes), proteins 42 mg/dl glucose 27 mg/dl with corresponding blood sugar of 135 mg/dl. CSF geneXpert was negative for Mycobacterium tuberculosis (MTB). HIV Elisa was negative. On examination, weight was 16.5 kg, she had meningeal signs and right lateral rectus palsy.

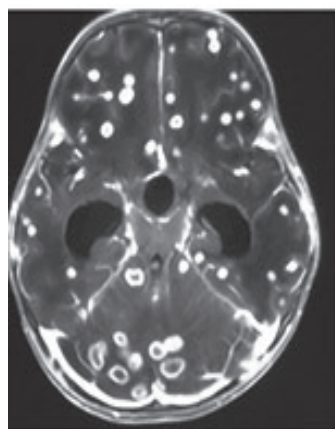


Figure 1. MRI brain showed granulomas in cerebral, cerebellar hemispheres and brain stem along with moderate obstructive hydrocephalus with meningeal enhancement.

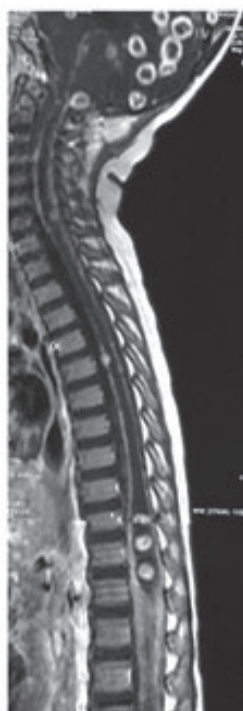

Figure 2. MRI spine showing spinal granulomas

ARTICLE HISTORY

Received 01 Nov 2018

Accepted 23 Jan 2019

KEYWORDS

Intestinal granuloma, TB, IBD

What is the likely diagnosis?

Expert Opinion

The patient was started on anti-tuberculosis treatment (ATT) along with prednisolone. After one week, her fever subsided and lateral rectus palsy also improved. She was advised to continue her ATT. Her CSF TB culture at the end of 6 weeks grew MTB that was sensitive to the first line ATT. There are multiple infectious, neoplastic, inflammatory, demyelinating and vascular causes of multiple ring-enhancing lesions.¹ In tropical India, the most common causes of multiple ring-enhancing lesions are neurocysticercosis and tuberculosis (TB), both of which often present with similar biochemical and radiological findings, thus causing a diagnostic dilemma.² Starry-sky in the brain has been observed in neurocysticercosis in children^{3,4}, however, its atypical presentation in CNS TB in children is rare, with only a few cases reported.^{5,6,7} TB, caused by Mycobacterium tuberculosis (MTB) is acquired by inhalation of droplet nuclei containing the bacilli that lodge in the alveoli.⁸ In a healthy immunocompetent host, the TH1 immune response tries to contain the bacilli by forming a tuberculoma. Before this happens, the bacilli drain into the lymph node and cause low-level bacteremia and get disseminated in the body, mainly to the organs receiving rich blood supply such as the brain (cerebral and cerebellar hemispheres and the basal ganglia that are highly oxygenated). A further event in the disseminated organ depends upon the balance between the host immune response and the virulence of the organism.⁹ For central nervous system (CNS) TB, the bacilli seeds to the brain, spinal cord or the meninges forming small subependymal or subpial focus known as the Rich focus.⁹ Location and control of these lesions ultimately determine the form of CNS TB that results. Rupture of these lesions most commonly presents as tuberculous meningitis (TBM). Tuberculous encephalitis, intracranial tuberculoma, and brain abscess are the less likely consequences.¹⁰ Intracranial tuberculomas are very rare and account for 10-30% of all intracranial masses in the developing world.¹¹ Its incidence is highest in the pediatric population. TB lesions are commonly located at corticomedullary junction and periventricular region (rich blood supplies) and are mainly supratentorial in

CONTACT Tsering Yangchen

Email: mbbs160172@kem.edu

Address for Correspondence: Tsering Yangchen, Seth G S Medical College, Mumbai, India.

©2020 Pediatric Oncall

adults. In children, the cerebellum is more commonly involved than the cerebrum.⁹ Multiple lesions are less common than single lesions and when present, give the characteristic 'starry sky appearance' which, in a country like India, raises diagnostic dilemma with neurocysticercosis. Differentiation can be established by growing bacteriological isolation of MTB as was seen in our patient. The reason for the development of multiple tuberculomas is still not clear. Treatment consists of antituberculous therapy and steroids.

Compliance with Ethical Standards

Funding: None

Conflict of Interest: None

References :

1. Garg RK, Sinha MK. Multiple ring-enhancing lesions of the brain. *J Postgrad Med* 2010;56:307-16.
2. Verma R, Gupta R. Multiple ring-enhancing lesions: diagnostic dilemma between neurocysticercosis and tuberculoma. *BMJ Case Rep*. 2014.
3. Sodhi KS, Khandelwal N, Suri S. Starry sky appearance. *Postgrad Med J*. 2005;81:332.
4. Singhi P, Singhi S. Neurocysticercosis in children. *Indian J Pediatr*. 2009;76(5):537-45.
5. Satyarthee GD, Chandra PS, Mahapatra AK. Brain Studded with Innumerable Larger Stones: Starry Sky at Night Appearance; Multiple Calcified Giant Tuberculoma with 15 Years of Follow-up. *Indian J Neurosurg* 2017;6:155-158.
6. Kaur S, Kulkarni K, Gupta V. The "Starry-Sky" Appearance of Tuberculous Meningitis. *Pediatr Infect Dis J*. 2010;29:384-385.
7. Garg M, Kulkarni S, Sayed R. Starry-Sky Appearance in neurotuberculosis. *Pediatr Neurol*. 2016;64: 101.
8. Thwaites G, Chau TT, Mai NT, Drobniowski F, McAdam K, Farrar J. Tuberculous Meningitis. *J Neurol Neurosurg Psy*. 2000; 68:289-99.
9. Chowdhury FH, Haque MR, Sarker MH. Cerebrum, Cerebellum, and Deep Structures of the Brain. In: Turgut M (ed). *Tuberculosis of the Central Nervous System*. Switzerland. Springer. 2017: 80-96.
10. Rock RB, Olin M, Baker CA, Molitor TW, Peterson PK. Central Nervous System Tuberculosis: Pathogenesis and Clinical Aspects. *Clin Microbiol Rev*. 2008;21:243-261.
11. Nabi J. Multiple Isolated Intracranial Tuberculomas Masquerading as Brain Metastases on Radiological Imaging: Success of a Therapeutic Trial. *Arch Surg Oncol*. 2015;1:1