

## LETTER TO EDITOR (VIEWERS CHOICE)

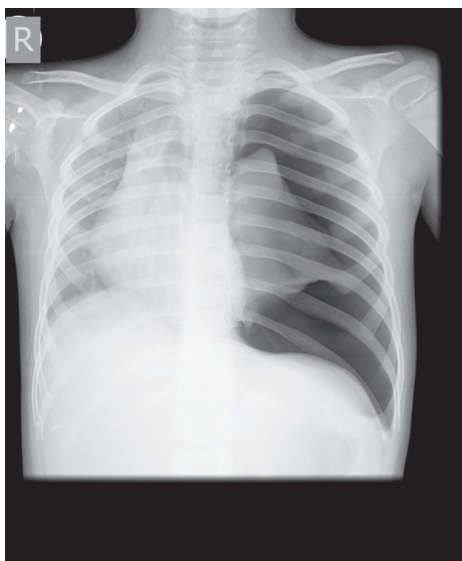
### SPONTANEOUS PNEUMOTHORAX: A RARE COMPLICATION OF CIPROFLOXACIN IN A CHILD

Ashwin Borade\*, Muznah Kapdi\*, Swapneel Kulkarni\*\*

Although ciprofloxacin is a generally well-tolerated fluoroquinolone antibiotic, serious and life-threatening adverse events such as anaphylaxis and pulmonary edema have been described with its use in literature. (1) However spontaneous pneumothorax following hypersensitivity to ciprofloxacin has not been reported especially in children. The case emphasizes promoting the rational use of antibiotics.

A 6-year-old boy presented with on and off fever for a week. He was admitted at a local hospital and given intravenous (IV) ceftriaxone and amikacin. Hemogram was normal, C - reactive protein (CRP) and Widal test were negative. He continued to have persistent high grade fever without focus, so IV ciprofloxacin was started. Injection ceftriaxone and amikacin were continued. As soon as IV ciprofloxacin was started, he developed generalized erythema, urticaria, dyspnea, swollen tongue, and a sense of fullness in the chest. He was immediately transferred to our hospital where dyspnea increased and he also developed ipsilateral chest pain. Physical examination at admission revealed a left sided pneumothorax. Chest X-ray confirmed the same (Fig.1). Tube thoracotomy with underwater seal was done. Injection pheniramine maleate and hydrocortisone were given for anaphylactoid reactions. Blood count, glucose, urea, creatinine, liver function tests, IgE levels were normal. HIV Elisa and tuberculosis Elisa were negative. Subsequent radiographs of the chest showed a gradual reduction of the pneumothorax. The chest tube was removed on the 3rd day of hospitalization and he was discharged on day 5. Injection ceftriaxone and amikacin were given till discharge. Child is on regular follow up without any residual effects.

**Fig.1: A radiograph of the chest showing a left sided pneumothorax**



The fluoroquinolones are an important group of antibiotics widely used in the treatment of various infectious diseases, as a result of an excellent spectrum

of activity, good tissue penetration and convenient ways of administration. (2) Fluoroquinolones cause arthrototoxicity, photosensitivity, disorders of glucose homeostasis, dysrhythmias, hepatic dysfunction, and life-threatening hypersensitivity reactions characterized by diffuse, erythematous, non-pruritic, blanching rash, with fever and hypotension rashes. (1,2) Although anaphylactoid/anaphylactic reactions are rare adverse effects of ciprofloxacin and other fluoroquinolones, this potentially can cause fatal episode of pneumothorax as in our case. Anaphylactoid reactions produce the same clinical picture with anaphylaxis but are not IgE mediated, occur through a direct non-immune mediated release of mediators from mast cells and/or basophils or result from direct complement activation. (1) This may induce upper airway obstruction, due to laryngeal edema, as well as lower airway obstruction, due to bronchospasm, intraluminal secretions, submucosal edema, vascular congestion, and influx of inflammatory cells, especially eosinophils. Airway obstruction, pulmonary hyperinflation, and an increased effort of breathing all increase alveolar pressure, which may have ruptured pre-existing subpleural blebs or bullae, causing pneumothorax. (3,4)

#### Acknowledgement

Authors would also like to thank Dr. Parvez Inamdar, Medical director, Inamdar Multispecialty Hospital, Pune and Dr. Rohit Kumbhar for allowing us to publish this case.

**Funding:** None

**Conflict of Interest:** None

#### References :

1. Ho DY, Song JC, Wang CC. Anaphylactoid reaction to ciprofloxacin. *Ann Pharmacother.* 2003 ;37:1018-1023
2. Leibovitz E. The use of fluoroquinolones in children. *Curr Opin Pediatr.* 2006; 18: 64-70
3. Sahn SA, Heffner JE. Spontaneous pneumothorax. *N Engl J Med* 2000; 342: 868-874
4. Giltay EJ, Berendsen HH. Pneumothorax following insect sting anaphylaxis. *Allergy.* 2002; 57: 270-271 Thimerosal - Containing Vaccines and Neurodevelopmental Disorders. Washington, DC: The National Academies Press, 2001.

**From:** \*Department of Pediatrics and Neonatology Inamdar Multispecialty Hospital, Pune, Maharashtra, India.

**Address for Correspondence:** Dr. Ashwin Borade, Consultant paediatrician and neonatologist, Inamdar Multispecialty Hospital, Street no 15, Fatima Nagar, Pune, Maharashtra, India 411040.

**Email:** ashwinborade@yahoo.com



**DOI:** 10.7199/ped.oncall.2015.26