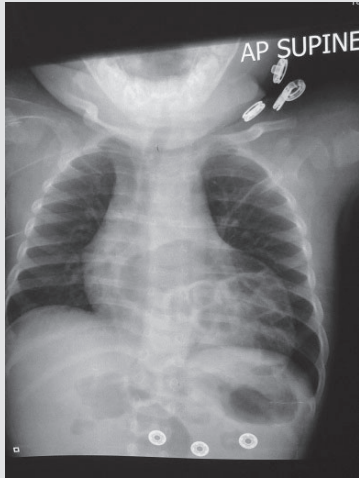


## SPOT DIAGNOSIS (IMAGE GALLERY)



### NEWLY DIAGNOSED DIAPHRAGMATIC HERNIA IN A 13 MONTHS OLD

**Adam Powell**

*Shaw Air Force Base Pediatric Medical Director, USA.*

**Address for Correspondence:** Dr. Adam Powell, 431 Meadowlark st. Shaw AFB , SC 29152, USA. Email : [adampowellmd@gmail.com](mailto:adampowellmd@gmail.com)

A 13 months previously healthy male child was transferred from a community emergency room for newly diagnosed congenital diaphragmatic hernia and possible emergency surgery. He had presented with two days of cough, congestion and fever. On examination, he was calm, comfortable and happy on mother's lap without any obvious respiratory distress. Respiratory auscultation had only conducted breath sounds. He had bilateral otitis media. Other systems were normal. A chest x-ray at the outside emergency room showed loops of large bowel in the left chest cavity with some mediastinal shift. No additional studies were ordered on arrival and surgery was consulted. Patient was admitted for observation and placed on antibiotics

for his otitis media. Patient was stable overnight and discharged on amoxicillin. Patient had outpatient surgery a week after hospitalization to repair his diaphragmatic hernia without any immediate complications or issues on 6 month follow-up.

#### Which type of diaphragmatic hernia does this patient have?

Morgagni hernia. Subcostosternal diaphragmatic hernias are a rare form of diaphragmatic hernia accounting for 3-5 percent of all cases. (1) Anterior defect occurs when gastrointestinal (GI) contents extend through the foramen of Morgagni, a triangular space formed when the muscle fibers of the xiphoid process and costal margin insert on the central tendon of the diaphragm. (2) This is in contrast to the more common posterolateral defects through the foramen of Bochdalek, which account for 80-90 percent of congenital diaphragmatic hernia cases. (3) The presentation differs greatly with these two hernia types. The Bochdalek hernia usually presents in the classic, acutely ill neonate requiring significant respiratory support and surgical interventions. These patients tend to have some degree of lung hypoplasia and pulmonary hypertension leading to significant morbidity and mortality, among other complications. (4) The Morgagni hernia tends to be diagnosed incidentally however presentation varies from recurrent chest infections to gastrointestinal symptoms. (5) Surgical repair is still indicated for patients with Morgagni hernias due to risk of strangulation and colonic perforation, however the timing of repair depends on the individual surgeon. (2) .

**Funding:** None

**Conflict of interest:** None

**Disclosure:** The opinions expressed herein are those of the author and are not necessarily representative of those of Shaw Air Force Base, the Department of Defense (DOD) or the United States Army, Navy, or Air Force

#### References:

1. Al-Salem, AH. Congenital hernia of Morgagni in infants and children. *J Pediatric Surg.* 2007; 42: 1539-1543
2. Minneci PC, Deans KJ, Kim P, Mathisen, DJ. Foramen of Morgani hernia: changes in diagnosis and treatment. *Ann Thor Surg.* 2004;77: 1956-1959
3. Kim JM, Couluris M, Schnapf BM. Late-presenting Left-Sided Morgagni Congenital Diaphragmatic Hernia in a 9 Year Old Male. *ISRN Pulmonology.* 2011; article ID 409252.
4. Peetsold MG, Heij HA, Kneepkens CM, Huisman J, Gemke RJ. The Long-Term Follow-Up of Patients with a Congenital Diaphragmatic Hernia: a Broad Spectrum of Morbidity. *Pediatr Surg Int.* 2009;25: 1-17
5. Mei-Zahav M, Solomon M, Trachsel D, Langer JC. Bochdalek diaphragmatic hernia: not only a neonatal disease. *Arch Dis Child.* 2003; 88:532-535

**DOI No. :** 10.7199/ped.oncall.2014.45

Quick Response Code

